

CASE REPORT

Idiopathic Laryngeo-Tracheal Stenosis: An Illustrative Case Report**Zeead M. Al Ghamdi, Shadi A Alshammary, Ayman El-Baz, Mohamed Regal**

Cardiothoracic Surgery Division, Surgery Department, King Fahad University Hospital, Al Dammam University, Al Dammam, Saudi Arabia.

Corresponding author: Dr. Mohamed Regal Email: mohamedregal@yahoo.com

Published: 23 June 2014

Ibnosina J Med BS 2014;6(3):155-158

Received: 10 November 2013

Accepted: 19 December 2013

This article is available from: <http://www.ijmbs.org>

This is an Open Access article distributed under the terms of the Creative Commons Attribution 3.0 License, which permits unrestricted use, distribution, and reproduction in any medium, provided the original work is properly cited.

Abstract

Idiopathic laryngeo-tracheal stenosis (ILTS) is characterized by the formation of a scar-like circumferential stenosis affecting the subglottic area and extending to a variable length in the upper trachea. We report an illustrative case of ILTS in a 33 years old lady who presented with progressive dyspnea and stridor and was managed as bronchial asthma for the prior 2 years. Her bronchoscopic and radiologic imaging revealed extensively narrowed subglottic segment 5 mm below the vocal cords that extended into the upper trachea. Definitive laryngeo-tracheal resection and reconstruction (Pearson's repair) was performed with a satisfactory result. She remained free of symptomatic and radiologic recurrence over 4 years of follow up.

Key Words: Idiopathic laryngeo-tracheal stenosis, Bronchial asthma, Stridor, Pearson's repair.

Introduction

Tracheal stenosis is not uncommon. It may be caused by a variety of benign and malignant conditions. Most commonly, it is caused by post-intubation injury, and represents the main indication for surgical treatment of the upper airway (1,2). Idiopathic laryngeo-tracheal stenosis (ILTS) is a rare disease of unknown origin. It is characterized by the formation of a scar-like circumferential stenosis, caused by non-specific inflammation, affecting the subglottic area and extending to a variable length in the upper trachea (3,4).

Case Report**Presentation**

A thirty-three year old nurse presented with a history of progressive dyspnea for two year duration. She has been treated as bronchial asthma with bronchodilators and corticosteroids with partial improvement. Her condition worsened in the previous six months with marked stridor and hoarseness of voice and she was referred to our hospital

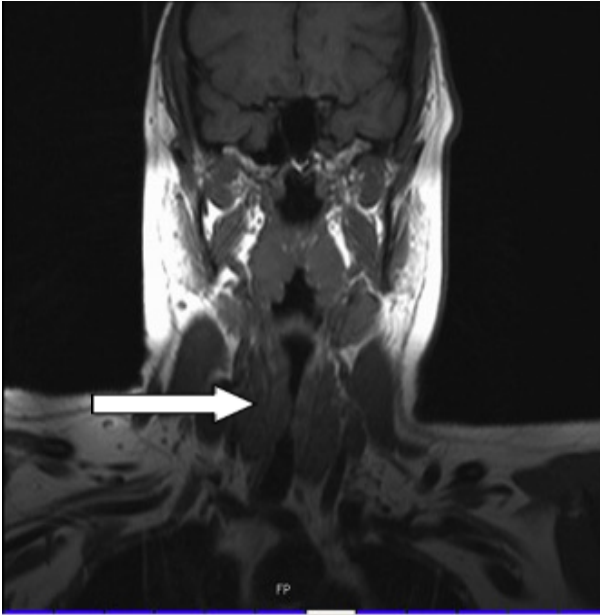


Figure 1. Preoperative MRI scan showed a long segment of extensive subglottic stenosis extending into upper trachea (arrow).

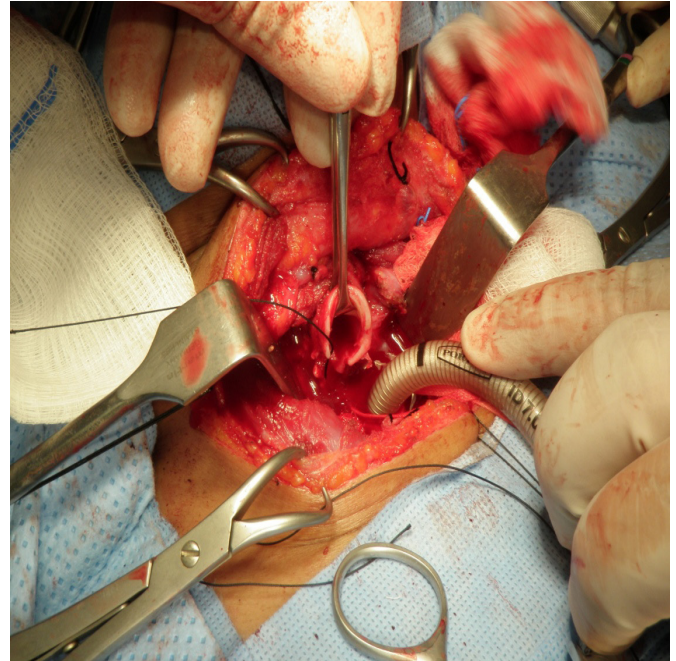


Figure 2. Conduction of anesthesia through a distal endotracheal tube (ETT) after division of the upper trachea below the stenotic area.

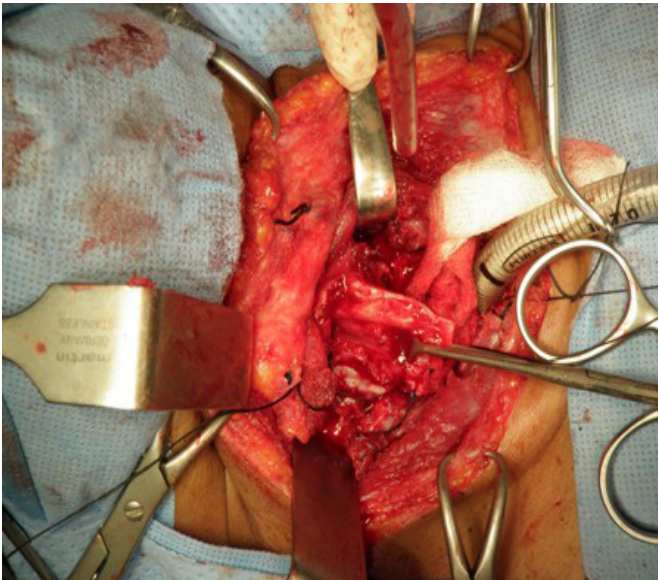


Figure 3. Extensive narrowing of the cricoid lumen after partial cricoidectomy

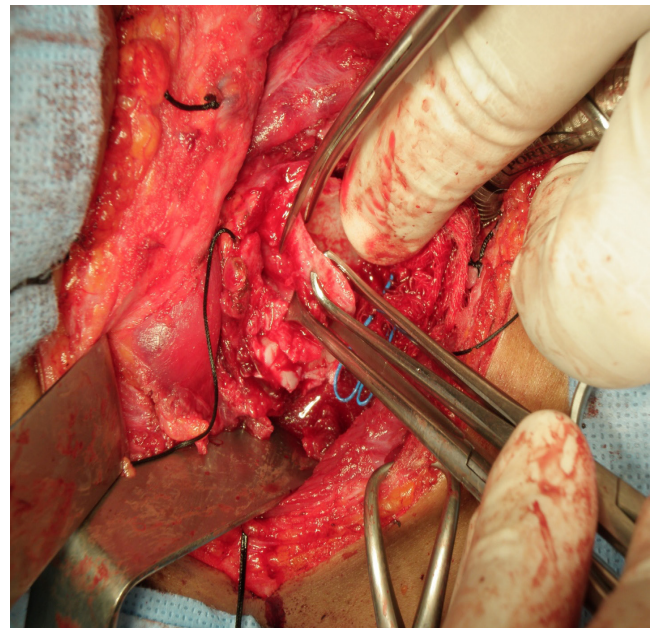


Figure 4. Subperichondrial excision of the cricoid cartilage to augment the narrowed lumen.

for further management. The patient had no past history of previous surgery or airway intubation for any reason. There was no history of tracheal trauma, previous ICU admissions, previous TB or any other connective tissue disease or recurrent aspirations or pneumonia. She has never smoked. Her initial MRI showed a long segment of stenotic subglottic area extending into the upper trachea (Figure 1).

The patient could not tolerate fiberoptic bronchoscopy and became hypoxic. Therefore, she was admitted and rigid bronchoscopy was done under general anesthesia. Scope size 3.5 Fr was passed with extreme difficulty. It confirmed the presence of an area of extensive subglottic stenosis,

starting around 5 mm below the vocal cords and extending for 1-1.5 cm into the upper trachea. The stenotic area was very tough and could neither be dilated by balloons nor by the use of progressive sizes of the bronchoscope. Urgent laryngotracheal resection and reconstruction was planned.

Surgical management

Induction of anesthesia was with continuous infusion of short-acting muscle relaxants and intravenous anesthetic agents and short acting opioids. A small endotracheal tube (ETT) was used for proximal intubation until tracheal resection was done, and after the distal airway was divided, ventilation was maintained through a distal ETT connected across the operative field (Figure 2).

Operative procedure (Pearson's technique)

The patient was placed in a supine position with a sand bag beneath her shoulders and the head was hyperextended. An anterior cervical low collar incision was done. Routine dissection, division of the sternohyoid muscles in the midline, and division of the thyroid isthmus to expose the cervical trachea. Circumferential dissection of the trachea up to the level of the thyroid cartilage above and inferiorly below the stenosis. Dissection was maintained as close as possible to the tracheal wall to avoid injury to recurrent laryngeal nerves. Resection of the upper two tracheal rings was done. Excision of the anterior and lateral walls of the cricoid cartilage was done with preservation of the posterior plate. After partial cricoidectomy done, it was found insufficient with extensive narrowing of the lumen, so we performed subperichondrial excision of the cricoid to augment the lumen (Figures 3 & 4). At the end direct thyrotracheal anastomosis was done with covering the bared cricoid cartilage by a posterior membranous tracheal flap. Protective tracheostomy was done to maintain the airway patency until the edema subsides.

Postoperative care

Laryngeal edema subsided gradually and the patient was extubated within the first 24 hours. Tracheostomy tube was removed after 1 week and the patient had normal mobile vocal cords. Pathology examination did not show any disease or abnormality, only excessive circumferential fibrous tissue formation with non-specific inflammation. TB was excluded.

Follow up

The patient was re-admitted twice with mild stridor in the early post operative period. Bronchoscopy was performed,

using size 6.5, showed formation of granulation tissue over the suture line. Curettage was done in addition to removal of the remnant sutures (6 weeks after discharge). Pneumatic dilatation was used once at 12 weeks after discharge. Patient's condition improved apart from mild hoarseness of the voice. Over four years of follow up, the patient has been well and did not require any further admissions or interventions. After stabilization of the patient and improvement of her breathing she was referred for elective upper gastrointestinal tract endoscopy which revealed gastroesophageal reflux disease and mild sliding hiatus hernia. She was treated with proton pump inhibitor and anti-reflux therapy.

Discussion

ILTS is a rare disease of unknown origin. It is caused by non-specific inflammation that produces ring-like scar tissue. This scar tissue affects the subglottic area circumferentially and extends into the upper trachea. ILTS has a characteristic features that are different from other stenosis where there is a lack of predisposing factors and the almost exclusive affect female patients with ages between the 20 to 60 (3,4). To diagnose ILTS, it is important to rule out the predisposing factors most often claimed to lead to stenosis, such as prolonged tracheal intubation, external laryngotracheal trauma, upper airway infections, Wegner's granulomatosis, amyloidosis, histoplasmosis, collagen vascular disease, chemical or inhalational burns, tuberculosis, radiation, benign or malignant neoplasms and congenital causes. It has been suggested that ILTS could be related to gastroesophageal reflux disease (3-5). The cardinal symptom is inspiratory dyspnea (98%), occasionally stridor, it is rarely accompanied by dysphonia or cough. Bronchoscopic evaluation of the upper airways is the key stone of preoperative diagnosis and evaluation of the airways and to exclude other causes of tracheal stenosis. Temporary balloon or pneumatic dilatation is very important to stabilize these patients and properly prepare them for surgical intervention, without the need to perform unnecessary tracheostomy. Dilatation failed in our patient due to the extensive fibrosis of keloid-type narrowing the larynx and trachea. Tracheal reconstructive surgery is the best option for the cases of ILTS. Most series have recommended surgical intervention as the primary management of upper airways stenosis (3,4,6,-8). In cases of subglottic involvement, there is increased technical difficulty to perform partial cricoidectomy that is removal of the anterior and lateral plates of the cricoid, as described by Pearson with preservation of the posterior plate to preserve the re-

current laryngeal nerves. In this case the partial cricoidec-tomy was not sufficient and we performed subperichondrial excision of the posterior cricoid plate. Finally the upper tracheal is fashioned obliquely and anastomosed to the thyroid cartilage, after using its posterior membranous wall to cover the posterior cricoid plate. In the follow up period further evaluation of the patient revealed gastroesophageal reflux disease, although asymptomatic it could explain the progressive narrowing of the upper airways. In the early post operative period all factors causing recurrent stenosis should be avoided. Early removal of intraluminal sutures and granulation tissue may cause stridor and initiate re-stenosis. In our patient, bronchoscopy with curettage of the granulation tissue and removal of all sutures protruding in the lumen was done. A pneumatic dilatation was done at 12 weeks after discharge and since then the patient did not have any stridor or symptoms for the last 4 years.

In conclusion, ILTS is uncommon and usually presents with inspiratory dyspnea and stridor. To establish the correct diagnosis, the following steps should be taken in consideration; a detailed history (prolonged tracheal intubation or external laryngo-tracheal trauma), meticulous external and endoscopic examination, the proper radiological studies to rule out the possible causes. Tracheal surgery for ILTS with or without Pearson's repair is a safe procedure, with no major complications. Early formation of granulation tissue and stenosis could be successfully managed by bronchoscopy and balloon dilatation. Long term follow up have reportedly shown an excellent outcome with no late complications.

References

1. D'Andrilli A, Ciccone AM, Venuta F, Ibrahim M, Andreotti C, Massullo D, et al. Long-term results of laryngotracheal resection for benign stenosis. *Eur J Cardiothorac Surg* 2008;33(3):440-3.
2. Grillo HC, Donahue DM. Post intubation tracheal stenosis. *Semin Thorac Cardiovasc Surg* 1996;8(4):370-80.
3. Grillo HC. Idiopathic Stenosis. In: Pearson FG, Cooper JD, Deslauries J, Ginsberg RJ, Hiebert CA, Patterson GA, et al. (Eds). *Thoracic surgery*. 2nd Ed. Churchill Livingstone; (2002): pp 314-20.
4. Grillo HC, Mark EJ, Mathisen DJ, Wain JC. Idiopathic laryngotracheal stenosis and its management. *Ann Thorac Surg* 1993;56:80-7.
5. Terra RM, de Medeiros IL, Minamoto H, Nasi A, Pego-Fernandes PM, Jatene FB. Idiopathic tracheal stenosis: Successful outcome with antigastroesophageal reflux disease therapy. *Ann Thorac Surg* 2008; 85(4):1438-9.
6. Sajal De, Sarmishtha De. Post intubation tracheal stenosis. *Indian J Crit Care Med*. 2008;12(4):194-7.
7. Nielsen VE, Pedersen U, Pilegaard H. [Surgical treatment of tracheal stenosis]. *Ugeskr Laeger* 2010;172(17):1289-93.
8. Marques P, Leal L, Spratley J, Cardoso E, Santos M. Tracheal resection with primary anastomosis: 10 years experience. *Am J Otolaryngol* 2009;30(6):415-8.