

CASE REPORT

Intraoperative Ventricular Fibrillation Arrest Caused by Accidental Intravenous Injection of Epinephrine

Deyaa Baghdady Ahmed, Juniad Alam, Mahmood Talaat, Ahmed Al-Ahmary

Department of Critical Care, Imam Abdel Rahman Bin Faisal Hospital, National Guard Health Affairs, P.O. Box 4616, Dammam 31412, Saudi Arabia.

Corresponding author: Dr. Deyaa B. Ahmed Email: deyaa.baghdady@gmail.com

Published: 13 October 2014

Ibnosina J Med BS 2014;6(5):223-226

Received: 01 February 2014

Accepted: 05 July 2014

This article is available from: <http://www.ijmbs.org>

This is an Open Access article distributed under the terms of the Creative Commons Attribution 3.0 License, which permits unrestricted use, distribution, and reproduction in any medium, provided the original work is properly cited.

Abstract

We describe a 25-year old male who experienced ventricular fibrillation (V-Fib) arrest induced by inadvertent intravenous injection of epinephrine instead of the routine reversal medication. Under general anesthesia with Desflurane inhalation, 1.5% Lidocaine containing 1:100,000 Epinephrine was injected into the nasal mucosa for septoplasty and the procedure went smoothly. Near the end of the surgery, the patient suddenly developed sinus tachycardia followed by V-Fib arrest which responded to a single shock of 300J. Sinus rhythm was restored immediately. The patient developed severe lactic acidosis and a bedside echocardiography showed global hypokinesia and normal right sided pressures. The patient was intubated and admitted to the ICU on mechanical ventilation before being weaned and extubated. Retrospectively while investigating the cause after it was discovered that epinephrine had been given as opposed to the anesthesia reversal medication. This case illustrates an unusual response to epinephrine

with cardiac arrest in a healthy young male.

Key words: Cardiac Arrest, Epinephrine, General anesthesia,

Introduction

Rapid I.V. administration of epinephrine during pulseless cardiac arrest is an established standard of care (1). However, accidental rapid IV epinephrine is known to result in very serious side effects which may include cerebrovascular hemorrhage or cardiac arrhythmias leading to death. We report a case of an unusual response to epinephrine with cardiac arrest in a healthy young male.

Case Report

25 years old Saudi male was admitted for routine rhinoplasty in March 2013. He has no past medical history. He was not obese (weight: 55kg; height: 166 cm) His preoperative vital signs were all normal (Heart rate: 72 bpm regular, blood

pressure 126/70 mmHg, respiratory rate: 20, and SpO₂ was 100%). On the following morning, he went to operating room for the planned procedure. Patient was classed as ASA1; anesthesia started 08:50 and ended 10:35, and surgery started 09:10 and ended at 09:35. Patient was very stable during his operating room stay as evidenced by his documented vitals. His heart rate ranged between 70 and 80 bpm; and blood pressure, respiratory rate and oxygen saturation were all within normal ranges. Almost near the end of the anesthesia at 09:35, inadvertently instead of the

usual anesthesia reversal medication (Proistgmine plus Glycopyrolate), he received 1mg given IV push from one ampoule of Epinephrine (1:1000 concentration 1mg/1ml). Prior to the injection, the patient was in sinus rhythm but the HR jumped instantaneously from 120 to 180 and then changed to ventricular fibrillation. Only one DC shock of 300 J was given followed by one cycle of CPR after which he was noted to be back to sinus tachycardia followed by sinus bradycardia. A single dose of 0.6 mg atropine was given IV after which HR returned to sinus rhythm with

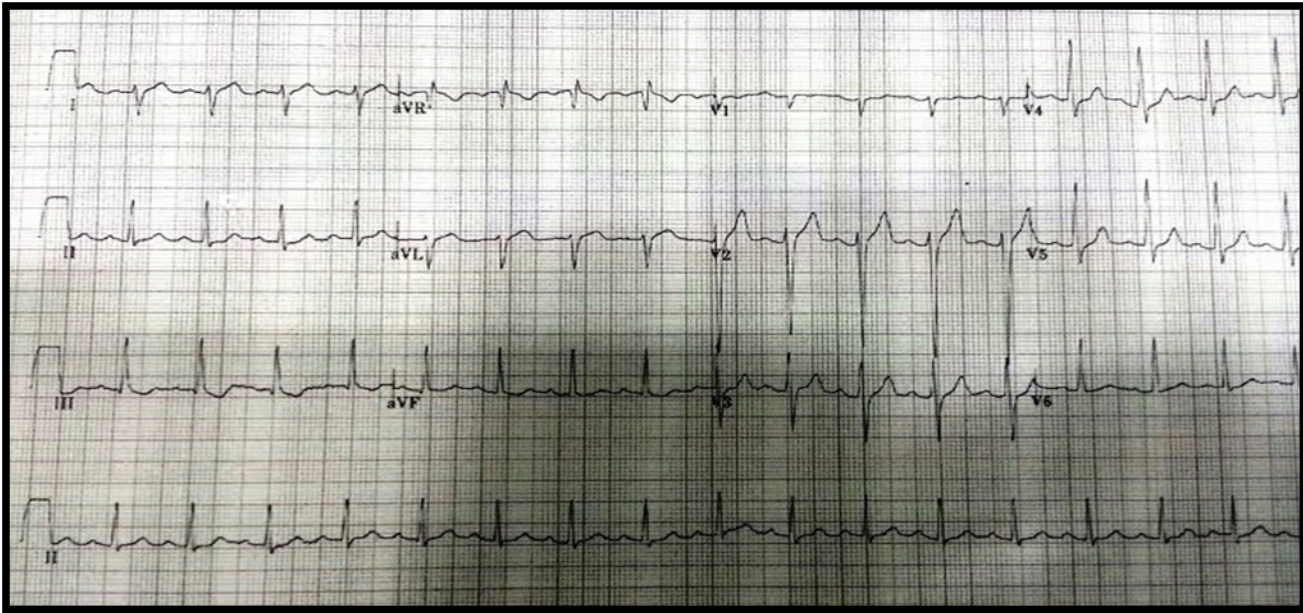


Figure 1. Post cardiac 12 lead ECG showing sinus tachycardia and right axis deviation.

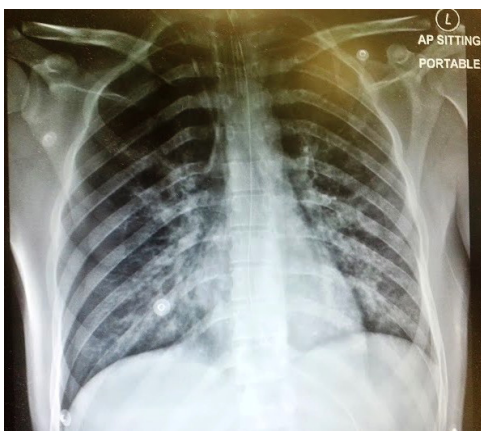


Figure 2. Plain chest X-ray which showed 2 cm right side pneumothorax.

stable BP. Post cardiac arrest, the patient was kept intubated and shifted to the ICU for monitoring recovery. After 10-15 minutes of arriving to the ICU, the patient started to wake up but was very agitated. An attempt at extubation was done at 11:10 am but he remained severely restless and agitated. He therefore received IV boluses of haloperidol, fentanyl and finally midazolam. Within the following hour, BP dropped, IV Fluid bolus was given but stayed hypotensive so norepinephrine infusion was started. He was found to be severely hypoxemic and pulse oximetry was 76% on a non-re-breather face mask, ABG analysis at this point was PO₂ 44%, SpO₂ 76%. With no improvement in oxygenation, ICU team decided to reintubate him electively. At 13:02, patient was intubated again and ventilated. With the sudden unexplained high hypoxic index, an emergent bedside echocardiography was ordered done. With new bilateral lung infiltrates in the chest X-ray plus severe hypoxemia,

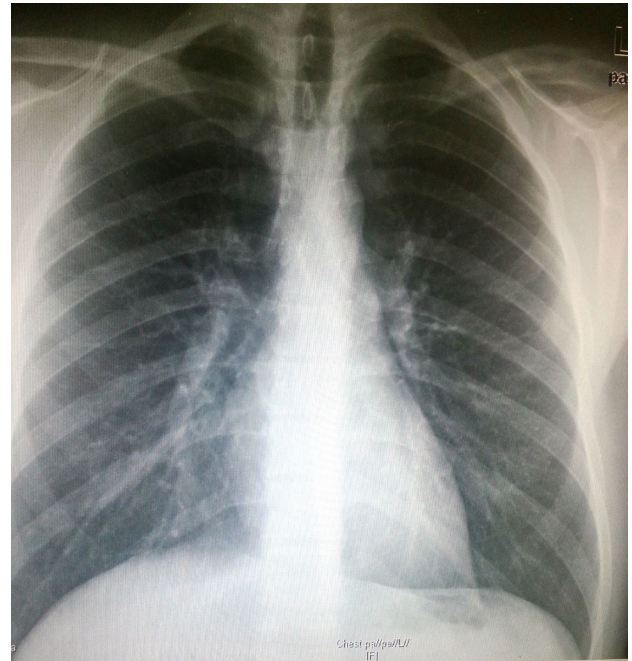
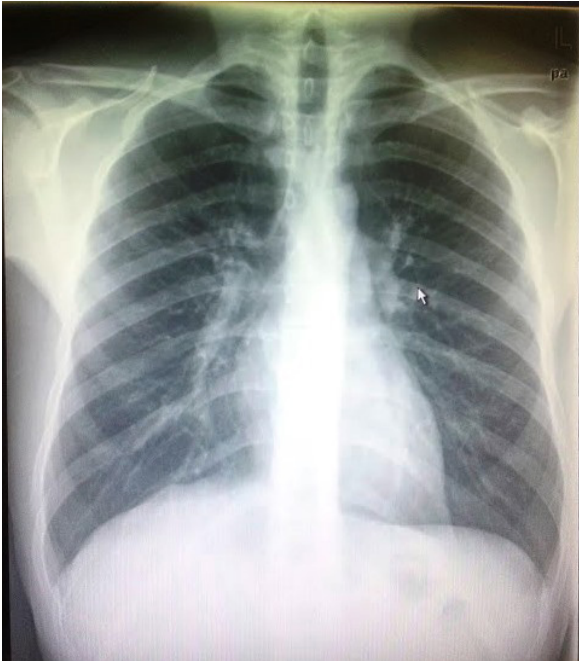

Figure 3. Follow up plain chest X-ray done in the ENT clinic days later showed no pneumothorax on the right side. On the left side the follow up X-ray after 1 year.

the patient was kept on mechanical ventilation on adult respiratory distress syndrome (ARDS) protocol (low volume & high positive end expiratory pressure). Right internal jugular line inserted with post procedure chest X-ray showing bilateral infiltrates but no pneumothorax. Central venous pressure was 12 mmH₂O. MV parameters were FIO₂ (100 then 80%), PEEP (10, 8 then 5), ACPC mode which generated Vt of 450 CC.

Post cardiac arrest blood lactic acid was 10.10mmol (0.5-2.2), which decreased to 1.40 mmol/L 3 hours later. Other pertinent labs were WBC 25.3, Hgb 140, Ca⁺⁺ 2.33 mOther pertinent laboratory results were WBC 25.3, hemoglobin 140 g/L, Ca⁺⁺ 2.33 mmol/L, Mg⁺⁺ 0.77 mmol/L, Na⁺ 135mmol/L, K⁺ 4.2mmol/L, CO₂- 16mmol, Creatinine 89umol/L, Anion Gap 19, INR 1.1, PTT 29.3 sec, CRP 0.3 mg/l and two blood cultures came negative after 5 days. Echocardiography showed an EF 50-55% with abnormal wall motion of the left ventricle likely explained by the cardiac arrest and DC shock. ECG post cardiac arrest showed sinus tachycardia, right axis deviation (Figure 1).

Patient was kept on MV on ARDS protocol which improved dramatically within the next few hours. On the second ICU day, his Glasgow coma score was 15/15; vitals stable, off pressors with no signs of ARDS with MV parameters

were weaned from MV and extubated smoothly (with the aid of Flumazenil as reversal for midazolam infusion). Incidentally, 2 cm right side pneumothorax was noted in the Chest X-ray (Figure 2). Patient remained tachypneic so; he was placed on high flow oxygen as initial management of his pneumothorax without insertion of intercostal tube. On the third day in ICU: repeated chest-X ray showed resolving pneumothorax. Patient was on 2 liters O₂ SpO₂ 100%, and was transferred to a general hospital ward. On the 5th postoperative day, patient was discharged home without any complaint. A follow up plain X-ray of the chest was done in clinic 9 days post event was normal with no more evidence of pneumothorax (Figure 3). He was referred for follow up for echocardiography 6 weeks but the patient didn't show up. The patient did follow up after one year of the incident. ECG came normal, same picture as post arrest. Echocardiogram was also done which revealed normal left ventricular function no wall motion abnormality, no valvulopathy and no pulmonary hypertension. Also, a follow up chest X-Ray showed the same picture as last one (Figure 3).

Discussion

Although rapid intravenous administration of epinephrine during pulseless cardiac arrest is recommended. However, accidental rapid IV epinephrine is known to result in very

serious side effects which may include cerebrovascular hemorrhage or cardiac arrhythmias leading to death. Significant cardiovascular adverse reactions also include: angina, cardiac arrhythmia, chest pain, flushing, hypertension, pallor, palpitation, sudden death, tachycardia (parenteral), vasoconstriction, and ventricular ectopic, ventricular fibrillation. Adrenaline 1:10,000 is used as an adjunct in the management of cardiac arrest. Adrenaline 1:1,000 is the drug of choice in the emergency treatment of acute severe anaphylactic reactions due to insect bites, drugs and other allergens. It may also be used for the symptomatic relief of respiratory distress due to bronchospasm. The 1:1,000 (1 mg/1 mL) injection is preferably administered subcutaneously. It may also be administered intramuscularly but not in the buttocks. In emergency situations, adrenaline may be injected very slowly intravenously but only as the dilute solution 1:10,000. Adrenaline injection contains no antimicrobial agent. It should be used only once and any residue discarded. In cardiac arrest adults, the recommended dose is 1 mg intravenously, using 10 mL of the 1:10,000 solutions. This may be repeated every 3-5 minutes. If given through a peripheral line, each dose should be followed by a flush of 20 mL of IV fluid to ensure delivery of the drug to the central compartment.

Our hospital is JCI-accredited and under its MMU (Medication Management and Utilization) Chapter, a committee looking into medication errors governs and guides for all such problems. This case was discussed in detail in our MUPES (Medication Utilization Process Error Subcommittee) and it recommended independent double checking for high alert medications, strict signing of all medications before giving medication and all personnel involved do their yearly competencies along with a medication safety course.

There have been a few reports in the literature describing accidental IV epinephrine that have caused coronary vasospasm (2), angina (3) or even acute MI (Ref). A case has even been reported with submucosal injection of very low concentrations of 1:100,000 in patients with variant angina (3). Inadvertent IV injection of adrenaline has been reported to have caused convulsions, metabolic acidosis, and renal failure with anuria. Adrenaline directly increases lactate release and lipolysis and inhibits insulin-stimulated glucose uptake (4-6). Our case was not known to have any medical problem include any coronary artery disease plus also post cardiac arrest ECG and echocardiography did not show any evidence to coronary vasospasm at any

moment. Cardiac enzymes including troponin I post cardiac arrest all came within normal variants. Despite thorough investigation for this patient we did not find any risk factors for Coronary heart disease including family history. There also was no evidence as well for coronary vasospasm or symptoms of angina before or after the attack. A follow up ECHO had been requested but the patient did not return in 6 weeks but recently after almost a year, follow up echocardiogram came normal.

Conflict of Interest:

The authors declared no conflict of interest.

References

1. American Heart Association. 2010 American Heart Association Guidelines for cardiopulmonary resuscitation and emergency cardiovascular care science. *Circulation* 2010;122:S640-S656.
2. O-uchi J, Komukai K, Tohyama J, Inada K, Iwano K, Yamane T, et al. Coronary artery spasm discovered in thorough examination of perioperative VT in a 26-year-old Japanese male. *Jpn Heart J* 2003;44(6):1021-6.
3. Lee JY, Hong SJ, Chon JY, Kwon SY. Cardiac arrest induced by submucosal injection of epinephrine in a patient with variant angina. *Rhinology* 2010;48(2):251-3.
4. Arfi AA, Kouatli A, Al-Ata J, Arif H, Syed S. Acute myocardial ischemia following accidental intravenous administration of epinephrine in high concentration. *Indian Heart J* 2005;57:261-4.
5. Totaro RJ, Raper RF. Epinephrine-induced lactic acidosis following cardiopulmonary bypass. *Crit Care Med.* 1997;25(10):1693-9.
6. Gjedsted J, Buhl M, Nielsen S, Schmitz O, Vestergaard ET, Tønnesen E, et al. Effects of adrenaline on lactate, glucose, lipid and protein metabolism in the placebo controlled bilaterally perfused human leg. *Acta Physiol (Oxf)*. 2011;202(4):641-8.