

## CASE REPORT

## Seckel's-Like Syndrome with Primordial Dwarfism, Marked Mental Retardation, and Severe Heart Malformation

Farida Chentli, Siham Belahcene, Said Azzoug

Department of Endocrinology and Metabolism, Bab El Oued Hospital, Algiers, Algeria

Corresponding author: Professor Farida Chentli Email: Chentli.f@gmail.com

Published: 30 November 2013

Ibnosina J Med BS 2013,5(6):339-344

Received: 26 February 2013

Accepted: 09 July 2013

This article is available from: <http://www.ijmbs.org>

This is an Open Access article distributed under the terms of the Creative Commons Attribution 3.0 License, which permits unrestricted use, distribution, and reproduction in any medium, provided the original work is properly cited.

### Abstract

**Introduction:** Seckel's Syndrome, also called "Bird headed" syndrome was first described by Seckel in 1960. The very rare genetic and heterogeneous disorder, inherited in an autosomal recessive manner, is characterized by severe proportionate dwarfism of prenatal onset with mental retardation, dysmorphic facial features like a bird's with microcephaly, large beaked nose, and micrognathia. Our aim was to describe a typical case and give a focused literature review. **Case report:** A boy aged 7, with a birth weight of 1.9kg, whose parents are first cousins, was referred to our department for severe dwarfism. His mother reported hyperactivity and mental retardation. He weighed 8kg, measured 81cm (-6SD) and his cranial perimeter was 31 cm. He had a bird-like face with receding chin and forehead, large eyes, and prominent nose. In addition to his dysmorphic face, clinical examination showed kyphoscoliosis, flat feet, hypospadias and a systolic heart murmur heard in the pulmonic area of

the chest, radiating into the back. There was no sign of right cardiac insufficiency. Echocardiography showed a large atrial-septal defect with enlarged right atrium and ventricle. Routine and haematological analyses were normal. Endocrine assessment was normal even for growth hormone and insulin growth factor (IGF-1). Psychological examination argued for severe mental retardation. Genetic screening was not available because of parents' low socioeconomic status. **Conclusion:** Consanguinity, intra and post natal severe dwarfism, mental retardation, body malformations with typical bird-headed aspect most likely indicate a diagnosis of Seckel's Syndrome worth being reported for its rarity.

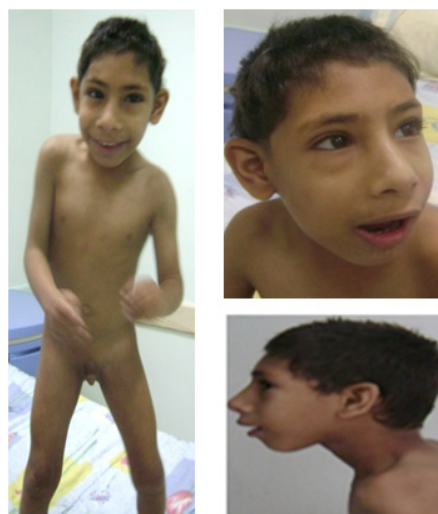**Key words:** Seckel's Syndrome, Dwarfism, Cardiac disease, Multiple congenital anomalies, Hypospadias, Kyphoscoliosis

**Introduction**

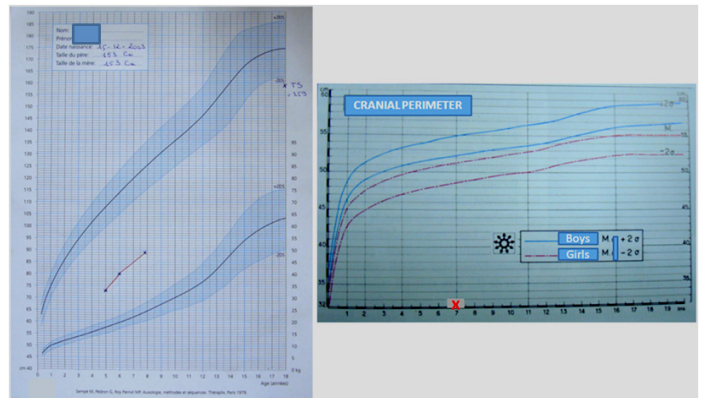
Seckel's Syndrome (SS) or "bird-headed" syndrome is an extremely rare genetic disease inherited in an autosomal recessive manner with severe intra and post natal dwarfism plus malformations. SS was described for the first time in 1960. Its mechanism is still unknown, but it is characterized by genetic heterogeneity (1-4) with chromosomal instability in fragile sites (5). The numerous gene abnormalities are responsible for clinical heterogeneity and different malformations (6-8) although some heart diseases may be incidental. Our aim was to describe the first case observed in our practice and provide a focused literature review on this condition.

**Case Report**

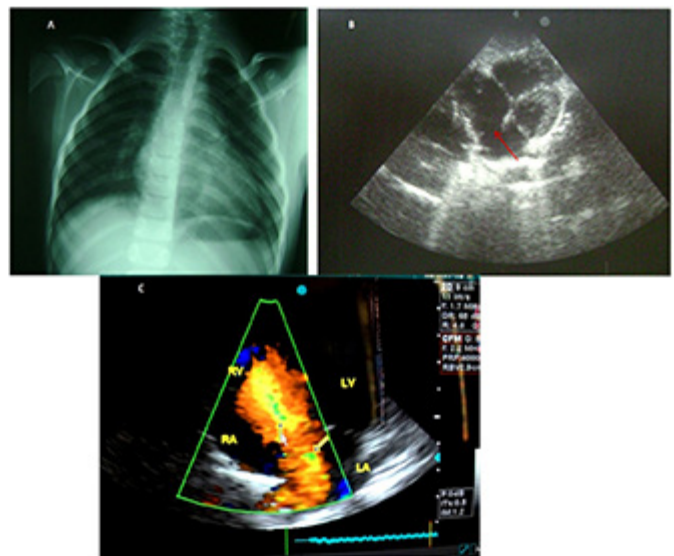
A boy aged 7, who weighed 1.9kg at birth, was referred to our unit for severe dwarfism. His family history was unremarkable except for consanguinity as his parents are first cousins. Clinical examination showed a restless boy, with incomprehensible language and a head that looked like a bird's (Figure 1). His small forehead and micrognathia contrasted with very large eyes, and a large and sharp nose. In addition to the dysmorphic face, we also noted kyphoscoliosis, flat feet, hypospadias, and systolic heart murmur heard in the pulmonic area of the chest and radiating into the back. There was no sign of right cardiac insufficiency. He weighed 8kg and measured 81 cm (-6SD), cranial perimeter was 31cm. The upper body segment measured 40cm, and the lower one 41cm. The arm span was 80cm indicating a proportionate short stature. His linear growth chart and cranial perimeter chart are depicted in figure 2. His



**Figure 1.** showing the proband with a bird-headed face.

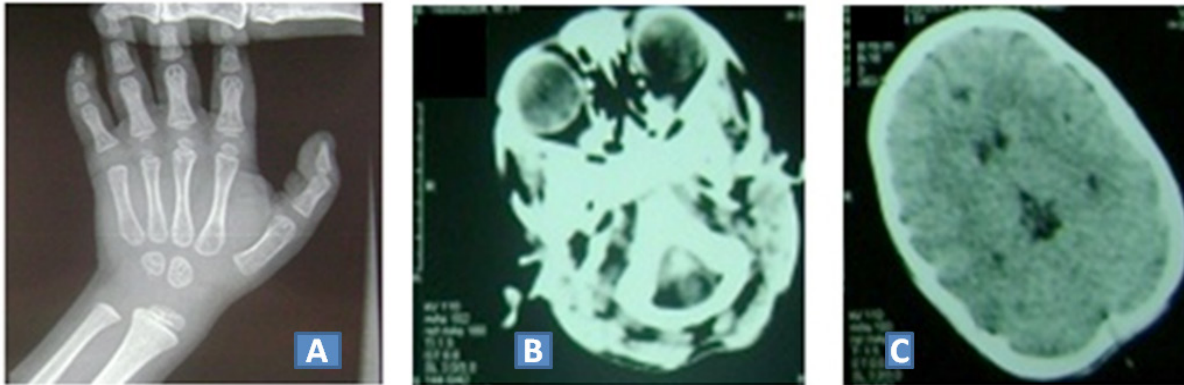


**Figure 2.** Patient's linear growth and cranial perimeter showing a severe dwarfism and very small cranial perimeter (red cross).



**Figure 3.** (A) Chest X-ray showing cardiomegaly, (B) Echocardiography showing a large atrial-septal defect, and (C) colour flow imaging showing a jet of blood from the left atrium to the right atrium. Notice the enlarged right atrium and ventricle.

mental age performed by Wechsler Intelligence Scale for Children (WISC: mental age/real age x100) corresponded to 17 months. Routine analyses and haematological assessments were unremarkable. Chest x-ray showed moderate cardiomegaly (figure 3A). Echocardiography revealed a large atrial-septal defect with enlarged right atrium and ventricle (figure 3B). Colour flow imaging demonstrated a jet of blood from the left atrium to the right atrium (Figure 3C ). His bone age was equal to 2 years (Figure 4A). Brain CT scan was normal except for large orbital cavities (Figure 4B) and fingerprints suggestive of craniostenosis (Figure 4C). Cerebral MRI showed a thickening of the cortical ribbon with bilateral hemispheric depletion of



**Figure 4.** Bone-aging radiography showing bone age=2years (A) and computed tomography of the brain showing large orbital cavities (B), and fingers prints (C).

**Table 1.** The patient's results and reference ranges of the endocrine investigations showing: normal cortisol, thyroid function, gonadal function for age, 17 hydroxyprogesterone, dehydroepiandrosterone sulphate, basal and glucagon-propranolol stimulated GH and circulating IGF-1.

Parameters	Patient's Values	Reference Ranges
Serum Cortisol (nmol/l)	353	154-368
Serum TSH (uIU/ml)	1.59	0.2-4.0
Serum free T4 (pmol/l)	16.2	8-24
Serum FSH (mIU/l)	0.95	0.4-1.6
Serum LH (mIU/l)	0.25	1.6-5.7
Serum Testosterone (nmol/l)	0.26	0.17-0.39
Serum 17 Hydroxyprogesterone (nmol/l)	0.45	0.30-2.42
Serum DHEA (ng/dl)	7.94	30-33
Basal Serum GH (mIU/ml)	1.2;1.5	0-20
Stimulated GH (mIU/ml)	72	60±22
Serum IGF-1 (ng/ml)	175	57-316

*TSH=thyroid stimulating hormone, free T4= FT4, FSH =follicle stimulating hormone, LH= luteinising stimulating hormone, 17hydroxyprogesterone= 17OHP, and dehydroepiandrosterone sulphate = DHEA S, Growth hormone= GH; Insulin-like growth factor 1=IGF-1.*

cortical furrows and a partial agenesis of the corpus callosum (not shown). Endocrine tests were normal (Table 1), even for growth hormone response to the stimulation test by glucagon-propranolol. IGF-1 was normal too: 175ng/ml (n=57-316). IGFBP-3 and genetic screening were not available because of his parents' low socioeconomic status. In summary, a small weight at birth with severe postna-

tal dwarfism, debility, and bird-headed facial features with craniostenosis, and large atrial-septal defect added to consanguinity pleaded for Seckel's or Seckel-like Syndrome. This congenital and heterogeneous syndrome is worth being known by endocrinologists, paediatricians, neurologists and cardiologists for a multidisciplinary approach.

## Discussion

Seckel's Syndrome is a very rare congenital disease as it occurs in only 1/10,000 children without sex preference (9). It includes severe intrauterine growth retardation, mental retardation, and postnatal dwarfism with a typical face that looks like a bird's; that is why this condition was named "bird-headed syndrome" by Rudolf Virchow (10). It was described for the first time more than sixty years ago by Mann and Russell in 1959, then by Seckel in 1960 (5,9,10). Although, its real origin is still mysterious, it is well known that Seckel's Syndrome, due to chromosome instability, is inherited in an autosomal recessive manner (1,9,11). In this heterogeneous condition, several loci (SCKL1-5) were mapped, but only three important abnormal genes were identified: ATR or ATRP (Ataxi telangiectasia-related protein), CENPJ (centromere protein J), and CEP152 (centrosomal protein 152kDa) which means genes that control cellular responses to DNA damage (12). SCKL1, located in the 3q22.1-1-q24 area, was found in two consanguineous Pakistani families. SCKL2 located in the 18p11.31-q11.2 position was discovered in a consanguineous Iraqi family. SCKL3 located on chromosome 14q was observed in five Turkish families (3,5,9,13). SCKL4, situated on chromosome 13q12 (2), was found in a Saudi Arabian consanguineous family. SCKL5, situated on the chromosome 15q21, was discovered in a Pakistani family as well (12). But, as the syndrome is very heterogeneous other abnormalities may be discovered in future. On clinical examination, the typical dymorphic face consists of microcephaly, recessed forehead and chin, larges eyes and a prominent beaked nose. Other abnormalities such as dental malformations can exaggerate the disproportionate face. The lack of growth begins in the womb and continues after birth. The reported mean weight at birth is equal to 1543g (1000- 2055g), and the proportionate short stature is often severe as it varies from -5 to -13SD. Reported mean head circumference is equal to -8.7 SD and varies from -4 to -14SD (14). Other abnormalities such as hydrocephalus (15,16), vascular malformations (9) and aneurysms (17) have been reported. Skeletal or limbs deformities, and dental malformations such as hypodontia, enamel hypoplasia, crowding, and malocclusion have been described as well (18). Kidney, skin, and nail abnormalities are also reported (19). Haematological problems such as hypoplastic or aplastic anaemia (20,21), pancytopenia (22), and acute myeloid leukaemia (23) have been reported in some patients. Mental retardation varies from case to case, and may be discrete or severe (13,14). The described child suffers from severe debility with restless syndrome. For heart abnormal-

ities, only a few congenital heart diseases, with or without heart failure, have been reported so far. The reported abnormalities are atrial-ventricular defect (24), inter-ventricular communication, and other malformations such as complex ductus arteriosus, Fallot's tetralogy (25), and atrial-septal defect. Atrial-septal defect has been reported for the first time in a Japanese child (6). The second case was described by Arnold et al. in a child with Seckel's-like Syndrome (7) and the third case was reported in 2009 by Panigrahi et al. (8). Our case is probably the fourth one although this malformation may be incidental, because of it frequency in the general population. Heart malformations may be diagnosed early in utero by echosonography or later as in our patient in whom both the right atrium and ventricle were dilated although there was no sign of clinical heart insufficiency. Heart malformations can be very severe causing death before birth or just after, which probably explains the rarity of the described syndrome.

Endocrine abnormalities are not well known in Seckel's Syndrome, but Dimitrescu et al. reported an empty sella without pituitary deficits (26), and Di Blasi et al. described a pituitary hypoplasia with lack in growth hormone (GH) stimulation (27). Deficit in corticotropin hormone or ACTH was observed by Kajantie et al. (28). Pituitary deficits may worsen the short stature and mental retardation. Diabetes mellitus with insulin-resistance is also reported in adulthood (29). In our case, the endocrine assessment was normal even for growth hormone under stimulation by glucagon propanolol test, and IGF1. The natural history of growth retardation and facial characteristics of Seckel's Syndrome raise some potential differential diagnoses, especially osteodysplastic primordial dwarfisms (OPDs) type I, II, and III and Russel-Silver's Syndrome (26). As our patient did not have any bone abnormality (except for kyphoscoliosis) the OPDs were not discussed. Some authors consider OPDs as variations of Seckel's Syndrome. The variability of such associated malformations and lack of specific genetic markers of this syndrome raises the possibility of further modifications in the classification of this heterogeneous disease.

Russel-Siver's Syndrome shares the intrauterine growth retardation with the described syndrome, but in Russel-Silver's syndrome the cranial perimeter is generally normal, the face is more triangular, the ears are very small, and the mental retardation is less severe or totally absent. This is why this syndrome seemed unlikely in our patient.

For treatment, there is no specific one. On the endocrine side, thyroid hormones and glucocorticoids can be prescribed easily when necessary, but recombinant growth hormone (rGH) treatment is debated. Some authors think rGH is not useful, because some cases seem to be resistant to growth hormone, as their GH, IGF-1, IGF-2 and IGF-3 are elevated (29,30). Others think it should be avoided in a child with craniostenosis or hematologic disorders, because chromosome instability is known to predispose to cancer development. For the third group, GH therapy can be used without risk (31) in order to increase growth velocity as in other cases of intra uterine growth retardation. Psychological help is also necessary for the affected child. Parents need social and psychological help to care for their handicapped children, especially those suffering from a restless syndrome as in the reported child. Genetic counselling is mandatory in family intermarriages, or when a couple has a child with Seckel's Syndrome. Ultrasonic assessment of the facial area together with the measurements of fetal head and heart examination are mandatory for an early prenatal diagnosis (32).

#### Final Remarks

Seckel's or Seckel-like Syndrome is a very rare entity due to mutations of particular genes inducing chromosome instability leading to severe intrauterine and post natal dwarfism with a bird-headed aspect, mental retardation, various malformations, and endocrine or haematological disorders. The different manifestations of the syndrome should be checked and diagnosed as early as possible to avoid a poor prognosis, especially death caused by cardiac insufficiency, arrhythmias, or pituitary insufficiency. For disease prevention, genetic counselling is mandatory.

**Authors' Note:** Written informed consent of the patient's parents has been obtained to show and publish photos and radiological pictures.

#### References

1. Faivre L, Le Merrer M, Lyonnet S, Plauchu H, Dagonneau N, Campos-Xavier AB, et al. Clinical and genetic heterogeneity of Seckel syndrome. *Am J Med Genet.* 2002;112:379-83.
2. Al-Dosari MS, Shaheen R, Colak D, Alkuraya FS. Novel CENPJ mutation causes Seckel syndrome. *Med Genet.* 2010;47:411-4.
3. Willems M, Genevieve D, Borck G, Baumann C, Baujat G, Bieth E, et al. Molecular analysis of pericentrin gene (PCNT) in a series of 24 Seckel/microcephalic osteodysplastic primordial dwarfism type II (MOPD II) families. *J Med Genet.* 2010;47:797-802.
4. Griffith E, Walker S, Martin CA, Vagnarelli P, Stiff T, Vernay B, et al. Mutations in pericentrin cause Seckel syndrome with defective ATR-dependent DNA damage signaling. *Nat Genet.* 2008;40:232-6.
5. Casper AM, Durkin SG, Arlt MF, Glover TW. Chromosomal instability at common fragile sites in Seckel syndrome. *Am J Hum Genet.* 2004;75:654-60.
6. Fukuda S, Morishita Y, Hashiguchi M, Taira A. Seckel's syndrome associated with atrial septal defect: a case report and review of the literature in Japan. *Kyobu Geka.* 1991;44:411-3.
7. Arnold SR, Spicer D, Kouseff B, Lacson A and Gilbert-Barnes E. Seckel-like syndrome in three siblings. *pediatric and developmental pathology* 1999;2:180-7.
8. Panigrahi I, Satvinder Kaur S, Kulkarni K, Das R, and Marwah RK. Seckel syndrome with chromosomal 18 deletions. *Indian J Pediatr* 2009;76:1270-1.
9. Codd PJ, Scott RM, Smith ER. Seckel syndrome and moyamoya. *J Neurosurg Pediatr.* 2009;3:320-4.
10. Harsha Vardhan BG, Muthu MS, Saraswathi K, Koteeswaran D. Bird-headed dwarf of Seckel. *J Indian Soc Pedod Prevent Dent.* 2007:S8-9.
11. O'Driscoll M, Gennery AR, Seidel J, Concannon P, Jeggo PA. An overview of three new disorders associated with genetic instability: LIG4 syndrome, RS-SCID and ATR-Seckel syndrome. *Elsevier DNA repair* 2004;3:1227-35.
12. Qvist P, Huertas P, Jimeno S, Nyegaard M, Hassan MJ, Jackson SP, et al. CtIP Mutations cause Seckel and Jawad Syndromes. *PLoS Genet* 2011;7:e1002310.
13. Faivre L, Cormier-Daire V. Seckel syndrome. *Orphanet encyclopedia.* 2005, 1-3.
14. Thompson E, Pembrey M. Seckel syndrome: an over diagnosed syndrome. *J Med Genet.* 1985;22:192-201.
15. Thapa R, Mukherjee K. Seckel syndrome with asymptomatic tonsillar herniation and congenital mirror movements. *J Child Neurol.* 2010;25:231-3.
16. Kumar R, Rawal M, Agarwal S, Gathwala G. Semilobar holoprosencephaly in Seckel syndrome. *Indian J Pediatr.* 2008;75:519-20.
17. Di Bartolomeo R, Polidori G, Piastra M, Viola L, Zampino G, Chiaretti A. Malignant hypertension and cerebral haemorrhage in Seckel syndrome. *Eur J Pediatr.* 2003;162:860-2.
18. Regen A, Nelson LP, Woo SB. Dental manifestations associated with Seckel syndrome type II: a case report. *Clin Dysmorphol.* 2004;13:53-5.

19. Parent P, Moulin S, Munck MR, De Parscau L, Alix D. Bird beaked dwarfism in Seckel syndrome. Nosologic difficulties. *Arch pediatr*. 1996;3;55-62.
20. Esperou-Bourdeau H, Leblanc T, Schaison G, Gluckman E. Aplastic anemia associated with "bird-headed" dwarfism (Seckel syndrome). *Nouv Rev Fr Hematol*. 1993;35:99-100.
21. Lilleyman JS. . Constitutional hypoplastic anemia associated with familial "bird-headed" dwarfism (Seckel syndrome). *Am J Pediatr Hematol Oncol*. 1984;6:207-9.
22. Butler MG, Hall BD, Maclean RN, Lozzio CB. Do some patients with Seckel syndrome have hematological problems and/or chromosome breakage? *Am J Med Genet*. 1987;27:645-9.
23. Hayani A, Suarez CR, Molnar Z, LeBeau M, Godwin J. Acute myeloid leukaemia in a patient with Seckel syndrome. *J Med Genet*. 1994;31:148-9.
24. Ucar B, Kilic Z, Dinleyici EC, Yakut A, Dogruel N. Seckel syndrome associated with atrioventricular canal defect: a case report. *Clin Dysmorphol*. 2004;13:53-5.
25. Can E, Bulbul A, Uslu S, Demirin H, Comert S, Bolat F, et al. A case of Seckel syndrome with Tetralogy of Fallot. *Genet Couns*. 2010;21:49-51.
26. Dumitrescu C, Procopiuc C, Chirita C, Carsote M, Dumitrescu A, Caragheorgheopol A, Poiana A. A case of severe growth retardation, probably Seckel syndrome. *Acta Endocrinologica (Buc)* 2010;6:361-9.
27. Di Blasi S, Belvedere M, Pintacuda S, Di Blasi U, Ferotti N, Galante S, et al. Seckel's syndrome: a case report. *J Med*. 1993;24:75-96.
28. Kajantie E, Otonkoski T, Kivirikko S, Somer M. A syndrome with multiple malformations, mental retardation, and ACTH deficiency. *Am J Med Genet* 2004;126A:313-8.
29. Kebapci N, Onbasi K, Yorulmaz G, Efe B, Basma KH. Possible effects of IGF-1 and IGF-3 in the development of growth failure, type 2 diabetes mellitus and severe insulin resistance in a case of Seckel syndrome. *Endocrine Abstracts*. 2009;20:276.
30. Schmidt A, Chakravarty A, Brommer E, Fenne BD, Siebler T, De Meyts P, Kiess W. Growth failure in a child showing characteristics of Seckel syndrome: possible effects of IGF-I and endogenous IGFBP-3. *Clin Endocrinol (Oxf)* 2002;57:293-9.
31. Bajpai A and Menon PSN. Growth hormone therapy. *Indian j pediatr* 2005;72:139-44.
32. Majoor-Krakauer DF, Wladimiroff JW, Stewart PA, van de Harten JJ, Niermeijer MF, Neri G, et al. Microcephaly, micrognathia, and bird-headed dwarfism: Prenatal diagnosis of a Seckel-like syndrome. *Am J Med Genet*. 1987;27:183-8.