
Double fenestration of the anterior communicating artery: “The figure-of-8” anomaly

Sir,

Anterior communicating artery (ACoA) is the commonest site for congenital variations in the anatomy of the circle of Willis.^[1] The association of variations in normal anatomy with aneurysms is well

known with one study reporting a 7.9% incidence of ACoA aneurysms being associated with fenestration of the ACoA.^[2] We present herein a rare variation in the anatomy of the ACoA complex – a double fenestration – that we have termed the “figure-of-8 anomaly.”

The patient was a 23-year-old male who presented with clinical and radiological features of subarachnoid hemorrhage. A four-vessel conventional angiography showed an anterior communicating artery (ACoA) aneurysm filling from the left A1 with a hypoplastic right A1 segment. Three-dimensional rotational angiography (3D-RA) reconstructions revealed a double fenestration in the ACoA with the aneurysm arising from the distal channel of the ACoA and incorporating the wall of the left A2 segment [Figure 1]. This we called the “figure-of-8 anomaly.” The patient underwent a left pterional craniotomy, transylvian approach, and clipping of the aneurysm. A thinned out hypoplastic right A1 segment was identified along with a double fenestration of the ACoA. The aneurysm was secured with two 7-mm straight mini clips with one blade of each clip passing through the left fenestration and trapping the aneurysm [Figure 2a-c]. The patient

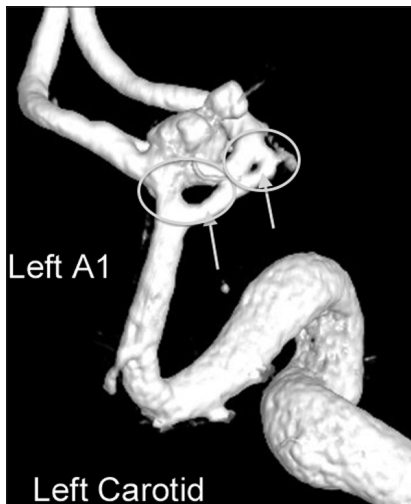

Figure 1: 3D-RA of left carotid injection showing a large necked aneurysm involving the ACoA and left A2 with a double fenestration in the ACoA—the “figure-of-8” anomaly

recovered uneventfully and was discharged on the 7th postoperative day.

The ACoA is formed by coalescing of a plexus of small vessels that connect the right and left half of the intracranial vasculature by the 27th week of gestation. This occurs to various extents leading to single or multiple fenestrations in the ACoA. Apart from this anomaly, other variations seen are a hypoplastic A1, azygous origin of the A2 as a single artery, duplication, and the presence of a midline artery of the corpus callosum (MACC) in addition to the A2s.^[3,4]

The reported incidence of a fenestration of the ACoA with an associated aneurysm at the same site is about 13%.^[5] The incidence of a double fenestration with an aneurysm is extremely rare and, since the first report of Kwak in 1980, only two more cases have been reported.^[3] Namiki in 2003 reported a case of double fenestration, where the presence of a MACC and duplication of the ACoA caused the same.^[6] De Oliveira in 2004 reported a case of true double fenestration with associated hypoplastic A1, with fenestrations at the origins of both A2's.^[5] Though this case is similar to ours in the presence of double fenestration and a hypoplastic A1, the aneurysm in our case was based on both the ACoA and the proximal A2, unlike in their report.

Double fenestration of the ACoA with an associated aneurysm is an extremely rare occurrence and poses a technical challenge to the operating surgeon. Securing the aneurysm and reconstruction of the ACoA with clips may be done taking advantage of the fenestrations, as in this case. The use of a preoperative 3D-RA is invaluable in the surgical planning in such cases since these anomalies are rarely identified on standard 2D digital subtraction angiography.

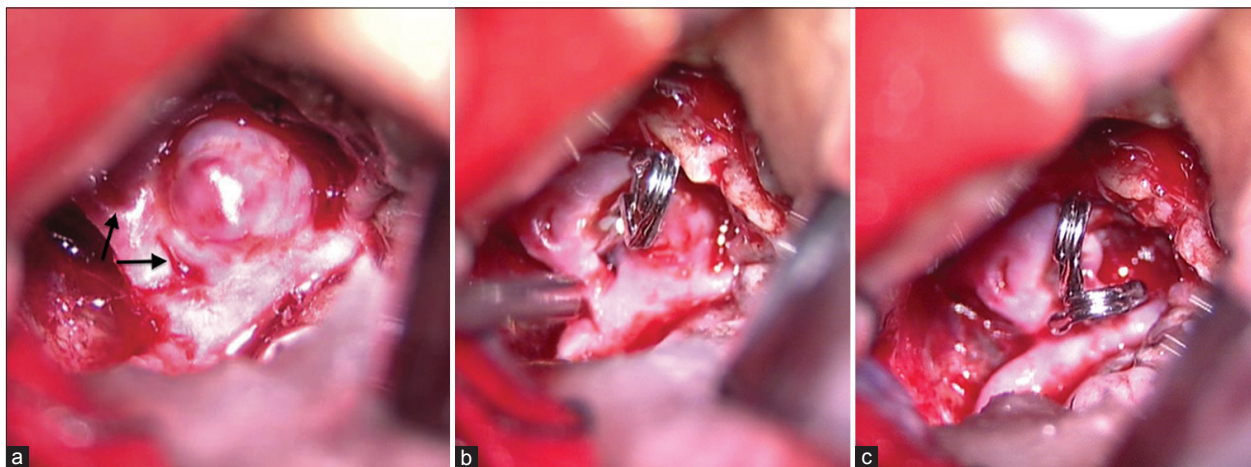


Figure 2: (a) Intra-operative photograph showing the aneurysm and the fenestrations; (b) intra-operative photograph following clip application on the right side of the aneurysm and (c) intra-operative photograph following securing the aneurysm with 2 clips on either side of the aneurysm

**B. V. Savitr Sastri, Srinivas Dwarakanath,
H. R. Arvinda¹, Somanna Sampath**

Departments of Neurosurgery and ¹Neuroradiology,
National Institute of Mental Health and Neuroscience
(NIMHANS), Bangalore, Karnataka, India.
E-mail: dwarakaneuro@yahoo.com

REFERENCES

1. Perlmutter D, Rhoton AL Jr. Microsurgical anatomy of the anterior cerebral-anterior communicating-recurrent artery complex. *J Neurosurg* 1976;45:259-72.
2. de Gast AN, van Rooij WJ, Sluzewski M. Fenestrations of the anterior communicating artery: Incidence on 3D angiography and relationship to aneurysms. *AJNR Am J Neuroradiol* 2008;29:296-8.
3. Kwak R, Niizuma H, Hatanaka M, Suzuki J. Anterior communicating artery aneurysms with associated anomalies. *J Neurosurg* 1980;52:162-4.
4. San-Galli F, Leman C, Kien P, Khazaal J, Phillips SD, Guerin J. Cerebral arterial fenestrations associated with intracranial saccular aneurysms.

Neurosurgery 1992;30:279-83.

5. de Oliveira JG, du Mesnil de Rochemont R, Beck J, Hermann E, Gerlach R, Raabe A, *et al.* A rare anomaly of the anterior communicating artery complex hidden by a large broad-neck aneurysm and disclosed by three-dimensional rotational angiography. *Acta Neurochir (Wien)* 2008;150:279-84.
6. Namiki J, Doumoto Y. Microsurgically critical anomaly of the anterior communicating artery complex during the pterional approach to a ruptured aneurysm: Double fenestration of the proximal A2 segments. *Neurol Med Chir (Tokyo)* 2003;43:304-7.

Access this article online	
Quick Response Code:	Website: www.ijns.in
	DOI: 10.4103/2277-9167.110226