

Multiple aneurysms with meningiomas: Coincidence or co-incidence?

Savitr Sastri, Dwarakanath Srinivas, Sampath Somanna

Department of Neurosurgery, National Institute of Mental Health and Neurosciences (NIMHANS), Hosur Road, Bangalore, Karnataka, India

INTRODUCTION

Co-existing multiple aneurysms and meningiomas are very unusual and only 17 such cases^[1,2] have been reported in available literature. In this article, we describe two cases, the first of their kind from India and review their etiopathogenesis. While, there is a school of thought that this co-existence is incidental, we believe that there may be some common factors in their co-genesis, which merits investigation as it may have implications in their prevention.

CASE REPORTS

Case 1

This patient was a 49-year-old housewife who presented with a history of on and off headache, predominantly occipital for 2 years prior to evaluation. A computed tomography (CT) scan done for persistent and intractable headache revealed an infratentorial torcular meningioma. On contrast sequences, an Internal carotid artery (ICA) bifurcation aneurysm on the right was also detected and a CT angiogram showed aneurysms involving the right ICA bifurcation and the left A1/medial lenticulostriate artery. [Figures 1a-c] She underwent a right pterional craniotomy and clipping of both aneurysms followed by a midline suboccipital craniectomy and excision of the torcular meningioma.

Case 2

A 56-year-old gentleman presented with history of sudden loss of consciousness from which he recovered with no deficits, but complained of persistent holocranial headache,

which gradually resolved over a week. He had no deficits except for bilateral subtle cerebellar signs and gait ataxia. Imaging revealed a right infratentorial meningioma arising from the tentorial surface and torcula. In addition, he also had aneurysms of the anterior communicating artery (ACoA), right middle cerebral artery (MCA), right

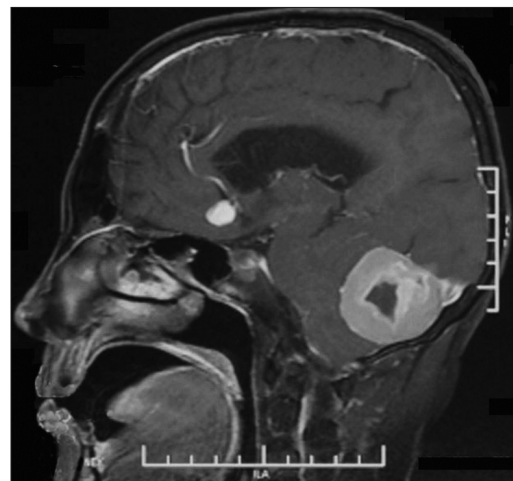


Figure 1a: Digital subtraction angiogram showing the presence of an anterior communicating artery, middle cerebral artery bifurcation, and posterior communication artery aneurysm

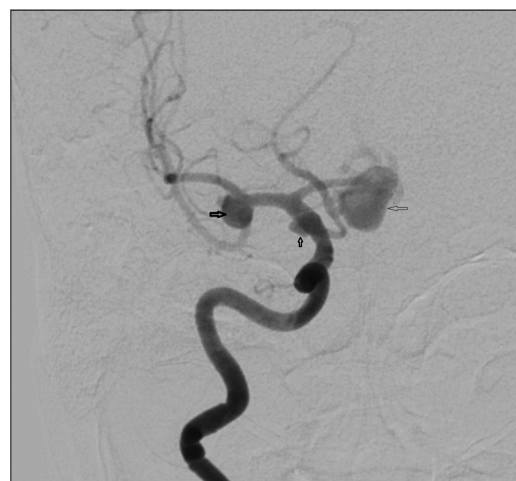

Figure 1b: Digital Subtraction angiogram showing the presence of a basilar top aneurysm

Access this article online	
Quick Response Code:	Website: www.ijns.in
	DOI: 10.4103/2277-9167.110232

Address for correspondence: Dr. Dwarakanath Srinivas,
Department of Neurosurgery, National Institute of Mental Health and Neurosciences (NIMHANS), Bangalore - 560 029, India.
E-mail: dwarakaneuro@yahoo.com

posterior communicating artery (PCoA), and the basilar bifurcation. [Figures 2a and b] He underwent a right

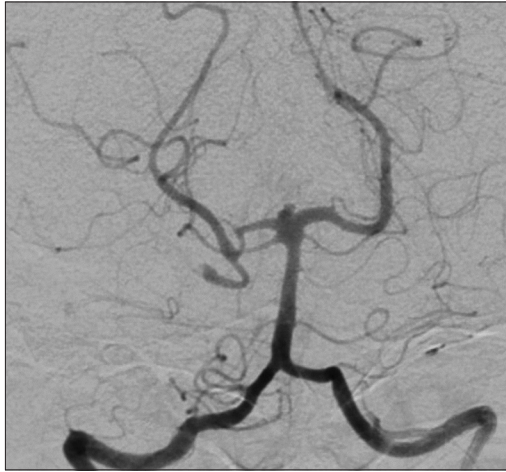


Figure 1c: Magnetic resonance imaging of the brain (Post contrast) showing the presence of a large infratentorial torcular meningioma

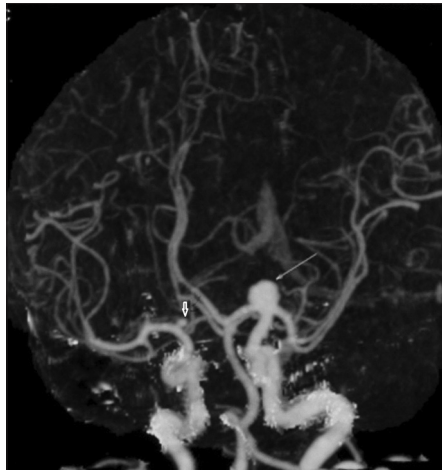


Figure 2a: Computerised tomogram angiogram showing the presence of a large right internal carotid artery aneurysm and Left A1/medial lenticulostriate artery (small arrow)

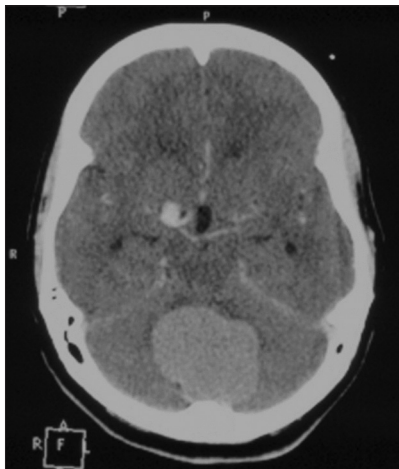


Figure 2b: Computerised tomogram imaging of the brain (Post contrast) showing the presence of a large infratentorial meningioma

frontotemporal craniotomy and orbitozygomatic osteotomy and clipping of the ACoA, MCA, and PCoA aneurysms. Following this, he underwent a midline suboccipital craniectomy and Simpson's grade II excision of the torcular meningioma. The patient recovered uneventfully and is planned for coiling of the basilar top aneurysm.

DISCUSSION

The association of intracranial meningioma and aneurysms has been a matter of debate. First reported by Arieti in 1944, over 110 cases have been reported in literature.^[1] Among these, only 17 of them have been associated with multiple aneurysms. Most authors have attributed it to a co-incidence, whereas others have attributed local flow alterations or vessel invasion to their co-incidence. Although it is true that there is a pronounced proximity of the localization of aneurysm on the feeding arteries, we feel that there is more to it than that meets the eye. This is due to the fact that in multiple aneurysms, they are not in proximity to the tumor.

Pia *et al.*^[3] postulated a possible dysgenetic factor in their etiology. There have been reports about the influence of estrogen in the genesis of both meningiomas and aneurysms, while genetic mutations on 1p36, 11q13, and 17p13 have been described in both these pathologies. It is also worthwhile to note that Klippel–Trenaunay syndrome, characterized by multiple meningiomas and arterial aneurysms, may support their co-incidence. Keeping all the above factors in mind, it is worthwhile to explore the possibility of dysplastic growth factor in their genesis, which may have potential implications in the prevention of genesis of these conditions.

CONCLUSION

These two cases add to the available literature on co-existing sparse multiple aneurysms and meningiomas and also are the first from India.

REFERENCES

1. Fischer BR, Palkovic S, Holling M, Niederstadt T, Jeibmann A, Wassmann H. Coexistence of cerebral aneurysm and meningioma: Pure accident? *Clin Neurol Neurosurg* 2009;111:647-54.
2. Javalkar V, Guthikonda B, Vannemreddy P, Nanda A. Association of meningioma and intracranial aneurysm: Report of five cases and review of literature. *Neurol India* 2009;57:772-6.
3. Pia HW, Obrador S, Martin JG. Association of brain tumours and arterial intracranial aneurysms. *Acta Neurochir (Wien)* 1972;27:189-204.

How to cite this article: Sastri S, Srinivas D, Somanna S. Multiple aneurysms with meningiomas: Coincidence or co-incidence?. *Indian J Neurosurg* 2013;2:99-100.

Source of Support: Nil, **Conflict of Interest:** None declared.