

Surgery in multisegmental cervical spondylotic myelopathy: Outcome analysis in a series of 65 patients

Sumit Sinha, K. B. Shankar¹, Shashank Sharad Kale, Bhawani Shankar Sharma

Departments of Neurosurgery, Neurosciences Centre, All India Institute of Medical Sciences, ¹Safdarjung Hospital, New Delhi, India

ABSTRACT

Background: Multi-segmental cervical spondylotic myelopathy (MS-CSM) can be dealt with by either anterior or posterior approaches. The aim of study was to analyze the surgical outcomes of MS-CSM treated by either anterior cervical discectomy with fusion and cervical plating (ACDF) or cervical laminoplasty (LP). **Materials and Methods:** Sixty-five patients with MS-CSM (two or more levels) underwent either ACDF ($n=13$) or LP ($n=52$). ACDF was performed in patients having these criteria: (i) three or less levels involved, (ii) myeloradiculopathy, (iii) pre-dominant anterior compression radiologically, (iv) <50 years age. LP was chosen in: (i) more than three levels involved (ii) posterior compression radiologically, (iii) >50 years age. Patients were evaluated pre- and post-operatively on the basis of modified Japanese Orthopedic Association (mJOA) scoring and Hirabayashi formula. Thirty-five patients were followed up (8 in ACDF group and 27 in LP group). The mean follow-up period was 37.5 months (12.5-54 months). **Results:** The mean pre-operative mJOA score in the ACDF group and the LP group was 11 ± 2.62 and 10.6 ± 2.04 , respectively. The mean final post-operative mJOA score in the ACDF group ($n=8$) in follow-up was 14.12 ± 2.36 ($P<0.05$) and in the LP group ($n=27$) was 14.63 ± 1.64 ($P<0.05$). 86% had good-to-excellent outcome while 8.5% had poor outcome. Overall, the mean recovery was $64.73\pm 18.9\%$. On analyzing two groups separately, the mean recovery in the ACDF group was 59.62 ± 24.2 , while in the LP group was 66.25 ± 17.3 ($P<0.05$). **Conclusions:** The choice of ACDF and LP in MS-CSM depends on pre-operative clinical and radiological parameters. If the surgical approach is chosen correctly, the surgery in MS-CSM can result in significant improvement in the clinical outcome of these patients.

Key words: Anterior cervical discectomy and fusion, laminoplasty, modified Japanese scoring system, multi-segmental cervical spondylotic myelopathy, surgical approaches

INTRODUCTION

Cervical spondylotic myelopathy (CSM) is the most common cause of spinal dysfunction in elderly.^[1,2] It is also the most common cause of non-traumatic spastic quadriparesis. Spondylotic changes commonly occur as a result of disc degeneration. Besides disc-associated spondylotic degenerative changes, ossification of the posterior longitudinal ligament (OPLL), which is pre-dominantly observed in certain Asian populations, can also occur with cervical spondylosis and can result in severe anterior cord compression and subsequent clinical presentation like CSM.

Surgery is mainstay of treatment for patients with CSM and is generally recommended for patients who have both clinical and radiographic evidence consistent with CSM, as the disorder is typically progressive without surgery.^[3] Significant debate exists regarding the best surgical approach for treating cervical myelopathy.^[4] There are a number of options, including anterior decompression and fusion, laminectomy, laminectomy and fusion, and laminoplasty (LP). Each approach carries its own set of pros and cons, and there is no one procedure which is clearly favorable in all circumstances.

In this retrospective study, we have attempted to analyze the surgical outcomes of multi-segmental cervical spondylotic myelopathy (MS-CSM) treated by either anterior cervical discectomy with fusion and cervical plating (ACDF) or cervical LP.

MATERIALS AND METHODS

This retrospective study involved 65 patients with multi-segmental cervical spondylotic myelo-radiculopathy

Access this article online	
Quick Response Code:	Website: www.ijns.in
	DOI: 10.4103/2277-9167.118119

Address for correspondence: Dr. Sumit Sinha,
Department of Neurosurgery, VIIth Floor, Neurosciences Centre, All India Institute of Medical Sciences, New Delhi - 110 029, India.
E-mail: sumitaiims@yahoo.com

(two or more levels) who were surgically treated at our center over a period of 2 years. The ethical clearance was obtained from the Institutional ethics Committee prior to the start of study.

The details of patients were retrieved from the hospital database. Their demographic profile, clinical features, surgical details, post-operative outcomes, and complications were analyzed retrospectively.

There were 60 (92%) males and 5 (8%) females. The age ranged from 25 to 78 years (mean \pm SD = 55.9 \pm 10.8).

Non-contrast MRI of cervical spine was performed in all patients. The MRI films were reviewed carefully with a neuroradiologist for the presence of prolapsed inter-vertebral disc, ossified posterior longitudinal ligament or ligamentum flavum hypertrophy. The patients either underwent anterior cervical discectomy with fusion and instrumented fixation with a cervical plate ($n=13$) or LP only ($n=52$).

Surgical procedures

The ACDF was done using standard micro-surgical techniques. The discectomy was done at the involved levels and either iliac crest bone graft or polyetheretherketone (PEEK) cage was used to achieve bony fusion. All the patients underwent instrumented fusion using anterior cervical plate of appropriate size. None of the patient requiring decompression by anterior approach underwent corpectomy. In the LP group, open door LP was performed with fixation of the hinged laminae by means of titanium miniplates and screws. Combined procedure was not done in any patient.

The decision for the type of surgical approach was based on the surgeon's discretion and ACDF was the chosen procedure for: (i) three or less levels involved, (ii) myeloradiculopathy, (iii) pre-dominant anterior compression radiologically, (iv) sagittal cervical malalignment, and (v) <50 years age. LP was the chosen surgical approach in (i) more than three levels involved, (ii) pre-dominant posterior compression radiologically, (iii) maintained cervical lordosis, and (iv) patients > 50 years of age with comorbidities who cannot withstand major surgery.

Patients were evaluated pre- and post-operatively on the basis of the modified Japanese Orthopedic Association (mJOA) scoring system. To calculate improvement in myelopathy in the post-operative period, a formula proposed by Hirabayashi *et al.*^[5] was used.

(Final mJOA score – pre-operative mJOA score / 17 – pre-operative mJOA score) \times 100.

The outcome of the patients was graded as: (i) Excellent – 75-100% recovery, (ii) Good – 50-74% recovery, (iii) Fair – 25-49% recovery, and (iv) Poor – 0-24% recovery.

A detailed follow-up was conducted either in OPD or telephonically using mJOA scoring system [Table 1]. Out of 65 patients, 35 patients were followed up (8 in ACDF group and 27 in LP group). The mean follow-up period was 37.5 months (12.5-54 months).

Statistical analysis

The statistical analysis was performed using Stata 9.0 software. The Student "t" test was applied to continuous and categorical variables for comparing the improvement in two groups and to find out if the difference had statistical significance ($P < 0.05$).

RESULTS

Table 1 shows the presenting features. The duration of symptoms before surgical intervention ranged from 54 to 254 days (mean 137.6 days). The distribution of patients with respect to the number of segments involved in patients with MSCSM is shown in Table 2. Thirteen patients underwent ACDF while LP was performed in 52 patients. The pre-operative characteristics of patients are shown in Table 3. All the patients who underwent ACDF had anterior compression pre-dominantly, whereas pre-dominant posterior compression was present in 22% patients undergoing LP.

The pre-operative mJOA scores were 11 \pm 2.62 and 10.6 \pm 2.04, in the ACDF group and LP group, respectively. The mean final post-operative mJOA score in the ACDF

Table 1: Frequency of presenting symptoms

Symptoms	No. of patients (%)
Gait abnormality	59 (91)
Neck pain	24 (37)
Radiation of pain	22 (34)
Bladder involvement	18 (28)
Bowel involvement	3 (5)

Table 2: No. of segments affected in patients with CSM

No. of segments involved	No. of patients (%)
Two	4 (6)
Three	33 (51)
Four	11 (17)
Five	13 (20)
Six	4 (6)

CSM – Cervical spondylotic myelopathy

group in follow-up ($n=8$) was 14.12 ± 2.36 while that in the LP group ($n=27$) was 14.63 ± 1.64 [Figure 1]. There was statistically significant improvement in the post-operative mJOA scores in both the groups ($P=0.035$ in the ACDF group and $P=0.029$ in the LP group). Overall, the mean recovery was $64.73 \pm 18.9\%$. On analyzing the two groups separately, the mean recovery in the ACDF group was 59.62 ± 24.2 , while the mean recovery in the LP group was 66.25 ± 17.3 . However, this difference was not statistically significant (P value: 0.39). 30 patients (87%) had good to excellent outcome, 2 patients (6%) had fair outcome while the remaining 3 patients (8%) had poor outcome.

The pre-operative mJOA scores correlated well with the final recovery of the patient. Thirty patients with pre-operative mJOA scores of 10.6 had good-to-excellent improvement in clinical features, while five patients with very low pre-operative mJOA scores had fair-to-poor recovery [Table 4].

Complications

In the ACDF group, one patient developed hoarseness of voice in the post-operative period, which resolved after 8 weeks. One patient developed cerebrospinal fluid leak which was managed conservatively with lumbar drainage. This patient had focal OPLL and a calcified posterior longitudinal ligament which was densely adhered to dura. In the LP group, none of the patients demonstrated any deterioration of symptoms after surgery. One patient developed ipsilateral C5 palsy, which completely resolved in 6 months. One patient required long-term analgesics for constant axial neck pain. There were no implant-related complications in both the groups and none of the patient underwent repeat surgery because of the failure of the previous procedure.

DISCUSSION

Significant debate exists regarding the best surgical approach for treating cervical myelopathy. There are a number of options, including anterior decompression and fusion, laminectomy, and fusion, and LP. Considerations which may favor one approach *versus* another include: (i) the number of stenotic levels present; (ii) patient factors, such as co-morbidities; (iii) desire to either limit or preserve motion; (iv) cervical sagittal malalignment; and (v) location and extent of disease.^[4] In our study, the mean number of segments involved was 2.7 in patients treated with ACDF and 4.05 in the LP group. Anterior compression was present in 53 patients, while 12 patients had evidence of posterior compression. All the 13 patients undergoing ACDF had anterior compression while all the patients with pre-dominant posterior compression ($n=12$)

Table 3: Pre-operative patient characteristics

Characteristics	No. of patients (%)
No. of patients	13
Mean age (years)	53.6
Mean symptom duration (days)	137.6
Most common presenting symptom	Gait abnormalities
Myelopathy	59 (91)
Myelopathy+Radiculopathy	22 (34)
Mean no. of levels involved	3.5
Anterior compression	53 (81.5)
Posterior compression	12 (18.4)
Cord signal changes	27 (41.5)
OPLL	29 (44.6)
PIVD	53 (81.5)
LFH	12 (18.5)

OPLL – Ossification of the posterior longitudinal ligament; PIVD – Prolapsed intervertebral disc, LFH – Ligament flavum hypertrophy; ($n=65$)

Table 4: Recovery rate in follow-up in the two groups

Recovery	ACDF group ($n=8$) (%)	Laminoplasty group ($n=27$) (%)
Poor	1 (12.5)	2 (7.4)
Fair	1 (12.5)	1 (3.7)
Good	6 (75)	18 (66.6)
Excellent	0	6 (22.2)

ACDF – Anterior cervical discectomy with fusion

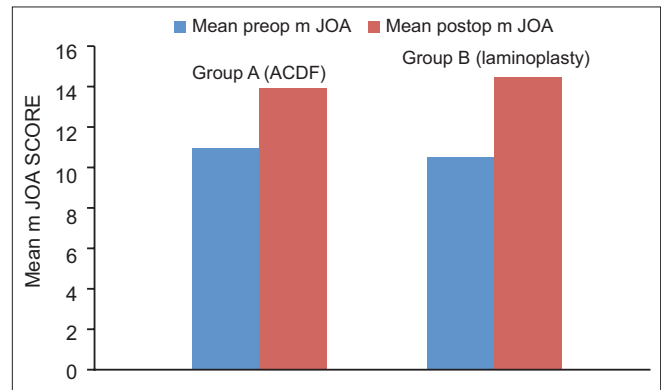


Figure 1: Bar diagram showing pre-operative and post-operative mJOA scores in both groups

as the offending pathology, underwent LP. The patients >50 years of age and having additional co-morbidities were selected for LP even in the presence of anterior compression. The mean age of patients in LP group was 57.5 years in our study as compared to 49.6 years in the ACDF group.

Emery *et al.*^[1] in a series of 108 patients demonstrated significant improvement in symptoms after ventral decompression and fusion. They concluded that the most significant predictive factor for recovery from myelopathy was the severity of pre-operative myelopathy. In concordance with various studies in the literature, in our study also, the pre-operative mJOA scores very

well correlated with the final recovery of the patients. Thirty patients with mean pre-operative mJOA scores of 10.6 had good to excellent (50-100%) improvement in clinical features, while five patients with very low pre-operative mJOA scores had fair to poor recovery. Zhang *et al.* demonstrated clinical improvement in 91% patients treated with anterior cervical decompression and fusion.^[6] In our study, clinical improvement in the follow-up was seen in all the patients undergoing ACDF ($n=8$), out of which six (75%) patients had good-to-excellent recovery.

In MSCSM, both ventral and dorsal approaches have been advocated for the treatment of OPLL.^[7-9] However, controversy exists regarding adequate decompression of the ossified ligament with a ventral approach,^[5,10] and there are concerns for surgery-related complications like cerebrospinal fluid leakage, graft dislodgement, pseudoarthrosis, accelerated adjacent level degeneration, and the necessity to achieve spinal fusion.^[11,12] Henceforth, LP was developed to address multilevel myelopathy for OPLL,^[5] which has fewer surgery-related complications when compared to anterior surgery.^[7,10] In our study, ventral or dorsal surgery was chosen pre-operatively depending on surgeon's discretion on the basis of presence of certain clinical and radiological parameters. ACDF was the procedure of choice for: (i) three or less levels involved (mean number of levels involved were 2.7), (ii) patients with myeloradiculopathy, (iii) patients with a pre-dominant anterior compression radiologically (iv) cervical sagittal malalignment, and (v) patients <50 years age. LP was the treatment in those patients with (i) more than three levels involved (mean number of levels involved were 4.05), (ii) posterior compression radiologically, (iii) maintained cervical lordosis, and (iv) patients >50 years age with comorbidities, who cannot withstand major surgery. The mean final post-operative mJOA score in the ACDF group in the follow-up ($n=8$) was 14.12 ± 2.36 while that in the LP group ($n=27$) was 14.63 ± 1.64 . Overall, the mean recovery was $64.73 \pm 18.9\%$. 30 patients (87%) had good to excellent outcome, 2 patients (6%) had fair outcome while the remaining 3 patients (8%) had poor outcome. On analyzing the two groups separately, the mean recovery in the ACDF group was 59.62 ± 24.2 , while that in the LP group was 66.25 ± 17.3 . This difference was not statistically significant.

Iwasaki *et al.*^[13,14] concluded that although ACDF is technically demanding and has a higher incidence of surgery-related complications, it is preferable to LP for patients with an occupying ratio of OPLL $\geq 60\%$. However, the authors performed anterior cervical corpectomies and not ACDF in their study, which might

have accounted for better results of anterior approach as compared to LP. In a similar study by Masaki *et al.*,^[15] the mean recovery rate was 68.4% in the ACDF group and 52.5% in the patients undergoing LP. These results demonstrated that the surgical outcome of ACDF was superior to the surgical outcome of LP. Tani *et al.*^[16] in a retrospective study of patients with multi-segmental OPLL have reported similarly better clinical results with ACDF as compared to LP. Sakaura *et al.*^[17] reported that LP and anterior spinal fusion provided equal neurologic improvement. Goubier *et al.*^[18] concluded that anterior approach is preferred in case of pain or brachialgia; the posterior approach is indicated in the case of poor health status or for bedridden patients. Neurological status improved in 83% of the patients.

Wang *et al.*^[19] retrospectively reviewed the clinical outcomes in 204 cases of MS-CSM treated by open door LP. Post-operatively, Nurick scores improved by 1 point in 78 patients, 2 points in 37 patients, 3 points in 7 patients, and 4 points in 5 patients; 74 patients experienced no improvement and 3 patients deteriorated by 1 point. They concluded that LP is an alternative to anterior surgery that can be accomplished quickly with minimal blood loss, minimizing risks in elderly patients.

George *et al.*^[20] described the technique of multilevel oblique corpectomies (MOC) without fusion in the treatment of MS-CSM. MOC was performed using an anterolateral approach with control of the vertebral artery. The vertebral bodies were drilled obliquely from the lateral side toward the opposite posterolateral corner saving more than half of the vertebral bodies. They reported improvement in 82% of the patients, worsening in 8%, and stabilization in 10%. The authors concluded that MOC is a safe and efficient technique and must be applied for patients with anterior compression and straight or kyphotic axis of the spine. No fusion is required regardless of the number of levels, providing there are no soft discs and there is no pre-operative instability.

In the present study, we have analyzed surgical outcomes of the two most commonly used surgical approaches in the treatment of MS-CSM, namely ACDF ($n=13$) and LP ($n=52$) in a series of 65 patients. There was statistically significant improvement in the post-operative mJOA scores in both the groups as compared to the pre-operative mJOA scores. The surgical approach was chosen on the basis of certain clinical and radiological parameters. This study shows that if the surgical approach is chosen correctly, the surgery in MS-CSM can result in significant improvement in the clinical outcome of these patients.

REFERENCES

1. Emery SE. Cervical spondylotic myelopathy: Diagnosis and treatment. *J Am Acad Orthop Surg* 2001;9:376-88.
2. Young WF. Cervical spondylotic myelopathy: A common cause of spinal cord dysfunction in older persons. *Am Fam Physician* 2000;62:1064-73.
3. Sampath P, Bendebba M, Davis JD, Ducker TB. Outcome of patients treated for cervical myelopathy. A prospective, multicenter study with independent clinical review. *Spine (Phila Pa 1976)* 2000;25:670-6.
4. Emery SE, Bohlman HH, Bolesta MJ, Jones PK. Anterior cervical decompression and arthrodesis for the treatment of cervical spondylotic myelopathy. Two to seventeen-year follow-up. *J Bone Joint Surg Am* 1998;80:941-51.
5. Hirabayashi K, Toyama Y, Chiba K. Expansive laminoplasty for myelopathy in ossification of the longitudinal ligament. *Clin Orthop Relat Res* 1999;359:35-48.
6. Zhang ZH, Yin H, Yang K, Zhang T, Dong F, Dang G, *et al.* Anterior inter-vertebral disc excision and bone grafting in cervical spondylotic myelopathy. *Spine (Phila Pa 1976)* 1983;8:16-9.
7. Cheng WC, Chang CN, Lui TN, Lee ST, Wong CW, Lin TK. Surgical treatment for ossification of the posterior longitudinal ligament of the cervical spine. *Surg Neurol* 1994;41:90-7.
8. Lunsford LD, Bissonette DJ, Zorub DS. Anterior surgery for cervical disc disease. Part 2: Treatment of cervical spondylotic myelopathy in 32 cases. *J Neurosurg* 1980;53:12-9.
9. Yamaura I, Kurosa Y, Matuoka T, Shindo S. Anterior floating method for cervical myelopathy caused by ossification of the posterior longitudinal ligament. *Clin Orthop Relat Res* 1999;359:27-34.
10. Matsuoka T, Yamaura I, Kurosa Y, Nakai O, Shindo S, Shinomiya K. Long-term results of the anterior floating method for cervical myelopathy caused by ossification of the posterior longitudinal ligament. *Spine (Phila Pa 1976)* 2001;26:241-8.
11. Bohlman HH, Emery SE, Goodfellow DB, Jones PK. Robinson anterior cervical discectomy and arthrodesis for cervical radiculopathy. Long-term follow-up of one hundred and twenty-two patients. *J Bone Joint Surg Am* 1993;75:1298-307.
12. Döhler JR, Kahn MR, Hughes SP. Instability of the cervical spine after anterior interbody fusion. A study on its incidence and clinical significance in 21 patients. *Arch Orthop Trauma Surg* 1985;104:247-50.
13. Iwasaki M, Okuda S, Miyauchi A, Sakaura H, Mukai Y, Yonenobu K, *et al.* Surgical strategy for cervical myelopathy due to ossification of the posterior longitudinal ligament: Part 1: Clinical results and limitations of laminoplasty. *Spine (Phila Pa 1976)* 2007;32:647-53.
14. Iwasaki M, Okuda S, Miyauchi A, Sakaura H, Mukai Y, Yonenobu K, *et al.* Surgical strategy for cervical myelopathy due to ossification of the posterior longitudinal ligament: Part 2: Advantages of anterior decompression and fusion over laminoplasty. *Spine (Phila Pa 1976)* 2007;32:654-60.
15. Masaki Y, Yamazaki M, Okawa A, Aramomi M, Hashimoto M, Koda M, *et al.* An analysis of factors causing poor surgical outcome in patients with cervical myelopathy due to ossification of the posterior longitudinal ligament: Anterior decompression with spinal fusion versus laminoplasty. *J Spinal Disord Tech* 2007;20:7-13.
16. Tani T, Ushida T, Ishida K, Iai H, Noguchi T, Yamamoto H. Relative safety of anterior microsurgical decompression versus laminoplasty for cervical myelopathy with a massive ossified posterior longitudinal ligament. *Spine (Phila Pa 1976)* 2002;27:2491-8.
17. Sakaura H, Hosono N, Mukai Y, Ishii T, Iwasaki M, Yoshikawa H. Long-term outcome of laminoplasty for cervical myelopathy due to disc herniation: A comparative study of laminoplasty and anterior spinal fusion. *Spine (Phila Pa 1976)* 2005;30:756-9.
18. Goubier JN, Benazet Dagger JP, Saillant G. Surgical decompression of cervical arthrotic myelopathies: Comparison of surgical anterior and posterior approaches [Article in French]. *Rev Chir Orthop Reparatrice Appar Mot* 2002;88:591-600.
19. Wang MY, Shah S, Green BA. Clinical outcomes following cervical laminoplasty for 204 patients with cervical spondylotic myelopathy. *Surg Neurol* 2004;62:487-93.
20. George B, Gauthier N, Lot G. Multisegmental cervical spondylotic myelopathy and radiculopathy treated by multilevel oblique corpectomies without fusion. *Neurosurgery* 1999;44:81-90.

How to cite this article: Sinha S, Shankar KB, Kale SS, Sharma BS. Surgery in multisegmental cervical spondylotic myelopathy: Outcome analysis in a series of 65 patients. *Indian J Neurosurg* 2013;2:170-4.

Source of Support: Nil, **Conflict of Interest:** None declared.