

The therapeutic effect of cranioplasty in severe head injuries: Report of two cases

Salvatore Chibbaro^{1,3}, Marco Marsella², Leonardo Tigan¹, Eric Vicaut⁶, Bernard George³, Jean-Pierre Guichard⁴, Fabrice Vallee⁵, Pierre Kehrl¹, Kourban Houssen¹, Paolo Diemidio¹, Jean-Julien Keppi¹

¹Department of Neurosurgery, Strasbourg University Hospital, Strasbourg, ²Private Neurosurgeon, (Associate University Arizona Medical Center), ³Departments of Neurosurgery, ⁴Neuroradiology, and ⁵ICU, Lariboisiere University Hospital, ⁶Unité de Recherche Clinique Hôpital Universitaire Lariboisière – Fernand Widal, Paris, France

ABSTRACT

Background: Aesthetic appearance and brain protection are the main indications for cranial reconstruction following decompressive craniectomy. Recently, few reports indicated that cranioplasty could also improve both, cognitive and functional status. **Materials and Methods:** A group of 20 patients were treated with decompressive craniectomy following closed head injury; among these patients, two of them (who represent the subject of the current investigation) had to undergo subsequent cranioplasty removal due to the development of local infection. All patients were evaluated by Glasgow outcome scale, frontal assessment battery and mini-mental state examination at 1 week before completion of the cranioplasty as well as 6 and 24 weeks following cranioplasty. Perfusion computed tomography scans were also performed (1 week before and 6 weeks after cranioplasty) as well as a trans-cranial Doppler 1 week before, and 6 and 24 weeks after. The two patients being the subject of this study were also clinically and radiologically evaluated after cranioplasty removal. **Results:** These two patients, who represent (not intentionally) two case control, showed a real clinical and cerebral perfusion improvement following repair of the skull defect followed by obvious clinical worsening after the skull flap had to be removed. **Conclusion:** Cranioplasty is likely not to have just a positive influence on cosmetic and protective features of the patients but also seem to improve both, cognitive and functional status by favorably influencing local and global brain hemodynamic and perfusion.

Key words: Brain perfusion, cranioplasty, head injury, outcome of cranial reconstruction

INTRODUCTION

Currently, recommendations for cranioplasty following decompressive craniectomy include brain protection and cosmetic reasons.^[1-5]

Recently, however, some studies indicated that cranioplasty may improve patients functional and cognitive status due to a possible positive influence on brain hemodynamic and perfusion.^[1-3,6-16]

Because of the protective and stabilizing effects of a rigid skull, it seems logical to think that once a skull defect

develops, the local and global brain hemodynamic and perfusion might be negatively influenced. In this study, the authors describe two patients showing a clear clinical improvement following skull defect repair as well as a clear clinical deterioration after cranioplasty removal due to infectious complications.

MATERIALS AND METHODS

This report describes two patients, selected in a group of 20 patients who suffered closed head injury and subsequently underwent decompressive craniectomy followed later on by cranioplasty. These two patients had to undergo synthetic flap removal due to infectious complications.

All patients were studied by brain perfusion computed tomography (CT) scan 1 week before and 6 weeks after cranioplasty as well as by trans-cranial Doppler which was performed also 24 weeks afterwards. Clinical, functional and cognitive status was assessed by Glasgow outcome

Access this article online	
Quick Response Code:	Website: www.ijns.in
	DOI: 10.4103/2277-9167.118124

Address for correspondence: Dr. Salvatore Chibbaro, Department of Neurosurgery, Strasbourg Hautepierre University Hospital, 1, Av Moliere, 67100 Strasbourg, France. E-mail: schibbaro@hotmail.com

scale, frontal assessment battery and mini-mental state examination 1 week before, and 6 and 24 weeks after cranioplasty. The two patients being the subject of this report were also clinically and radiologically evaluated after cranioplasty removal.

RESULTS

A global clinical improvement was recorded in these two patients following repair of the skull defect. However, these two patients had to undergo later on (at 8 and 10 weeks, respectively) to removal of the bone flap because of local infection resistant to antibiotics. Within 3 and 5 days, respectively, following removal of the flap it was noted that both patients developed a noticeable clinical deterioration; in addition we found very interesting that their cerebral perfusion (that improved after flap replacement), deteriorated following flap removal. Clinical outcome and investigations of these two patients are summarized in Tables 1-3.

DISCUSSION

Patients with severe traumatic brain injury often need decompressive craniectomy to treat raised Intracranial pressure (ICP) not responsive to common medical management (i.e., raising of the head of the bed, osmotic diuretics, etc.). Current indications for replacement of the bone flap remain brain protection and cosmetic reasons.^[1,2,4,5]

Recently, many studies have documented that cranioplasty seems to bear a positive influence on cerebral hemodynamic and metabolism; other studies have shown that early cranioplasty would limit complications as hydrocephaly and epilepsy and improve neurological outcome allowing faster recovery.^[1-6,11,13,14,16] We feel that the relevance of our report is based on the fact that the two cases that involuntarily represent two case control; as mentioned, these two patients requiring removal of the flap due to antibiotic resistant infection had enjoyed clinical and neurological improvement following bone flap replacement and suffered noticeable deterioration following the removal [see also Tables 1-3 as well as Figures 1-3]. This view coincides with Yamaura,^[4] who in 1977, reported that 30% of patients with depressed scalp flap (due to lack of a piece of the skull) causing obvious brain indentation improved after cranioplasty. Similar results have been widely described in literature. Sakamoto *et al.*^[10] studied the syndrome of the sinking flap (SSSF), described as one of the causes of new neurological worsening after a large craniectomy, using dynamic xenon CT scan to evaluate cerebral blood flow (CBF). Although, the mechanism of SSSF remains still speculative, they felt it to be the results of the combined effects of atmospheric pressure, cerebrospinal fluid, and CBF changes.^[17] The study of Sakamoto showed clear improvement of CBF in the SSSF following defect repair. Additionally and although, the physiopathology is still not fully understood, there

Table 1: Cerebral perfusion outcome by computed tomography of the two patients in the affected hemisphere

	Patient 1		Patient 2	
	CBV ml/100 mg	CBF ml/100 mg/min	CBV ml/100 mg	CBF ml/100 mg/min
Frontal				
Pre-cranioplasty	5.55	69	4.65	62
Post-cranioplasty	6.23	75.23	6.75	71.11
Post-cranioplasty ablation	5.63	68	4.68	61
Parietal				
Pre-cranioplasty	6.79	59.27	5.99	59.27
Post-cranioplasty	7.21	68.01	6.51	65.01
Post-cranioplasty ablation	6.85	60.2	6.12	61.2
Occipital				
Pre-cranioplasty	6.27	55.87	5.17	59.81
Post-cranioplasty	7.01	75.21	6.95	71.12
Post-cranioplasty ablation	6.02	63.40	5.10	61.45
Temporal				
Pre-cranioplasty	2.90	31.89	4.95	45.08
Post-cranioplasty	2.87	34.59	6.21	48.79
Post-cranioplasty ablation	2.81	32.01	4.67	45.05
BG				
Pre-cranioplasty	5.07	56.08	4.89	55.21
Post-cranioplasty	5.01	55.85	4.72	54.75
Post-cranioplasty ablation	5.03	55.99	4.93	55.32

CBV – Cerebral blood volume; CBF – Cerebral blood flow; BG – Basal ganglia

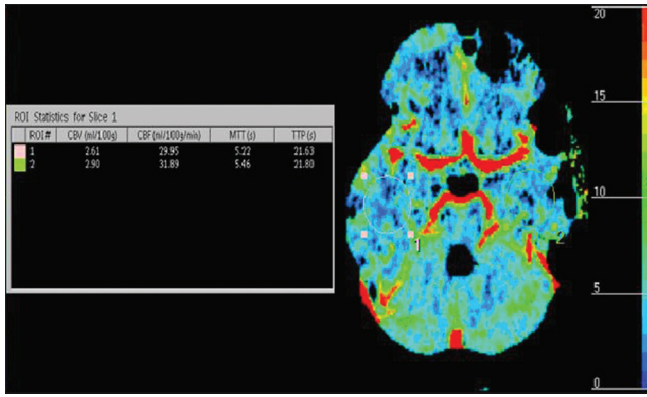


Figure 1: (Patient 1) Brain computed tomography perfusion scan of right and left temporal area before left cranioplasty

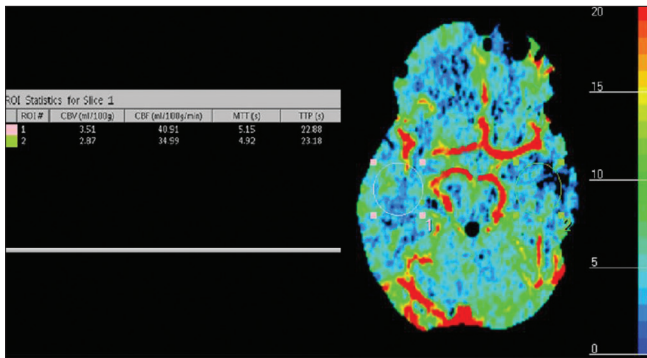


Figure 2: (Patient 1) Brain computed tomography perfusion scan of right and left temporal area after left cranioplasty showing a clear global perfusion improvement in the affected hemisphere as well as in the opposite side comparing to prior skull reconstruction

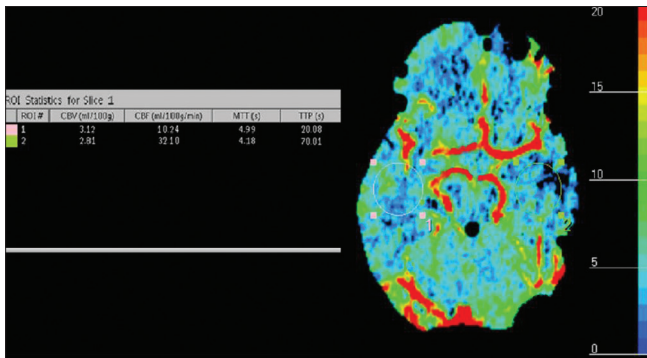


Figure 3: (Patient 1) Brain computed tomography perfusion scan of right and left temporal area after left cranioplasty removal showing a clear global brain perfusion deterioration in the affected hemisphere as well as in the opposite side

is general acceptance that cranial reconstruction is useful for not only cerebral protection but also for improving the functional and neuro-cognitive outcomes.^[18] These clinical data are supported by animal models as reported by Schaller *et al.*,^[15] in fact, after performing a hemicraniectomy in rats Schaller found a clear reduction of cerebral metabolism of normal brain tissue. In addition, it was also highlighted the higher

Table 2: Trans-cranial Doppler parameters/results

Patient 1 (left cranioplasty)

Monitoring of vital constants			
Pre-cranioplasty	MBP=120 mmHg		HR=86 B/M
Post-cranioplasty	MBP=100 mmHg		HR=80 B/M
Post-cranioplasty ablation	MBP=90 mmHg		HR=78 B/M
R-MCA (cm/s)			
Pre-cranioplasty	S60	D30	Ip: 1.33
Post-cranioplasty	S70	D35	Ip: 1.34
Post-cranioplasty ablation	S85	D50	Ip: 1.30
L-MCA (cm/s)			
Pre-cranioplasty	S55	D15	Ip: 1.27
Post-cranioplasty	S70	D20	Ip: 1.55
Post-cranioplasty ablation	S58	D22	Ip: 1.35
R-ICA (cm/s)			
Pre-cranioplasty	S60	D20	Ip: 1.5
Post-cranioplasty	S80	D50	Ip: 1.23
Post-cranioplasty ablation	S60	D30	Ip: 1.3
L-ICA (cm/s)			
Pre-cranioplasty	S70	D30	Ip: 1.4
Post-cranioplasty	S90	D10	Ip: 1.5
Post-cranioplasty ablation	S78	D38	Ip: 1.3

Patient 2 (left cranioplasty)

Monitoring of vital constants			
Pre-cranioplasty	MBP=95 mmHg		HR=82 B/M
Post-cranioplasty	MBP=80 mmHg		HR=69 B/M
Post-cranioplasty ablation	MBP=120 mmHg		HR=80 B/M
R-MCA (cm/s)			
Pre-cranioplasty	S80	D45	Ip: 1.28
Post-cranioplasty	S100	D45	Ip: 1.37
Post-cranioplasty ablation	S60	D30	Ip: 1.33
L-MCA (cm/s)			
Pre-cranioplasty	S50	D20	Ip: 1.42
Post-cranioplasty	S70	D45	Ip: 1.33
Post-cranioplasty ablation	S50	D15	Ip: 1.25
R-ICA (cm/s)			
Pre-cranioplasty	S60	D30	Ip: 1.3
Post-cranioplasty	S60	D30	Ip: 1.33
Post-cranioplasty ablation	S60	D35	Ip: 1.38
L-ICA (cm/s)			
Pre-cranioplasty	S70	D40	Ip: 1.27
Post-cranioplasty	S100	D45	Ip: 1.37
Post-cranioplasty ablation	S50	D20	Ip: 1.42

R-MCA – Right middle cerebral artery; L-MCA – Left middle cerebral artery; R-ICA – Right internal carotid artery; L-ICA – Left internal carotid artery; HR – Heart rate; MBP – Mean blood pressure; S – Systolic; D – Diastolic

susceptibility of oxygen metabolism to perfusional disturbances by documenting the reduction of cerebral metabolic rate of oxygen (CMRO) to be larger than that of cerebral metabolic rate (CMR). Another very relevant feature to be considered is that the extracranial internal carotid artery flow is a global parameter of the brain perfusion; on the other hand, the middle cerebral artery (MCA) flow is representative of a large yet distinct cortical area. This means that MCA flow

Table 3: Clinical outcome

	Patient 1	Patient 2
GOS	Pre-cranioplasty 4/5 Post-cranioplasty 5/5 Post-removal 5/5	Pre-cranioplasty 3/5 Post-cranioplasty 4/5 Post-removal 3/5
MMSE	Pre-cranioplasty 23/30 Post-cranioplasty 30/30 Post-removal 25/30	Pre-cranioplasty 19/30 Post-cranioplasty 23/30 Post-removal 22/30
FAB	Pre-cranioplasty 16/18 Post-cranioplasty 18/18 Post-removal 16/18	Pre-cranioplasty 12/18 Post-cranioplasty 14/18 Post-removal 14/18
Symptoms and signs	Pre-cranioplasty: Dysphasia	Pre-cranioplasty: Severe dysphasia and R dense hemiparesis
	Post-cranioplasty: Normal	Post-cranioplasty: Dysphasia, able to walk and cope independently
	Post-removal: Light dysphasia	Post-removal: Severe dysphasia and R dense hemiparesis

GOS – Glasgow outcome scale; FAB – Frontal assessment battery;
MMSE – Mini-mental state examination

changes are markedly influenced by the location of the skull defect. Because of this, we speculate that patients who still retain auto-regulation of CBF also retain, following cranioplasty, of re-establishing a normal local and global brain hemodynamic and perfusion. Data of the present study showed how cranial reconstruction after decompressive craniectomy might improve local and global cerebral perfusion and clinical and neuro-cognitive status; this concept is also supported by the fact that removal of the flap worsened all the measurement parameters. It seems rather evident that cranioplasty, in these two patients, not only re-established brain protection but also was associated with a significant functional and hemodynamic recovery; on the other hand, these two patients, showed a deterioration of clinical, cognitive and brain perfusion parameters as soon as the bone flap was removed again.

CONCLUSION

The current report suggests that cranioplasty following traumatic head injury may improve the clinical status by ameliorating brain hemodynamic and perfusion; this is pointed by the fact that the two patients who had to have the flap removed immediately regressed. At this point, because of the small number of patients in the study further multi-center and larger trials are required to support our hypothesis.

REFERENCES

- Chibbaro S, Tacconi L. Role of decompressive craniectomy in the management of severe head injury with refractory cerebral edema and intractable intracranial pressure. Our experience with 48 cases. *Surg Neurol* 2007;68:632-8.
- Boström S, Bobinski L, Zsigmond P, Theodorsson A. Improved brain protection at decompressive craniectomy: A new method using Palacos R-40 (methylmethacrylate). *Acta Neurochir (Wien)* 2005;147:279-81.
- Dujovny M, Aviles A, Agner C, Fernandez P, Charbel FT. Cranioplasty: Cosmetic or therapeutic? *Surg Neurol* 1997;47:238-41.
- Yamura A, Makino H. Neurological deficits in the presence of the sinking skin flap following decompressive craniectomy. *Neurol Med Chir (Tokyo)* 1977;17:43-53.
- Fodstad H, Love JA, Ekstedt J, Fridén H, Liliequist B. Effect of cranioplasty on cerebrospinal fluid hydrodynamics in patients with the syndrome of the trephined. *Acta Neurochir (Wien)* 1984;70:21-30.
- Chibbaro S, Fricia M, Vallee F, Beccaria K, Poczos P, Mateo J, et al. The impact of early cranioplasty on cerebral blood flow and metabolism and its correlation with neurological and cognitive outcome: Prospective multi-center study on 34 patients. *Indian J Neurosurg* 2012;1:17-22.
- Britt RH, Hamilton RD. Large decompressive craniotomy in the treatment of acute subdural hematoma. *Neurosurgery* 1978;2:195-200.
- Clifton GL, Jiang JY, Lyeth BG, Jenkins LW, Hamm RJ, Hayes RL. Marked protection by moderate hypothermia after experimental traumatic brain injury. *J Cereb Blood Flow Metab* 1991;11:114-21.
- DeWitt DS, Jenkins LW, Prough DS. Enhanced vulnerability to secondary ischemic insults after experimental traumatic brain injury. *New Horiz* 1995;3:376-83.
- Sakamoto S, Eguchi K, Kiura Y, Arita K, Kurisu K. CT perfusion imaging in the syndrome of the sinking skin flap before and after cranioplasty. *Clin Neurol Neurosurg* 2006;108:583-5.
- Segal DH, Oppenheim JS, Murovic JA. Neurological recovery after cranioplasty. *Neurosurgery* 1994;34:729-31.
- Stula D. The problem of the "sinking skin-flap syndrome" in cranioplasty. *J Maxillofac Surg* 1982;10:142-5.
- Suzuki N, Suzuki S, Iwabuchi T. Neurological improvement after cranioplasty. Analysis by dynamic CT scan. *Acta Neurochir (Wien)* 1993;122:49-53.
- Yamura A, Sato M, Meguro K, Nakamura T, Uemura K. Cranioplasty following decompressive craniectomy – Analysis of 300 cases (author's transl). *No Shinkei Geka* 1977;5:345-53.
- Schaller B, Graf R, Sanada Y, Rosner G, Wienhard K, Heiss WD. Hemodynamic and metabolic effects of decompressive hemicraniectomy in normal brain. An experimental PET-study in cats. *Brain Res* 2003;982:31-7.
- Chibbaro S, Di Rocco F, Mirone G, Fricia M, Makiese O, Di Emidio P, et al. Decompressive craniectomy and early cranioplasty for the management of severe head injury: A prospective multicenter study on 147 patients. *World Neurosurg* 2011;75:558-62.
- Fodstad H, Ekstedt J, Fridén H. CSF hydrodynamic studies before and after cranioplasty. *Acta Neurochir Suppl (Wien)* 1979;28:514-8.
- Chibbaro S, Vallee F, Beccaria K, Poczos P, Makiese O, Fricia M, et al. The impact of early cranioplasty on cerebral blood flow and its correlation with neurological and cognitive outcome. Prospective multi-centre study on 24 patients. *Rev Neurol (Paris)* 2012;Doi: pii: S0035-3787 (12) 00936-8.10.1016/j.neurol. 2012.06.016. [Epub ahead of print] French.

How to cite this article: Chibbaro S, Marsella M, Tigan L, Vicaut E, George B, Guichard J, et al. The therapeutic effect of cranioplasty in severe head injuries: Report of two cases. *Indian J Neurosurg* 2013;2:189-92.

Source of Support: Nil, **Conflict of Interest:** None declared.