

A rare case report of cerebral phaeohyphomycosis mimicking glioma in a patient of rheumatic valvular heart disease

Ashish Chugh, Sharada Rane¹, Charandeep Singh Gandhoke², Kulkarni Maithili¹

Departments of Neurosurgery, ¹Pathology and ²Surgery (Neurosurgery Unit), B. J. Medical College and Sassoon General Hospitals, Pune, Maharashtra, India

ABSTRACT

Phaeohyphomycosis is a collective term used for fungal infections caused by moulds and yeasts that have brown pigmented cell walls due to the presence of melanin. These are also known as dematiaceous fungi. We report this patient who presented with headache, right hemiparesis, slurred speech, and altered sensorium. Patient was a known case of rheumatic valvular heart disease (RVHD) and had undergone balloon valvotomy for mitral stenosis 1 year back. Radiological features were suggestive of high grade glioma. Left fronto-parietal decompressive craniectomy with complete excision of mass lesion was performed. Histopathological examination of the surgical specimen revealed multiple granulomas with giant cells. These giant cells contained branched septate pigmented fungal hyphae in their cytoplasm. After the histopathology report, patient was started on intravenous amphotericin and was discharged on oral itraconazole 200 mg twice daily. Unfortunately, the patient was non-compliant and stopped taking oral itraconazole after 1 month. He landed up in fulminant fungal meningo-encephalitis and died 10 weeks after the initial diagnosis. We report a rare case of cerebral phaeohyphomycosis in a patient of RVHD which, to our knowledge, is nowhere mentioned in the literature.

Key words: Cerebral phaeohyphomycosis, fungal infections, rheumatic valvular heart disease

INTRODUCTION

Phaeohyphomycosis is a term first presented in 1974 by Ajello *et al.* to describe cutaneous, subcutaneous and systemic infections caused by dematiaceous septate fungi in the host tissue.^[1] Diseases caused by dematiaceous fungi include sinusitis, cerebral abscess, onychomycosis, tinea nigra, keratitis, mycetoma, chronic meningitis, and rarely pneumonia.^[2] These fungi may affect immuno-compromised as well as immuno-competent hosts. Diagnosis is confirmed on tissue examination and culture results. In spite of better medical care the prognosis still remains poor. We report a rare case of cerebral phaeohyphomycosis in a patient of rheumatic valvular heart disease (RVHD) which, to our knowledge, is nowhere mentioned in the literature.

CASE REPORT

We report a case of a 35-year-old male carpenter who presented with complaints of intermittent holocranial headache since 1 month, weakness in right upper and lower limbs since 3 weeks, which was progressive in nature, slurred speech since 1 week and altered sensorium since 2 days. Patient was a known case of RVHD and had undergone a balloon valvotomy for mitral stenosis 1 year ago. On examination, he was conscious, but drowsy. He could localize pain and had grade 2/5 power in right upper and lower limbs. On fundoscopic examination, he had bilateral papilledema. He was started on intravenous mannitol 100 cc thrice daily, phenytoin 100 mg thrice daily and dexamethasone 6 mg 4 times a day. His blood profile for biochemistry and hematology was within normal limits. His BSL profile was also normal. Tests for human immunodeficiency virus and hepatitis B surface antigen were negative. On chest X-ray Posterior to Anterior (PA) view, there was straightening of the left border of the cardiac silhouette. Pre-operative 2D echocardiogram showed rheumatic affection of the mitral valve, thickened anterior mitral leaflet, and posterior mitral leaflet (PML). PML also showed restrictive mobility. Mitral valve area was 1.9 cm² (Post Balloon

Access this article online	
Quick Response Code:	Website: www.ijns.in
	DOI: 10.4103/2277-9167.118130

Address for correspondence: Dr. Charandeep Singh Gandhoke, Department of Surgery, B. J. Medical College and Sassoon General Hospitals, 9/B, (2nd Floor), Cycle Merchant Society, Rasta Peth, Pune - 411 011, Maharashtra, India. E-mail: charandeepsingh2008@gmail.com

Mitral Valvotomy). Left ventricular systolic function was normal with an ejection fraction of 60%. Left atrium was dilated with no blood clots in the left atrium. There was no pulmonary hypertension. After his renal function tests were reported to be normal magnetic resonance imaging (MRI) scan of brain (plain and with contrast) was done. MRI scan showed an irregular peripherally enhancing lesion in the left fronto-parietal region of the brain with mass effect and midline shift. Satellite lesions were also seen [Figure 1]. These features were suggestive of glioblastoma mutiforme (high grade glioma). Patient was taken up for left fronto-parietal decompressive craniectomy and complete excision of the mass lesion was performed. Intra-operatively the mass was observed to be well-encapsulated, firm in consistency, could not be easily sucked and had necrotic areas within. The surrounding brain was edematous. There was no significant improvement in his sensorium in the immediate post-operative period. Post-operative computerized tomography (CT) scan of brain (plain and with contrast) showed complete removal of the lesion with persistent cerebral edema [Figure 1]. On third post-operative day, the histopathological report received was suggestive of cerebral phaeohyphomycosis [Figure 2 gross surgical specimen of excised fungal mass]. On H and E staining multiple granulomas with giant cells were seen. The giant cells had pigmented fungi in their cytoplasm [Figure 2]. Large areas of necrosis were also seen mimicking glioblastoma multi-forme. On Gomori

Silver Methenamine staining branched septate hyphae were seen in the giant cell cytoplasm [Figure 3]. On Masson's Fontana staining black colored fungal hyphae were seen in the giant cells [Figure 3]. The tissue had not been sent for fungal culture since malignancy was suspected in this patient. After the histopathology report, the patient was started on intravenous amphotericin B (1 mg/kg body weight/day) empirically. Patient showed improvement after starting anti-fungal treatment and power in right upper and lower limbs also improved to grade 4/5. After completing intravenous amphotericin B treatment for 2 weeks, the patient was discharged on oral itraconazole 200 mg twice daily. However, the patient was non-compliant and stopped taking itraconazole after 1 month following which he landed up in fulminant meningo-encephalitis with hydrocephalus. He was started on intravenous amphotericin B and flucytosine and external ventricular drainage insertion was performed (to reduce the intra-cranial pressure). The patient did not respond to the anti-fungal therapy and died 10 weeks after the initial diagnosis.

DISCUSSION

The term “phaeohyphomycosis” is used to describe fungal infections characterized by development of dark pigmented filamentous hyphae in the involved tissue. Dark color is due to the presence of melanin pigment in the cell wall, which helps in evading host defenses.^[3]

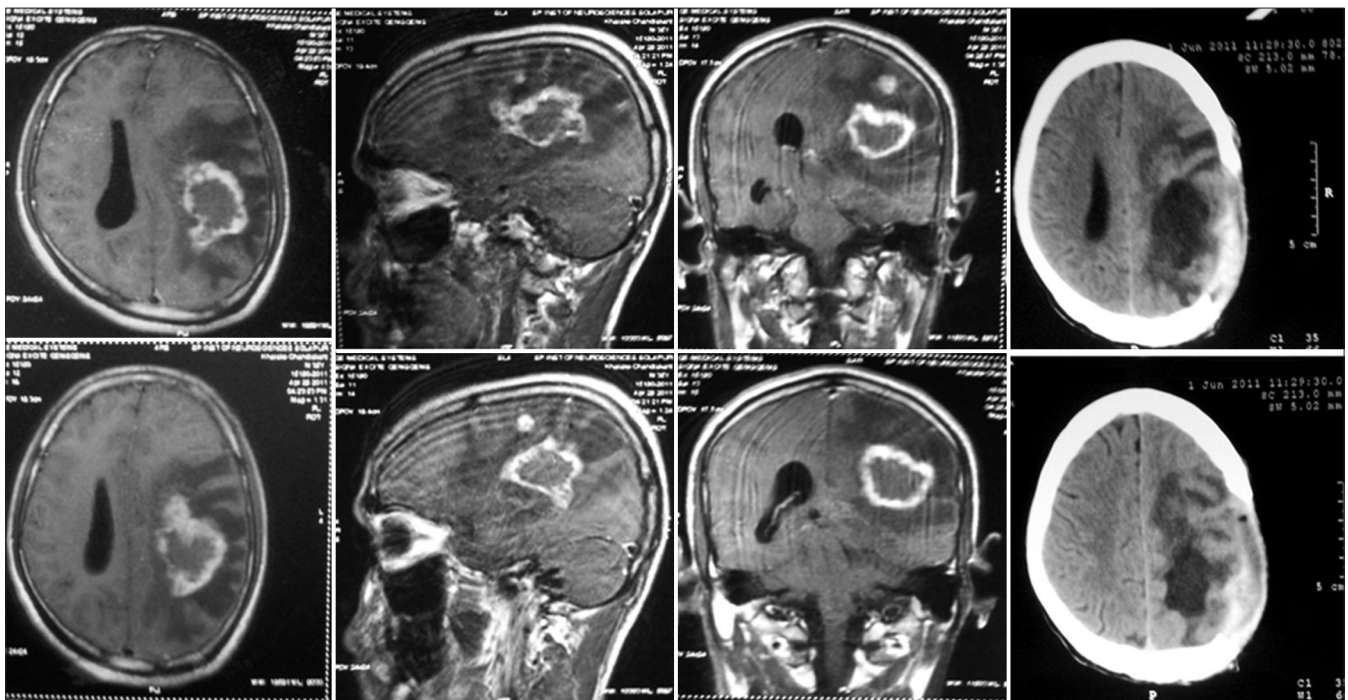


Figure 1: Magnetic resonance imaging scan showing irregular peripherally enhancing lesion in the left fronto-parietal region with mass effect and midline shift. Satellite lesions are also seen. Post-operative computerized tomography scan (plain + contrast) showing complete excision of the tumor

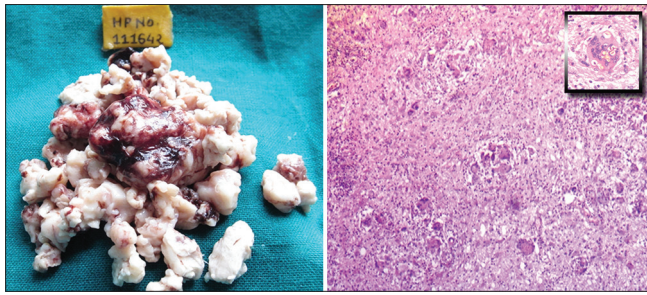


Figure 2: Gross surgical specimen showing multiple pieces with necrosis. H and E stain showing multiple granulomas with many giant cells which are showing pigmented fungi within (inset)

Melanin acts as a buffer against host oxidation killing mechanisms. Cerebral phaeohyphomycosis is rare and is associated with a high degree of morbidity and mortality.

Cladophialophora bantiana accounts for the majority of the cases until the date. Other agents responsible are *exophiala dermatitidis*, *ramichloridium mackenziei*, *ochroconis gallopavus*, *fonsecaea pedrosoi*, *fonsecaea monophora*, *chaetomium atrobrunnm*, *chaetomium strumirium*, *chaetomium perlucidum*, *bipolaris spicifera* and also other rare species. These organisms are frequently thermophilic growing at 40°C or higher temperatures.^[4] Portal of entry is not well-established, though inhalation of spores into the lungs and subsequent colonization and hematogenous spread is the widely accepted mode.^[5] Multiplicity of lesions is also suggestive of hematogenous route of spread. Trauma is also implicated with implantation of fungal elements in the skin resulting in cutaneous and subcutaneous infection, which may subsequently disseminate.^[5] Contiguous spread from paranasal sinuses can also occur.

As these fungi are saprophytes, they can be isolated from soil, wood, decaying vegetation, and seed warehouses. In this mentioned case, the patient was a carpenter by profession.

Patient was also a known case of RVHD. RVHD mainly involves the mitral and the aortic valves. These damaged valves are at risk of bacterial attachment and infective endocarditis. This may lead to septic thromboembolism, mycotic aneurysms, meningitis, meningo-encephalitis, and rarely brain abscess.

The characteristic imaging pattern seen on CT/MRI scan is that of an irregular conglomerate mass with variable enhancing pattern and significant peri-lesional edema.^[5] In the mentioned case, the lesion resembled a high grade glioma in the MRI scan of brain (plain and with contrast).

Microscopic examination of the tissue is an important aspect.^[5] Direct smear cytology of tissue is helpful in

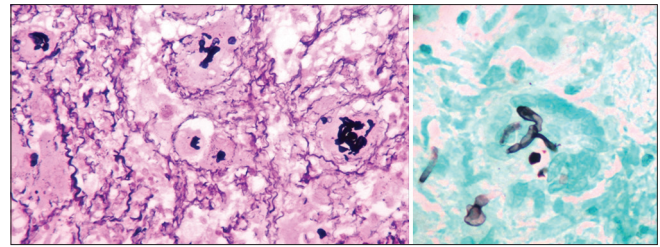


Figure 3: Black colored fungal hyphae in giant cell cytoplasm (Masson's Fontana Stain, x400). Branched septate hyphae in giant cell cytoplasm (Silver Methenamine, x1000)

giving a clue to fungal hyphae. Isolation of fungus from tissue demands proper collection of specimen with careful transportation to the laboratory. Tissue is to be cultured on slopes of Sabouraud's dextrose agar media incubated at room temperature.

Treatment of cerebral phaeohyphomycosis must be individualized with surgical resection and optimal anti-fungal therapy. Surgical options include stereotactic biopsy,^[6] tapping of the abscess and excision. Excision of the abscess reduces the disease load and may also improve response to anti-fungal treatment.^[3,7,8] Commonly used anti-fungal drugs are amphotericin B, flucytosine, itraconazole, and newer drugs such as voriconazole and posaconazole. Most commonly used therapy is amphotericin B along with 5-flucytosine.^[3,7-10] Relapses after therapy with amphotericin B have been successfully treated with oral itraconazole. Duration of anti-fungal treatment must be individualized using radiological evidence of resolution. Yet prognosis of patients with cerebral phaeohyphomycosis is poor and only few patients survive for more than 1 year.

CONCLUSION

This rare case report of cerebral phaeohyphomycosis in a patient of RVHD, to our knowledge is nowhere mentioned in the literature. This case underscores the difficulty of diagnosing and adequately treating cerebral phaeohyphomycosis. The feasibility of surgical resection should be considered in all patients of cerebral phaeohyphomycosis and duration of anti-fungal treatment must be individualized using radiological evidence of resolution.

REFERENCES

1. Ajello L, Georg LK, Steigbigel RT, Wang CJ. A case of phaeohyphomycosis caused by a new species of *Phialophora*. *Mycologia* 1974;66:490-8.
2. Osiyemi OO, Dowdy LM, Mallon SM, Cleary T. Cerebral phaeohyphomycosis due to a novel species: Report of a case and review of the literature. *Transplantation* 2001;71:1343-6.
3. Jacobson ES. Pathogenic roles for fungal melanins. *Clin Microbiol Rev* 2000;13:708-17.

4. Sutton DA, Slifkin M, Yakulis R, Rinaldi MG. U.S. case report of cerebral phaeohyphomycosis caused by *Ramichloridium obovoideum* (*R. mackenziei*): Criteria for identification, therapy, and review of other known dematiaceous neurotropic taxa. *J Clin Microbiol* 1998;36:708-15.
5. Rajput DK, Mehrotra A, Srivastav AK, Kumar R, Rao R. Cerebral phaeohyphomycosis mimicking glioma. *Pan Arab J Neurosurg* 2011;15:87-90.
6. Raut A, Muzumdar D, Narlawar R, Nagar A, Ahmed N, Hira P. Cerebral abscess caused by *Cladosporium bantianum* infection – Case report. *Neurol Med Chir (Tokyo)* 2003;43:413-5.
7. Revankar SG, Sutton DA, Rinaldi MG. Primary central nervous system phaeohyphomycosis: A review of 101 cases. *Clin Infect Dis* 2004;38:206-16.
8. Garg N, Devi IB, Vajramani GV, Nagarathna S, Sampath S, Chandramouli BA, *et al.* Central nervous system cladosporiosis: An account of ten culture-proven cases. *Neurol India* 2007;55:282-8.
9. Hiruma M, Kawada A, Ohata H, Ohnishi Y, Takahashi H, Yamazaki M, *et al.* Systemic phaeohyphomycosis caused by *Exophiala dermatitidis*. *Mycoses* 1993;36:1-7.
10. Kwon-Chung KJ, Bennett JE, editors. *Phaeohyphomycosis*. In: *Medical Mycology*. Philadelphia. Lea and Febiger; 1992. p. 620-77.

How to cite this article: Chugh A, Rane S, Gandhoke CS, Maithili K. A rare case report of cerebral phaeohyphomycosis mimicking glioma in a patient of rheumatic valvular heart disease. *Indian J Neurosurg* 2013;2:199-202.

Source of Support: Nil, **Conflict of Interest:** None declared.

New features on the journal's website

Optimized content for mobile and hand-held devices

HTML pages have been optimized of mobile and other hand-held devices (such as iPad, Kindle, iPod) for faster browsing speed.

Click on **[Mobile Full text]** from Table of Contents page.

This is simple HTML version for faster download on mobiles (if viewed on desktop, it will be automatically redirected to full HTML version)

E-Pub for hand-held devices

EPUB is an open e-book standard recommended by The International Digital Publishing Forum which is designed for reflowable content i.e. the text display can be optimized for a particular display device.

Click on **[EPub]** from Table of Contents page.

There are various e-Pub readers such as for Windows: Digital Editions, OS X: Calibre/Bookworm, iPhone/iPod Touch/iPad: Stanza, and Linux: Calibre/Bookworm.

E-Book for desktop

One can also see the entire issue as printed here in a 'flip book' version on desktops.

Links are available from Current Issue as well as Archives pages.

Click on  View as eBook