

# A rare case report of aneurysmal bone cyst involving the roof of the orbit

Charandeep Singh Gandhoke, Chugh Ashish<sup>1</sup>, Chaudhari Priyanka<sup>2</sup>, Gandhi Bhooshan<sup>3</sup>

Departments of Surgery, <sup>1</sup>(Neurosurgery Unit) and <sup>2</sup>Pathology, <sup>3</sup>B.J. Medical College and Sassoon General Hospitals, Pune, Maharashtra, India

## ABSTRACT

Aneurysmal bone cyst (ABC) is a benign, tumor like, multi-cystic vascular lesion that causes destruction of the cortical bone. It usually involves the metaphysis of long bones and spine (posterior elements). ABC arising in the orbit constitutes less than 0.25% of all reported cases. We report a 5-year-old girl who presented with painless right sided proptosis without any visual disturbance, which was gradual in onset. Contrast enhanced computed tomography and magnetic resonance imaging scans of the orbit were suggestive of an expansile bony lytic lesion in the roof of the right orbit. Frontal craniotomy followed by the supra-orbital osteotomy was carried out. The entire tumor-like mass was removed piece-meal. Histopathological diagnosis was "a solid variant of ABC of the orbital roof." Post-operative course was satisfactory and the patients eye symptoms improved.

**Key words:** Aneurysmal bone cyst, craniotomy, orbit, supra-orbital osteotomy

## INTRODUCTION

Aneurysmal bone cyst (ABC) is an expansile multi-cystic vascular lesion of the bone that most often affects individuals during their second decade of life. In 1942, Jaffe and Lichtenstein first described the term ABC as "peculiar blood-containing cysts of large size."<sup>[1]</sup> About 50% of ABCs occur in the metaphysis of a long bone. Another 20% of ABCs occur in the spine (posterior elements).<sup>[2]</sup> ABC may involve the flat bones of the body. Pelvis accounts for approximately 50% of the lesions occurring in the flat bones. ABCs are rarely seen in the cranium; of which the cranial vault is the most common site. World-wide only 25 cases of orbital ABC have been reported.<sup>[1-8]</sup> We describe a rare case of ABC involving the orbital roof in a 5-year-old girl, which was treated by total excision.

## CASE REPORT

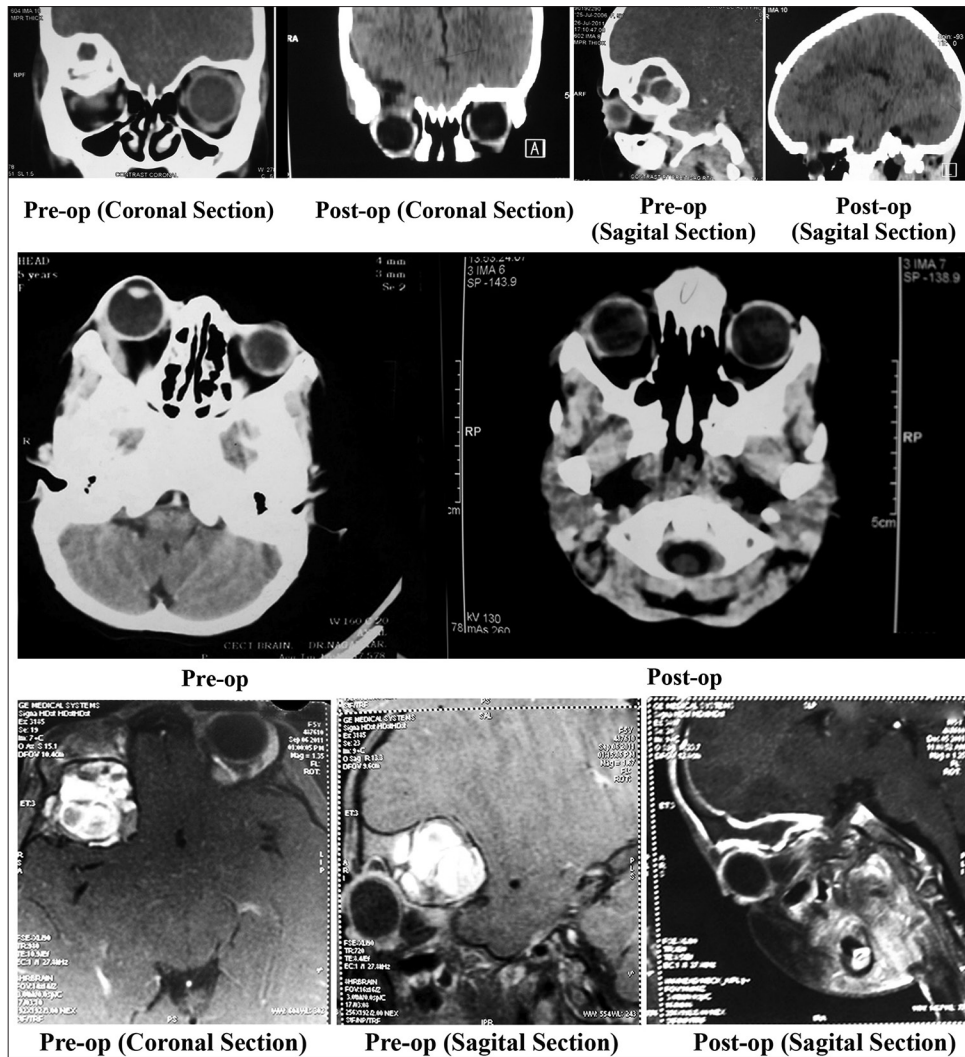
We report a 5-year-old female child who presented with 6 months history of painless, progressive right sided

peri-orbital swelling of gradual onset and proptosis, but without symptoms of visual disturbance. There was no limitation of eye movements. There was no relevant past history such as head injury. Visual acuity was normal in both eyes. Her blood profile for biochemistry and hematology was within the normal limits. Computed tomography (CT) scan of orbit (plain and with contrast) [Figure 1] and magnetic resonance imaging (MRI) scan of orbit (plain and with contrast) [Figure 1] were carried out. Findings were suggestive of a bony expansile multi-cystic lytic lesion in the roof of the right orbit of 35 mm × 30 mm × 32 mm in size. The bony expansion extended posteriorly up to the right anterior clinoid process. Superiorly the lesion indented on the right frontal lobe. Inferiorly it extended into the right orbital space with resultant mass effect and proptosis. Extra-ocular muscles were distorted by the lesion. Right optic nerve was displaced medially. The lesion showed multiple fluid-fluid levels with variable T1 and T2 weighted signal intensities representing areas of blood within the cysts, of variable age. The cyst wall enhanced strongly after injection of contrast.

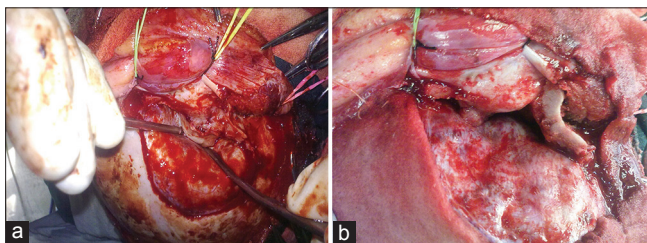
Surgical access to the tumor was carried out using a frontal craniotomy followed by supra-orbital osteotomy [Figure 2]. The dura of the frontal base was detached off the remnants of the orbital roof, the latter being almost completely destroyed and replaced by the tumor itself. The mass was entirely extra-dural in nature and was highly vascular. It was removed piece-meal [Figure 3].

Access this article online	
Quick Response Code:	Website: www.ijns.in
	DOI: 10.4103/2277-9167.118132

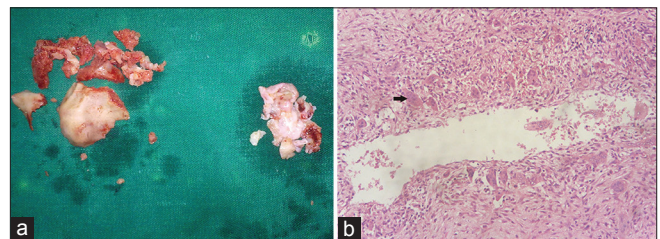
**Address for correspondence:** Dr. Charandeep Singh Gandhoke, Department of Surgery, B.J. Medical College and Sassoon General Hospitals, 9/B, Cycle Merchant Society, Rasta Peth, Pune - 411 011, Maharashtra, India. E-mail: charandeepsingh2008@gmail.com



**Figure 1:** Pre-operative computed tomography (CT) scan image shows an expansile multi-cystic lytic lesion in the roof of right orbit. Post-operative CT scan image shows complete excision of the lesion (coronal sections) (sagittal sections). Post-operative magnetic resonance imaging image showing complete excision of the lesion. Post-operative computed tomography image shows complete resolution of proptosis



**Figure 2:** (a) Frontal craniotomy with supra-orbital osteotomy done. Excision of aneurysmal bone cyst in process. (b) Intra-operative photograph showing complete excision of the lesion



**Figure 3:** (a) Gross specimen of aneurysmal bone cyst, (b) Microscopic picture of aneurysmal bone cyst, which on H and E, shows many osteoclast giant cells (arrow) along with blood containing cysts and spindle cells

The superior orbital margin was thinned out and was reconstructed with Codman™ cranioplastic bone cement.

Post-operatively the patient was given intravenous antibiotics for 5 days and was discharged on the fifth post-operative day. Histopathology report was suggestive of a solid variant of ABC of the orbital roof. The tumor

was composed of spindle cells with blood containing cysts, numerous osteoclast giant cells, and reactive new bone confirming the diagnosis of ABC [Figure 3]. Post-operative CT scan and MRI scan [Figure 1] showed complete excision of the mass lesion. Post-operative CT scan showed complete resolution of proptosis [Figure 1]. There was no recurrence of the ABC at 1 year follow-up of the child.

## DISCUSSION

World Health Organization defines ABC as a benign tumor-like lesion. It is described as “an expanding osteolytic multi-cystic eccentric lesion consisting of blood filled spaces of variable size separated by connective tissue septae containing trabecula or osteoid tissue and osteoclast giant cells.” Mean age of presentation of ABC is 13-17.7 years. There is a slight female preponderance. ABC may arise de novo (primary) or secondary to another bony lesion (secondary). The bony lesions associated with secondary ABCs are giant cell tumors, fibrous dysplasia, osteoblastoma, chondromyxoid fibroma, non-ossifying fibroma, chondroblastoma, osteosarcoma, chondrosarcoma, unicameral or solitary bone cyst, hemangioendothelioma, and metastatic carcinoma.<sup>[9]</sup>

The differential diagnosis for ABC includes simple (solitary/unicameral) bone cyst, giant cell tumor (osteoclastoma), osteoblastoma, telangiectatic osteosarcoma, and monostotic fibrous dysplasia. Simple bone cyst is a slightly expansile, centric lesion without cortical breach, which differentiates it from an ABC.

Various hypothesis have been put forth to explain the etiology of ABC. Some authors have postulated that local circulatory disturbance in the bone such as thrombosis or arteriovenous malformation leads to dilated vascular bed in the affected area.<sup>[10]</sup> This causes increased pressure, expansion, erosion, and resorption of the surrounding bone, which leads to formation of ABC. Others have proposed that post-traumatic ABC could be a manifestation of occluded venous drainage of the affected part of the bone with subsequent distension and expansion.<sup>[10]</sup>

For diagnosis of ABC, imaging studies are important. On imaging studies ABC appears as an expansile multi-loculated osseous lesion containing fluid-fluid levels. The peripheral capsule and internal septations enhance with contrast.<sup>[11]</sup>

The various modalities available for the treatment of ABC include selective arterial embolization using materials such as foam and springs (selective arterial embolization may be performed before surgery to reduce the amount of blood loss); intralesional injections; CT guided injections of calcitonin and methyl prednisolone; intralesional curettage; intralesional excision; and en bloc or wide excision of the ABC. Simple intralesional curettage is associated with the high recurrence rates of up to 50%.<sup>[10]</sup> Recurrence rates can be reduced by the combining intralesional curettage with adjuvant argon beam coagulation or by using locally applied

adjuvants such as liquid nitrogen, phenol and polymethyl methacrylate. Treatment for a secondary ABC is that, which is appropriate for the underlying lesion.

Total en bloc surgical excision is the treatment of choice for the management of orbital ABC and any remnant lesion can lead to recurrence. The recurrence rate after total excision is about 10%.<sup>[11]</sup> In the cranium and spine, there is an added difficulty of it being often impossible to reach and to excise the lesion completely. This is especially, true if the lesion is located in the skull base, for example, in the roof, the medial and lateral walls of the orbit, the paranasal sinuses and the petrous temporal bone. In these cases, partial excision or intra-lesional curettage with adjunctive therapy such as pre-operative embolization or post-operative radiotherapy or stereotactic radiosurgery should be considered.<sup>[11]</sup>

Recurrence usually occurs within the first 2 years after surgery. However, patients should still be monitored on a regular basis for 5 years after surgery. Children should be monitored until they have reached maturity to ensure that any possible recurrence does not cause deformity or interfere with their growth. Any patients that have received radiation should be monitored for life because of the risk of secondary sarcoma. Review of the literature reveals 2 cases of orbital recurrence following partial excision within 2 years.<sup>[12]</sup> No cases of osteogenic sarcoma complicating radiotherapy have been reported in the orbit, though this has occurred with extra-cranial ABCs.<sup>[12]</sup>

Patients with ABC usually have a good prognosis with an overall cure rate of 90-95%.

## CONCLUSION

World-wide only 25 cases of ABC of the orbit have been reported.<sup>[1-8]</sup> Rarity of the orbital roof ABC and total surgical excision with reconstruction of the superior orbital margin in a single setting prompted us to report this case.

## REFERENCES

1. Yu JW, Kim KU, Kim SJ, Choi S. Aneurysmal bone cyst of the orbit: A case report with literature review. *J Korean Neurosurg Soc* 2012;51:113-6.
2. Hunter JV, Yokoyama C, Moseley IF, Wright JE. Aneurysmal bone cyst of the sphenoid with orbital involvement. *Br J Ophthalmol* 1990;74:505-8.
3. Cakirer S, Cakirer D, Kabukcuoglu F. Aneurysmal bone cyst of the orbit: A case of rare location and review of the literature. *Clin Imaging* 2002;26:386-91.
4. Gan YC, Hockley AD. Aneurysmal bone cysts of the cranium in children. Report of three cases and brief review of the literature. *J Neurosurg* 2007;106:401-6.

5. Marback EF, Neves M, Marback RL. Aneurysmal bone cyst of the orbit-a clinicopathological study: Case report. *Arq Bras Oftalmol* 2008;71:868-70.
6. Marcol W, Manderá M, Malinowska I, Pajak J, Właszczuk P, Kluczevska E. Aneurysmal bone cyst of the orbit. *Pediatr Neurosurg* 2006;42:325-7.
7. Senol U, Karaali K, Akyüz M, Gelen T, Tuncer R, Lüleci E. Aneurysmal bone cyst of the orbit. *AJNR Am J Neuroradiol* 2002;23:319-21.
8. Yuen VH, Jordan DR, Jabi M, Agbi C. Aneurysmal bone cyst associated with fibrous dysplasia. *Ophthal Plast Reconstr Surg* 2002;18:471-4.
9. Levy WM, Miller AS, Bonakdarpour A, Aegerter E. Aneurysmal bone cyst secondary to other osseous lesions. Report of 57 cases. *Am J Clin Pathol* 1975;63:1-8.
10. Borkar SA, Kasliwal MK, Sinha S, Sharma BS. MR imaging in aneurysmal bone cyst of the orbit. *Turk Neurosurg* 2008;18:183-6.

**How to cite this article:** Gandhoke CS, Chugh A, Chaudhari P, Gandhi B. A rare case report of aneurysmal bone cyst involving the roof of the orbit. *Indian J Neurosurg* 2013;2:203-6.

**Source of Support:** Nil, **Conflict of Interest:** None declared.

## Staying in touch with the journal

### 1) Table of Contents (TOC) email alert

Receive an email alert containing the TOC when a new complete issue of the journal is made available online. To register for TOC alerts go to [www.ijns.in/signup.asp](http://www.ijns.in/signup.asp).

### 2) RSS feeds

Really Simple Syndication (RSS) helps you to get alerts on new publication right on your desktop without going to the journal's website. You need a software (e.g. RSSReader, Feed Demon, FeedReader, My Yahoo!, NewsGator and NewzCrawler) to get advantage of this tool. RSS feeds can also be read through FireFox or Microsoft Outlook 2007. Once any of these small (and mostly free) software is installed, add [www.ijns.in/rssfeed.asp](http://www.ijns.in/rssfeed.asp) as one of the feeds.