

Large vestibular schwannomas and hydrocephalus: Lessons learnt from a single centre experience

Prakash Nair, Devesh Kumar Singh¹, Rabi Narayan Sahu¹, Raj Kumar², Sanjay Behari¹, Awadesh Kumar Jaiswal¹, Arun Kumar Srivastava

Departments of Neurosurgery, Amrita Institute of Medical Sciences, Kochi, Kerala, ¹Sanjay Gandhi Postgraduate Institute of Medical Sciences, Lucknow, Uttar Pradesh, ²Director, All India Institute of Medical Sciences, Rishikesh, Uttarakhand, India

ABSTRACT

Aim: The aim of the following study is to analyze the outcome following surgery in 169 patients with large vestibular schwannoma (VS) and to evaluate hydrocephalus as a prognostic factor in patients of the VSs. **Subjects and Methods:** Retrospective analysis of all cases of VSs admitted to our tertiary neurosurgical center from January 2005 to December 2010 was performed. Comparison of patients who underwent pre-operative cerebrospinal fluid (CSF) diversion and those who underwent primary surgery was carried out for post-operative complications and delayed hydrocephalus. **Results:** A total of 169 patients of VS were seen. The mean age at presentation was 39.03 years (12-72 years). The most common symptom was hearing loss seen in 161 (95.2%) cases. Giant VS was seen in 130 (75.5%) and hydrocephalus was present in 110 (63.9%). Pre-operative CSF diversion was done in 23 (13.1%) patients; 8 (4.6%) patients developed gradually symptomatic hydrocephalus following surgery and underwent ventriculoperitoneal shunt. Total surgical excision was done in 92.9% patients and subtotal excision was done in 7% patients. **Conclusions:** Hydrocephalus occurs in longstanding untreated cases of VS. Hydrocephalus causes no statistically significant increase in post-operative complications like CSF leak and post-operative hematoma. Patients with hydrocephalus presenting with acute symptoms of raised intracranial pressure benefit from CSF diversion. In most patients, tumor resection will restore patency of the CSF pathway and CSF diversion can be avoided.

Key words: Hydrocephalus, retromastoid craniectomy, ventriculoperitoneal shunt, vestibular schwannoma

INTRODUCTION

Vestibular schwannoma (VS) is the most common neoplasm of the cerebellopontine angle. In India, VS often presents at a later stage when the tumor has attained a very large size and caused extra-audiofacial neurological deficits.^[1-3] With increase in size, VS cause significant brainstem compression and hydrocephalus, which is associated with visual deterioration, ataxia, urinary incontinence and often acute neurological worsening prior to surgery. The presence of hydrocephalus makes surgical excision difficult due to cerebellar swelling and greater intraoperative cerebellar retraction. This has been associated with an increase in postoperative morbidity, especially cerebrospinal fluid (CSF) fistulas.^[4-6] We analyze

the results of surgical treatment in 169 patients with VS with special attention to obstructive hydrocephalus as a factor in determining the outcome following surgery.

SUBJECTS AND METHODS

We performed a retrospective analysis of all cases of VSs admitted to our tertiary neurosurgical center from January 2005 to December 2010. Preoperative assessment of every patient consisted of clinical examination and neuroradiological evaluation by non-contrast computerized tomography (NCCT) or contrast enhanced computerized tomography (CECT), and gadolinium enhanced magnetic resonance imaging (MRI). Clinical information including age, sex, clinical symptoms and signs, duration of symptoms, radiological findings, surgical procedure carried out, extent of surgical excision, post-operative complications, and follow-up was retrieved from their case records, operation theater register and discharge summaries. The histopathology reports of all operated cases were verified before including them in our series. All patients were evaluated pre-operatively by clinical examination of the nervous system. Facial nerve palsy

Access this article online	
Quick Response Code:	Website: www.ijns.in
	DOI: 10.4103/2277-9167.131997

Address for correspondence: Dr. Rabi Narayan Sahu, Department of Neurosurgery, Sanjay Gandhi Postgraduate Institute of Medical Sciences, Lucknow - 226 014, Uttar Pradesh, India. E-mail: drnsahu@gmail.com

was graded pre-operatively and post-operatively by the House-Brackmann grading. Their hearing assessment was carried out using pure tone audiometry (PTA) and graded according to the Norstadt classification i.e. good = 0-30db, fair = 31-60db, bad = 61-90db, lost >90db. The criterion for impairment of useful hearing was a hearing impairment greater than 60 decibels. The speech discrimination test was not performed.

The size of the tumor was measured in the plane parallel to the petrous ridge. Jackler's staging was used to classify the tumors into small (<10 mm), medium (10-24 mm), large (25-39 mm), giant (>40 mm). Hydrocephalus was diagnosed if the ratio of the maximum width of the frontal horns to the maximum internal diameter of the inner table of the skull at the same level was greater than 30%.^[7] The extent of occlusion of the fourth ventricle was categorized as patent if the fourth ventricle was not distorted with the presence of dilated third and lateral ventricles, partially occluded if the fourth ventricle appeared distorted with dilatation of the third and lateral ventricles and completely occluded if the fourth ventricle was completely compressed and the third and lateral ventricles were dilated. The type of hydrocephalus was obstructive if the fourth ventricle was found compressed in the presence of dilated lateral and third ventricles or communicating if the fourth ventricle was dilated along with the lateral and the third ventricle. The surgical resection in all patients was done through the retromastoid approach in the park-bench position, except in one patient who was operated by the middle fossa approach. The Cavitron ultrasonic suction aspirator (CUSA) was used in a few cases. Facial nerve monitoring or brainstem evoked potential monitoring was not used in any case.

In those patients who had bilateral tumors and underwent surgical resection on both sides; the second surgery was recorded as a separate case with respect to tumor size and surgical outcome. The extent of resection was considered total if the entire tumor along with the intracanal extension was resected, near total if bits of the capsule were left behind on the cranial nerves or the brainstem and subtotal if a part of the tumor was left behind following surgery. Post-operative follow-up was obtained through direct out-patient clinic visits at 6 weeks, 3 months, 6 months and 1 year and later by telephonic or postal communication.

Sub group analysis of patients with hydrocephalus for pre-operative clinical presentation, neurological signs, post-operative complications and comparison of patients who underwent pre-operative CSF diversion and those who underwent primary surgery was done for post-operative complications and delayed hydrocephalus.

The data was tabulated and analyzed using SPSS[®] 16 (SPSS Inc., Chicago, IL).

RESULTS

From January 2005 to December 2010, 169 ($n = 169$) patients with a clinical diagnosis of VS were seen in our tertiary care neurosurgical unit, 95 (56.2%) patients were males and 74 (43.7%) were females. The age at presentation ranged from 12 years to 72 years with the mean age at presentation being 39.03 years. 15 patients (8.5%) had bilateral VSs due to neurofibromatosis-2 (NF-2). Two patients were reoperated for residual tumor 6 weeks after primary surgery and two patients were operated for recurrent VS.

Clinical presentation [Table 1]

The most common symptom was hearing impairment due to cochlear nerve involvement, which was seen in 161 (95.2%) patients. 71 patients (42.01%) patients had right and 83 (49.1%) patients had left ear involvement. Bilateral hearing loss was seen in 7 (4.1%) patients and only 4 (2.3%) patients had no subjective hearing loss at presentation. The mean duration of hearing loss at presentation was 20.8 months. Although the hearing loss is a subjective phenomenon, PTA was used pre-operatively for objective assessment of hearing. Good hearing was seen in 1 (0.5%) patient, fair in 4 patients (2.3%), bad in 30 (17.1%) and lost in 69 (39.4%). Visual deterioration was another complaint with a mean duration at presentation being 7 months, 74 (42.2%) patients complained of visual deterioration and 20 patients had a no perception of light in either one or both eyes at presentation. Fundus examination revealed bilateral papilledema in 94 (53.7%) patients and optic atrophy in 17 (9.7%) patients. Subjective complaints of lower cranial nerve involvement were seen in only 19 (10.5%) patients, the mean duration before presentation was 2.3 months and was much shorter than other symptoms. However, on clinical examination 61 (34.9%) patients had impaired pharyngeal sensation and absent gag reflex. Three patients had aspiration pneumonitis at presentation and required pre-operative tracheostomy for adequate tracheal toilet. One patient underwent percutaneous gastrostomy prior to surgery. Other symptoms included cerebellar ataxia, facial palsy, facial numbness, limb spasticity due long tract involvement, hemifacial spasm, headache and vomiting [Table 1].

Radiological features

In our series, one patient a small (<10 mm) tumor, 5 (2.9%) patients had medium sized (10-25 mm) tumors, 36 (20.9%) patients had large size (25-40 mm) tumors and 130 (75.5%) patients had giant (>40 mm) tumors.

Brainstem compression was seen in 153 (89.4%) patients. NCCT (bone window) was done in 43 patients, of these 32 (74.4%) patients had dilatation of the internal auditory meatus. 110 (63.9%) patients had hydrocephalus at presentation. In patients with hydrocephalus complete obstruction of the fourth ventricle was seen in 57 patients, partial compression was seen in 48 and a patent fourth ventricle was seen in 5 patients. We observed significant correlation between the extent of ventricular occlusion and development of hydrocephalus (Spearman's rho = 0.236, P < 0.01) and also between the size of the VS and the extent of ventricular occlusion (Spearman's rho = 0.38, P < 0.01) [Tables 2 and 3].

Hydrocephalus

A total of 110 patients had hydrocephalus on radiological study at admission; we observed significant correlation between the size of VS and hydrocephalus (Spearman's rho = 0.259, P < 0.01) [Table 4].

Clinically symptomatic hydrocephalus was seen in only 23 (13.1%) patients, and they underwent CSF diversion prior to definitive surgery for VS. Of these patients, 20 (11.4%) patients underwent ventriculoperitoneal (VP) shunt surgery, one patient underwent an endoscopic third ventriculostomy and two patients underwent emergency external ventricular drainage (EVD). Of these, four patients (one patient with Parkinson's disease, one with NF-2 and cachexia, one with renal failure and one who refused further treatment) underwent only VP shunt and were kept on follow-up.

All the other patients without symptomatic hydrocephalus underwent definitive surgery for VS. Following surgery, four patients underwent EVD for acute hydrocephalus as a result of operative site hematoma, of these in two patients could be weaned of the EVD without VP shunt, one patient with ventriculitis underwent Ommaya reservoir placement for ventricular antibiotic instillation and CSF drainage for 4 weeks but did not require a VP shunt. 8 (4.6%) patients developed gradually symptomatic hydrocephalus following surgery and underwent VP shunt.

Operative outcome

165/169 patients underwent surgery for VS; three patients with bilateral tumors underwent surgery on both sides, two patients underwent resurgery for residual tumor 6 weeks after the primary surgery and one patient underwent redo surgery for recurrent tumor. On analyzing the result of surgical excision in our patients, complete surgical excision with the removal of the intrametral part was possible in 159/171 (92.9%) patients. In 12 (7.0%) patients who underwent subtotal excision of VS, part of the tumor capsule was seen densely adherent to the

surface of the brain stem. Manipulation of the capsule was associated with alterations in the hemodynamic status during surgery or judged as detrimental due to potentially debilitating deficits resulting from brainstem injury.

Table 1: Distribution of symptoms in patients with giant vestibular schwannoma

Symptoms	Percentage		Mean duration (months)
	Yes	No	
Headache	66.4		14.2
Vomiting	23.8		7.3
Hearing impairment	95.2		20.8
Facial hyposthesia	39.2		10
Tinnitus	28.4		17.2
Facial palsy	22.7		7.5
Disequilibrium	77.3		7.8
Lower cranial nerve palsy	28.4		2.3
Loss of taste sensation	18.9		5.1
Visual loss	38.1		7
Trigeminal neuralgia	2.9		6
Limb spasticity	4.2		4
Hemifacial spasm	0.5		3
Vertigo	11.9		14.9

Table 2: Comparing ventricular occlusion with hydrocephalus

Fourth ventricular occlusion	Hydrocephalus		Total
	Yes	No	
Patent	5	14	19
Partial	48	27	75
Complete	57	21	78
Total	110	62	172

Spearman's rho=0.236; P<0.01

Table 3: Comparing ventricular occlusion with size of the tumor

Fourth ventricular occlusion	Jackler stage (size of the tumor in mm)				Total
	Small	Medium	Large	Giant	
Patent	1	4	9	5	19
Partial	0	1	18	56	75
Complete	0	0	9	69	78
Total	1	5	36	130	172

Spearman's rho=0.381; P<0.01

Table 4: Distribution of hydrocephalus in cases of various tumor sizes

Jackler stage (size of the tumour in mm)	Hydrocephalus		Total cases
	Yes	No	
Small (<10)	0	1	1
Medium (10-24)	1	4	5
Large (25-3.9)	17	19	36
Giant (>40)	92	38	130
Total	110	62	172

Spearman's rho=0.259; P<0.01

Neurological outcomes and complications

Nine (5.2%) patients developed post-operative hematoma, one patient had an extradural hematoma and eight patients had operative site hematoma and needed surgical evacuation. Fifteen (8.57%) patients underwent tracheostomy for either prolonged ventilatory support or lower cranial nerve palsy with inability to clear oral and tracheal secretions. Facial nerve was anatomically preserved in 64.3% ($n = 104$) cases where total or near total excision of the schwannoma was performed.

Postoperative complications

CSF leak from the surgical site or pseudomeningocele at the surgical site occurred in 18 (10.5%) patients, two patients developed CSF otorrhea and one patient developed CSF rhinorrhea. One patient had obstructive hydrocephalus in the postoperative NCCT and underwent VP shunt. In the remaining 17 (9.71%) patients, the CSF leak was initially managed with serial lumbar puncture or lumbar drainage for 3 days. Only two patients continued to have persistent CSF leak after CSF drainage, they were treated with lumboperitoneal (LP) shunts with resolution of CSF leak. All four patients with CSF rhinorrhea had resolution of symptoms after LP for 3 days. Two patients with otorrhea developed meningitis, one improved after CSF drainage and the other died of septicemia. One patient developed delayed pseudomeningocele at the surgical site, the post-operative NCCT revealed communicating hydrocephalus and the patient was taken up for a LP shunt. The condition did not resolve and the surgical site was re-explored and dural repair done, followed by a VP shunt with resolution of the pseudomeningocele.

The number of complications seen following surgery was more in patients having hydrocephalus, however the difference was not statistically significant ($P > 0.05$).

Complications in patients with hydrocephalus and pre-operative CSF diversion [Table 5 and Figure 1]

Thirteen out of 18 patients who developed CSF leak from the surgical site had hydrocephalus, while only 1 out of 19 patients who underwent CSF diversion followed by definitive surgery developed CSF leak. Among patients who developed CSF otorrhea/rhinorrhea 3/6 had hydrocephalus, however, no patient with a pre-operative shunt developed CSF otorrhea/rhinorrhea. Six out of 9 patients who developed hematoma following surgery had hydrocephalus prior to surgery, however, no patient with a pre-operative shunt developed hematoma at the operative site. Among patients who required tracheostomy and prolonged ventilation (>7 days) following surgery, 12/17 had hydrocephalus, however, this complication was seen in only 4/17 patients who underwent pre-operative CSF diversion. Patients

who underwent shunt prior to surgery had a fewer complications and a better outcome following surgery however the difference was not statistically significant ($P > 0.05$).

Mortality

The mortality in our series was 8 (4.5%) patients. One patient had massive hemorrhage from tentorial vessels and developed cardiogenic shock intraoperatively and succumbed in the post-operative period. Two patients developed septicemia with renal failure, one patient had meningitis following CSF otorrhea and died. Two patients developed bronchopneumonia and respiratory failure, one patient with a large cystic schwannoma experienced neurological worsening, probably due to brainstem compression, one patient developed massive cerebellar and brainstem infarction leading to death in the post-operative period.

DISCUSSION

The presence of fourth ventricular obstruction caused by large or giant VS was the most common cause of hydrocephalus in our series. This occurs due to either neglect of symptoms or delay in referral for treatment

Table 5: Comparison of post-operative complications in patients with and without pre-operative CSF diversion

Complications	CSF diversion		Total
	Yes	No	
CSF leak	1	17	18
CSF otorrhea	0	2	2
CSF rhinorrhea	0	4	4
Operative site hematoma	0	9	9
Prolonged ventilation	4	13	17
Brainstem injury	1	0	1
Total	6	45	51

CSF - Cerebrospinal fluid

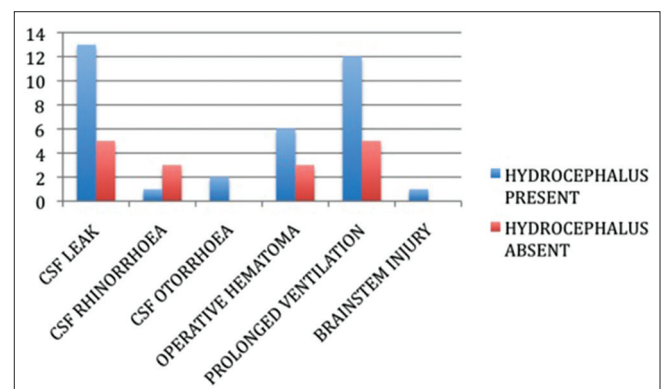


Figure 1: Comparison of incidence of complications in patients with and without hydrocephalus

(hearing loss-20 months, headache 14 months). We also found that untreated hydrocephalus causes an increase in postoperative CSF leak and operative site hematoma, this difference was however not statistically significant. In most cases of hydrocephalus resolved after microsurgical excision of the VS. We shall elaborate on these findings in detail.

The reported incidence of hydrocephalus in patients with VS is 3.7-42%.^[7-9] Several studies have also found that the size of VS or CPA tumors is related to hydrocephalus.^[5,10-13] There are several postulated mechanisms of hydrocephalus and its association with posterior fossa tumors like the VS. Hydrocephalus may result from compression of the fourth ventricle as seen in large posterior fossa tumors.^[14] High protein content in the CSF due to protein shedding by tumor and plugging of the arachnoid granulations may cause communicating hydrocephalus.^[9,15] Other theories include tumor-associated alterations in CSF flow dynamics within the basilar cisterns cause hydrocephalus, increased fibrinogen levels, meningeal adhesions caused by recurrent tumor bleeds and arachnoiditis induced by the proteins.^[10]

Development of communicating hydrocephalus and increased protein content in CSF obtained from the cisterna magna has been demonstrated for VS, especially in small tumors.^[7,8,12] While these postulates hold true for small VS, in large and giant VS with gross brainstem compression and distortion of the fourth as seen in this study correlating size with ventricular occlusion, direct long standing obstruction of the CSF circulation appears to be a more likely etiology.

Delayed development of hydrocephalus following surgical excision is very rare; only one patient developed delayed symptomatic hydrocephalus. The delay can be due to the anatomical distortion of the fourth ventricle, ependymal adhesions within the fourth ventricle and contamination of the arachnoid space by blood products. Sometimes, normalization of ventricular size following surgery may take a very long time due to the decrease in the ventricular elasticity caused by chronic hydrocephalus [Figure 2].^[7,12]

Complications and their relation to hydrocephalus

The incidence of CSF leak in VS ranges for 3-26.7%,^[14,16-19] A recent meta-analysis narrows it to 6-10%.^[20] The rate of CSF leak in our series was 10.5%. We noted an increase in the incidence of CSF leaks following VS surgery in patients with hydrocephalus [Figure 1]. Another feature was that patients who underwent CSF diversion prior to microsurgical excision of VS had fewer instances of CSF leaks [Table 5]. However, both these findings were not statistically significant ($P > 0.05$). Prolonged ventilatory support and the need for a tracheostomy were also greater in patients with hydrocephalus [Figure 1], however

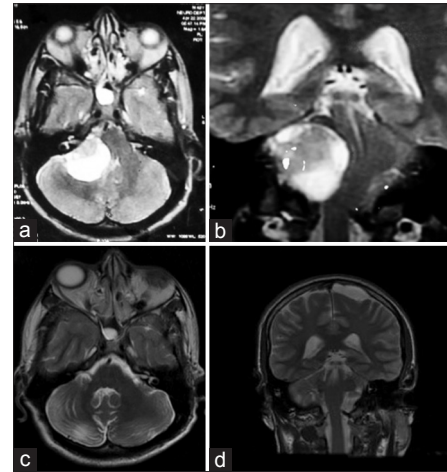


Figure 2: (a and b) T2-W magnetic resonance imaging axial and coronal, showing a giant (>4 cm) vestibular schwannoma with compression of the brainstem and occlusion of the cerebrospinal fluid (CSF) pathway. (c and d) Post-operative T2-W images in axial and coronal showing complete tumor excision with restoration of the contours of the brainstem and CSF pathway

the relationship was not statistically significant. This is probably because larger tumors size tend to gradually cause caudal shift of the cerebellum and brainstem compression.^[10] These patients often need prolonged ventilation and their weaning of the ventilator was delayed following surgery.

Post-operative hematoma occurred in 10 (5.7%) patients. An increased incidence of hematoma was seen in patients with hydrocephalus. In the presence of tonsillar descent due to a posterior fossa mass, the cisterna magna may be difficult to access. Operating with a tense cerebellum limits the exposure of the tumor and excessive retraction on a tense cerebellar hemisphere may result in cerebellar hematoma, tearing of veins and post-operative cerebellar swelling. All these cause an increase in post-operative morbidity. In turn, post-operative hematoma results in post-operative deterioration in sensorium, acute hydrocephalus, cerebellar and brainstem edema.^[21]

A small subset of patients ($n = 23$) with symptomatic hydrocephalus resulting in acute neurological deterioration however did benefit from pre-operative CSF diversion [Table 5], they represent a group, which presents very late in the course of the illness, either due to delayed referral, or poor access to health care. However we feel that most patients with hydrocephalus can be managed without a prophylactic shunt.

Most patients in our study presented with a long history of illness, were diagnosed and treated late. This is supported by the long duration of symptoms seen in patients at presentation (20 months for hearing loss and 14 months for headache). Even the duration of poorly

tolerated symptoms like vomiting and visual decline was prolonged (7 months), an important finding was the presence of papilledema or optic atrophy, which was seen in 72.3% (81/112) of our patients and favors the presence of chronic raised intracranial pressure (ICP) as the cause for blindness, all these point to delay in neurosurgical referral. Aforementioned literature also suggests that in societies with easy access to health care and a low threshold for detailed investigation, the delay in referral is shorter and the mean tumor size smaller at diagnosis, resulting in a fewer number of patients with hydrocephalus at presentation.

CONCLUSIONS

VS can cause hydrocephalus by fourth ventricular obstruction. The size of the VS correlates with the distortion of the fourth ventricle and hydrocephalus. Neurological sequelae of chronic raised ICP like blindness is a result of delayed referral. Hydrocephalus causes no statistically significant increase in postoperative complications like CSF leak and postoperative hematoma. Preoperative CSF diversion in symptomatic patients with features of raised ICP like altered sensorium is a life-saving measure, however no statistically significant decrease in the incidence of CSF leak or hematoma was seen. Patients with hydrocephalus presenting with acute symptoms of raised ICP benefit from CSF diversion. However, in most patients, tumor resection will restore patency of the CSF pathway and CSF diversion can be avoided.

REFERENCES

- Jain VK, Mehrotra N, Sahu RN, Behari S, Banerji D, Chhabra DK. Surgery of vestibular schwannomas: An institutional experience. *Neurol India* 2005;53:41-5.
- Mehrotra N, Behari S, Pal L, Banerji D, Sahu RN, Jain VK. Giant vestibular schwannomas: Focusing on the differences between the solid and the cystic variants. *Br J Neurosurg* 2008;22:550-6.
- Sahu RN, Mehrotra N, Tyagi I, Banerji D, Jain VK, Behari S. Management strategies for bilateral vestibular schwannomas. *J Clin Neurosci* 2007;14:715-22.
- Gerganov VM, Pirayesh A, Nouri M, Hore N, Luedemann WO, Oi S, et al. Hydrocephalus associated with vestibular schwannomas: Management options and factors predicting the outcome. *J Neurosurg* 2011;114:1209-15.
- Pirouzmand F, Tator CH, Rutka J. Management of hydrocephalus associated with vestibular schwannoma and other cerebellopontine angle tumors. *Neurosurgery* 2001;48:1246-53.
- Samii M, Gerganov VM, Samii A. Functional outcome after complete surgical removal of giant vestibular schwannomas. *J Neurosurg* 2010;112:860-7.
- Fukuda M, Oishi M, Kawaguchi T, Watanabe M, Takao T, Tanaka R, et al. Etiopathological factors related to hydrocephalus associated with vestibular schwannoma. *Neurosurgery* 2007;61:1186-92.
- Bloch J, Vernet O, Aubé M, Villemure JG. Non-obstructive hydrocephalus associated with intracranial schwannomas: Hyperproteinorrhachia as an etiopathological factor? *Acta Neurochir (Wien)* 2003;145:73-8.
- Gardner WJ, Spittler DK, Whitten C. Increased intracranial pressure caused by increased protein content in the cerebrospinal fluid; an explanation of papilledema in certain cases of small intracranial and intraspinal tumors, and in the Guillain-Barre syndrome. *N Engl J Med* 1954;250:932-6.
- Steenerson RL, Payne N. Hydrocephalus in the patient with acoustic neuroma. *Otolaryngol Head Neck Surg* 1992;107:35-9.
- Rogg JM, Ahn SH, Tung GA, Reinert SE, Norén G. Prevalence of hydrocephalus in 157 patients with vestibular schwannoma. *Neuroradiology* 2005;47:344-51.
- Tanaka Y, Kobayashi S, Hongo K, Tada T, Sato A, Takasuna H. Clinical and neuroimaging characteristics of hydrocephalus associated with vestibular schwannoma. *J Neurosurg* 2003;98:1188-93.
- Atlas MD, Perez de Tagle JR, Cook JA, Sheehy JP, Fagan PA. Evolution of the management of hydrocephalus associated with acoustic neuroma. *Laryngoscope* 1996;106:204-6.
- Briggs RJ, Shelton C, Kwartler JA, Hitselberger W. Management of hydrocephalus resulting from acoustic neuromas. *Otolaryngol Head Neck Surg* 1993;109:1020-4.
- Sayk J. The cerebrospinal fluid in brain tumours. In: Vinken PJ, Bruyn GW, editors. *Handbook of Clinical Neurology: Tumours of the Brain and Skull*. Vol. 16. North-Holland, Amsterdam: Elsevier; 1974. p. 360-417.
- Brennan JW, Rowed DW, Nedzelski JM, Chen JM. Cerebrospinal fluid leak after acoustic neuroma surgery: Influence of tumor size and surgical approach on incidence and response to treatment. *J Neurosurg* 2001;94:217-23.
- Stieglitz LH, Wrede KH, Gharabaghi A, Gerganov VM, Samii A, Samii M, et al. Factors affecting postoperative cerebrospinal fluid leaks after retrosigmoidal craniotomy for vestibular schwannomas. *J Neurosurg* 2009;111:874-83.
- Tonn JC, Schlake HP, Goldbrunner R, Milewski C, Helms J, Roosen K. Acoustic neuroma surgery as an interdisciplinary approach: A neurosurgical series of 508 patients. *J Neurol Neurosurg Psychiatry* 2000;69:161-6.
- Hoffman RA. Cerebrospinal fluid leak following acoustic neuroma removal. *Laryngoscope* 1994;104:40-58.
- Sughrue ME, Yang I, Aranda D, Rutkowski MJ, Fang S, Cheung SW, et al. Beyond audiofacial morbidity after vestibular schwannoma surgery. *J Neurosurg* 2011;114:367-74.
- Sanna M, Taibah A, Russo A, Falcioni M, Agarwal M. Perioperative complications in acoustic neuroma (vestibular schwannoma) surgery. *Otol Neurotol* 2004;25:379-86.

How to cite this article: Nair P, Singh DK, Sahu RN, Kumar R, Behari S, Jaiswal AK, et al. Large vestibular schwannomas and hydrocephalus: Lessons learnt from a single centre experience. *Indian J Neurosurg* 2014;3:19-24.
Source of Support: Nil, **Conflict of Interest:** None declared.