

Subtemporal keyhole approach to Meckel's cave epidermoid cyst: Case report and review of literature

Qing Lan, Jeffrey Tanudjaja, Ai Lin Chen

Department of Neurosurgery, The Second Affiliated of Soochow University, Suzhou, China

ABSTRACT

We report the first case of subtemporal keyhole surgery approach with neuronavigation and endoscopy, for total resection of an uncommon case of epidermoid cyst of the Meckel's cave in a 43-year-old woman who presented with paroxysmal headache and diplopia. Magnetic resonance imagines revealed the tumor location on the right area of the cavernous sinus. Postoperative examinations showed complete recovery of symptoms.

Key words: Epidermoid cyst, Meckel's cave, subtemporal keyhole approach

INTRODUCTION

Intracranial epidermoid tumors are relatively uncommon and benign congenital lesions that constitute approximately 0.2-1.8% of all intracranial tumors.^[1,2] They are predominantly located lateral in position, most often in the parapontine area, including the cerebellopontine angle and the parapituitary region.^[3,4] Only few cases of epidermoid tumors involving the Meckel's cave have been reported.^[1,4-8] There has been no mention of keyhole approach with the aid of neuronavigation and endoscopy in resection of the tumor. We present the first case of subtemporal keyhole surgical approach with the aid of neuronavigation and endoscopy for epidermoid cyst located in the right Meckel's cave.

CASE REPORT

A 43-year-old woman presented with a mild paroxysmal headache accompanied with decreased vision and diplopia for 40 days. Neurological examination showed decreased vision due to myopia, diplopia and hemianopia of the right eye's temporal quadrant. A magnetic resonance imagines (MRI) studies showed a 17 mm × 22 mm × 16 mm lesion originating at trigeminal

ganglion [Figure 1]. The lesion showed adhesions to the cavernous sinus and compression of the internal carotid artery of the cavernous segment.

The three aims of the surgical treatment were to alleviate the patient's symptoms, total resection of the tumor, and minimal surgical complications and scar. This led to our choice of keyhole approach assisted by neuronavigation and endoscopy for complete removal of the tumor.

Lumbar cerebrospinal drainage was placed and 100 ml of mannitol was given to facilitate the operative exposure. A 5 cm straight incision above the right zygomatic arch was made and temporal muscle retracted to the expose the skull. The zygomatic arch was not removed. The temporal lobe was retracted until the floor of the middle fossa was visible. Neuronavigation was used to locate the lesion, which was beneath the branches of the trigeminal nerve. The tentorium and the outer layer of the Meckle's cave were dissected to expose the tumor. With the aid of endoscopy, incision of the dural capsule revealed a pearly mass characteristic of an epidermoid cyst. The cystic content was soft in texture, with greyish yellow sediment and calcification. It was removed with suction and the area was repeatedly washout with normal saline to minimize the chance of potential aseptic meningitis. Outer layer dura of the Meckel's cave was repaired with an artificial dura—which we believed could minimize adhesions of the trigeminal nerve with the surrounding tissue, leading to trigeminal neuralgia, as well as reduce the possibility of cyst contents in the subarachnoid space.

The postoperative course was uneventful and neurological examination revealed complete relief from

Access this article online	
Quick Response Code:	Website: www.ijns.in
	DOI: 10.4103/2277-9167.132008

Address for correspondence: Dr. Jeffrey Tanudjaja, Department of Neurosurgery, The Second Affiliated of Soochow University, Suzhou - 215 004, China. E-mail: jtanum@hotmail.com

symptoms. A follow-up MRI confirmed total tumor removal [Figure 2]. Histological examination confirmed that the tumor was an epidermoid cyst composed of necrotic keratinized mass and flattened squamous epithelium [Figure 3].

DISCUSSION

Epidermoid cysts are benign, congenital, true ectodermal inclusion tumors, lined by an epithelium and are not considered true neoplasm. Epidermoid cysts stem from ectopic multipotential ectodermal cells that are carried along with the internal migration of the otic capsule and retained within the neural groove at the time of closure at a gestational age of 3-5 weeks.^[5,7,9]

Epidermoid masses are seen as low density lesions on computed tomography scans with minimal contrast enhancements due to their low vascularity. On MRI, epidermoids usually show an isointense or hypointense signal relative to the gray matter on T1-weighted images and a hyperintense signal relative to the cerebrospinal

fluid on T2-weighted images. On fluid-attenuated inversion recovery images, epidermoids became hyperintense and diffusion-weighted images (DWI) displayed bright appearance of epidermoid cyst, which was helpful in assessing residual tumors after operation.^[8,10]

According to Gharabaghi *et al.*,^[6] epidermoid cysts involving the cavernous sinus can be divided into three categories: Intracavernous, interdural and extracavernous. Intracavernous epidermoid cysts are located within the venous channels of the cavernous sinus between the medial wall and the inner layer of the lateral wall of the cavernous sinus. These tumors tend to wrap around the internal carotid artery and compress the cranial nerves. Interdural epidermoid cysts are located between the inner and outer layer of the lateral wall of the cavernous sinus. Extracavernous epidermoid cysts are frequently located in the Meckel's cave, arising from the petrous apex and invade or compress the cavernous sinus. Tatagiba *et al.*^[4] stated that some neural crest cells, which developed into skin, seem to remain entrapped in the arachnoid layer between the lateral walls of the cavernous sinus during the incomplete maturation stage. Therefore, this resulted in the development of epidermoid lesions.

In our case, the MRI showed an enlargement of the Meckel's cave area, which may suggest the location of the tumor. The initial MRI diagnosis for this patient was trigeminal schwannoma. It had similar radiological features to epidermoids^[5,8,10] but since the MRI T1-weighted contrast images showed no contrast enhancement and DWI images demonstrated restricted diffusion in the region of the lesion, the imaging was suggestive of extracavernous epidermoid cysts.

The different surgical approaches for tumors of the Meckel's cave are summarized in Table 1. The most common approach includes the frontotemporal approach, pterional approach, zygomatic approach, orbitozygomatic

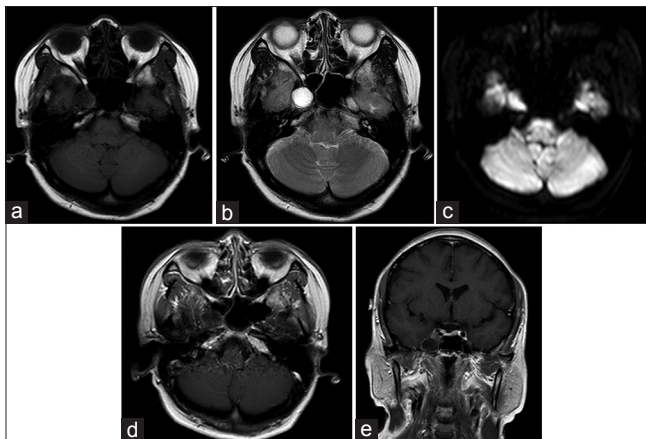


Figure 1: Preoperative magnetic resonance images. (a) Axial T1-weighted scan images show hypointense lesion. (b) Axial T2-weighted scan shows a hyperintense lesion. (c) Diffusion-weighted image shows hyperintense lesion. (d and e) T1-weighted with contrast showed enhancement of the rim with no contrast enhancement of the lesion

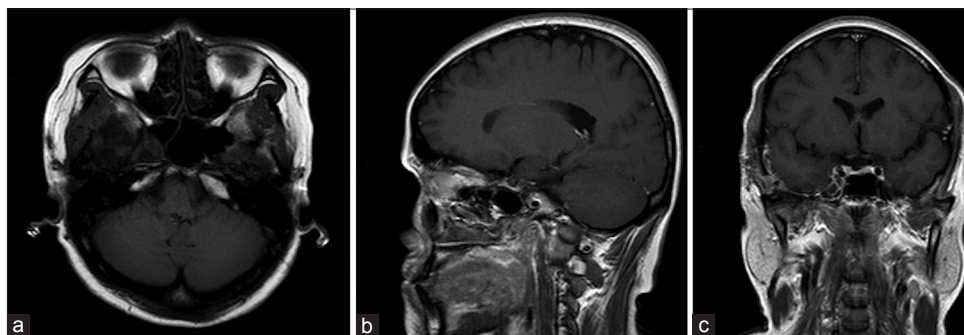
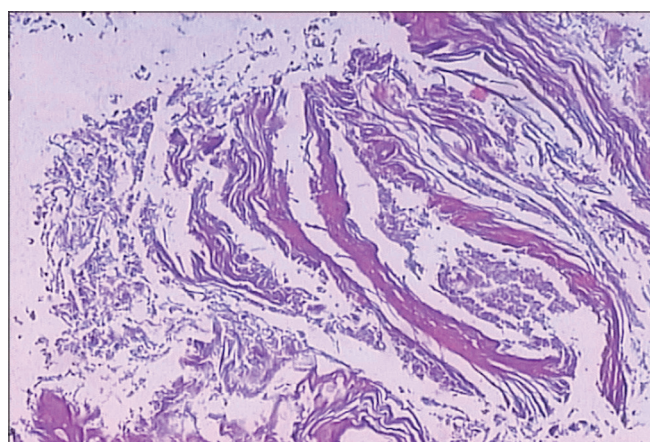


Figure 2: Postoperative magnetic resonance images. (a) Axial, (b) Sagittal and (c) Coronal T1-weighted magnetic resonance images show tumor removal of the cavernous region

Table 1: Summary of different surgical approaches in Meckel's cave epidermoid

Case number	Author	Age/sex	Site of lesion	Main symptoms	Approach/resection grade
1	Kline and Galbraith 1981 ^[11]	51/male	Right Meckel's cave	Dysfunction of CN 3, 5; 1 st and 2 nd branch, 6	Frontotemporal/subtotal
2	Sepehrnia et al. 1991 ^[12]	-/-	Petrous apex	Headache; dysfunction of CN 3, 5	Combined retromastoid subtemporal/total
3	Ohta et al. 1997 ^[9]	54/female	Right Meckel's cave	Dysfunction of CN 3, 4, 5, 6	Orbitozygomatic approach/subtotal
4	Nadkarni et al. 2000 ^[5]	27/female	Right Meckel's cave	Dysfunction of CN 5	Subtemporal interdural/total
5	Inoue et al. 2001 ^[13]	72/F	Right Meckel's cave (middle fossa floor)	Dysfunction of CN 5; 3 rd branch	Temporal craniotomy/subtotal
6	Furtado and Hedge 2009 ^[7]	25/female	Left petrous apex	Trigeminal neuralgia	Subtemporal extradural with neuronavigation/total
7	Arai et al. 2010 ^[8]	27/female	Right Meckel's cave	Headache; right face numbness	Orbito-zygomatic extrdural with endoscopy/total
8	Present study	43/female	Right Meckel's cave	Headache; diplopia	Keyhole subtemporal extradural with neuronavigation and endoscopy/total

CN - Cranial nerve

**Figure 3:** The histopathological examination shows a necrotic keratinized mass and flattened squamous epithelium

approach and subtemporal approaches. For our case, the tumor was located within the dural confines of meckel's cave and we were able to remove it totally including the capsule through subtemporal keyhole approach, with the aid of neuronavigation and endoscopy.

We first placed the fiducials around the right temporal region and then ordered an MRI scan for a clear picture of the tumor area. We used the neuronavigation at the beginning and during the operation to locate the depth and the breadth of the tumor and also to reduce the risk of damaging the surrounding neural structures and vessels. Due to the small bone window and dural incision, we weren't to be to view the beyond the sides of the incision with the microscope. With the help of endoscopy, we were able to view these blind spots to remove the tumor totally. We believed our approach has a smaller window compared to the traditional approaches and avoids unnecessary brain tissue exposure and hence minimizes surgical trauma and reduces the risk of infections.

CONCLUSION

We believe that this is the first case of keyhole approach with the aid of neuronavigation and endoscopy for Meckel's cave epidermoid cyst. It has clearly shown its advantages in being a minimally invasive procedure that allows total removal of intracranial epidermoid cystic content and its capsule. Thus subtemporal keyhole approach with neuronavigation and endoscopy can be considered for future surgical treatment of epidermoid cyst located in the Meckel's cave.

REFERENCES

1. Beck DW, Menezes AH. Lesions in Meckel's cave: Variable presentation and pathology. *J Neurosurg* 1987;67:684-9.
2. Wu Y, Dong J. Microsurgical anatomy of the cavernous sinus and Meckel's cave by subtemporal epidural keyhole approach. *Chin J Clin Neurosurg (China)* 2007;04:223-6.
3. Netsky MG. Epidermoid tumors. Review of the literature. *Surg Neurol* 1988;29:477-83.
4. Tatagiba M, Iaconetta G, Samii M. Epidermoid cyst of the cavernous sinus: Clinical features, pathogenesis and treatment. *Br J Neurosurg* 2000;14:571-5.
5. Nadkarni T, Dindorkar K, Muzumdar D, Goel A. Epidermoid tumor within Meckel's cave – Case report. *Neurol Med Chir (Tokyo)* 2000;40:74-6.
6. Gharabaghi A, Koerbel A, Samii A, Safavi-Abbasi S, Tatagiba M, Samii M. Epidermoid cysts of the cavernous sinus. *Surg Neurol* 2005;64:428-33.
7. Furtado SV, Hegde AS. Trigeminal neuralgia due to a small Meckel's cave epidermoid tumor: Surgery using an extradural corridor. *Skull Base* 2009;19:353-7.
8. Arai A, Sasayama T, Koyama J, Fujita A, Hosoda K, Kohmura E. Epidermoid cyst in Meckel's cave with unusual computed tomography and magnetic resonance imaging findings. Case report. *Neurol Med Chir (Tokyo)* 2010;50:701-4.
9. Ohta H, Ottomo M, Nakamura T, Yokota A. A case of epidermoid tumor inside the Meckel's cave. *No Shinkei Geka* 1997;25:943-7.
10. Nagasawa D, Yew A, Safaei M, Fong B, Gopen Q, Parsa AT, et al. Clinical characteristics and diagnostic imaging of epidermoid tumors. *J Clin Neurosci* 2011;18:1158-62.
11. Kline LB, Galbraith JG. Parasellar epidermoid tumor presenting as painful ophthalmoplegia. *J Neurosurg* 1981;54:113-7.
12. Sepehrnia A, Samii M, Tatagiba M. Management of intracavernous

tumours: An 11-year experience. Acta Neurochir Suppl (Wien) 1991;53:122-6.

13. Inoue Y, Ohata K, Nakayama K, Haba T, Shakudo M. An unusual middle fossa interdural epidermoid tumor. Case report. J Neurosurg 2001;95:902-4.

How to cite this article: Lan Q, Tanudjaja J, Chen AL. Subtemporal keyhole approach to Meckel's cave epidermoid cyst: Case report and review of literature. Indian J Neurosurg 2014;3:50-3.

Source of Support: Nil, **Conflict of Interest:** None declared.

FORM IV

Statement about ownership and other particulars about newspaper (Indian Journal of Neurosurgery) to be published in the first issue every year after the last day of February as per Rule 8

1. Place of publication : Mumbai
2. Periodicity of its publication : Four Monthly (April, August and December)
3. Printer's Name : Hemant Manjrekar
Nationality : Indian
(a) Whether a citizen of India? : Yes
(b) If a foreigner, the country of origin : N.A.
Address : B5-12, Kanara Business Center,
Off Link Rd, Ghatkopar (E),
Mumbai - 400075, India
4. Publisher's Name : Hemant Manjrekar
Nationality : Indian
(a) Whether a citizen of India? : Yes
(b) If a foreigner, the country of origin : N.A.
Address : B5-12, Kanara Business Center,
Off Link Rd, Ghatkopar (E),
Mumbai - 400075, India
Phone: 91-22-6649 1818/1816,
5. Editor's Name : Dr. P Sarat Chandra
Nationality : Indian
(a) Whether a citizen of India? : Yes
(b) If a foreigner, the country of origin : N.A.
Address : Department of Neurosurgery, Room 7, 6th Floor,
Neurosciences center AIIMS, New Delhi - 110 029, India.
6. Names and addresses of individuals who own the newspaper and partners or shareholders holding More than one per cent of the total capital. : Neurological Surgeons' Society of India
- I, Dr. P Sarat Chandra hereby declare that the particulars given above are true to the best of my knowledge and belief.

Date: 1st March 2014

Hemant Manjrekar

Dr. P Sarat Chandra