

**Address for correspondence:** Dr. Sameer A.H.Ansari,  
Department of Pathology, Grant Medical College and Sir JJ group of  
Hospitals, Mumbai, Maharashtra, India.  
E-mail: drsameeransari@yahoo.co.in

## References

1. Huvos AG, Lucas JC Jr, Foote FW Jr. Metaplastic carcinoma: A rare form of mammary cancer. *N Y State J Med* 1973;73:1078-82.
2. Jadhav DS, Bagate AV, Swami SY, Sonawane BR. Metaplastic carcinoma of breast giant cell rich variant. *In J Cancer* 2010;47:88-9.
3. Tavassoli FA. Classification of metaplastic carcinoma of breast. *Pathol Annu* 1992;27:89-119.
4. Herrington CS, Terin D, Buley L, Athanasou N. Osteosarcomatous differentiation in ca breast: A case of Metaplastic carcinoma with osteoclasts and osteoclastic giant cells. *Histopathology* 1994;24:282-5.
5. Wargotz ES, Norris HJ. Metaplastic carcinoma of breast versus metaplastic carcinoma of breast with osteoclastic giant cells. *Human pathol* 1990;21:1142-50.
6. Rosen PP. Carcinoma with metaplastic in: Rosen's Breast pathology. 2<sup>nd</sup> ed. Philadelphia: Lippincott William and Wilkins; 2001. p. 425-53.
7. Suzuki-Uematsu S, Shiraishi K, Ito T, Adachi N, Inage Y, Taeda Y, *et al*. Malignant phylloides tumor composed exclusively of a fibrosarcomatous component: A case-report and review of malignant phylloides tumor with metastasis. *Breast cancer* 2010;17:218-24.

### Access this article online

<p><b>Quick Response Code:</b></p> 	<p><b>Website:</b> www.sajc.org</p>
	<p><b>DOI:</b> 10.4103/2278-330X.103724</p>

## Gorham disease of mandible treated with post-operative radiotherapy

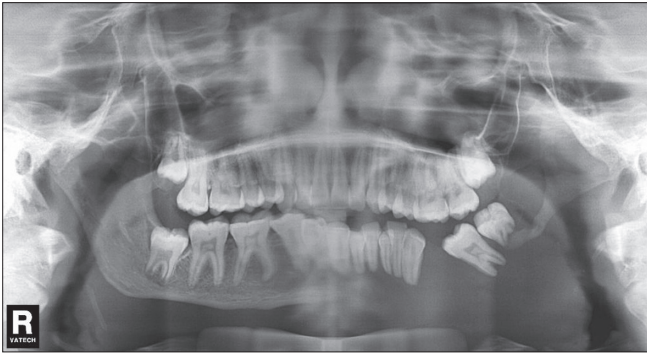Sir,

Gorham disease is considered a rare disease which is characterized by spontaneous, massive osteolysis and usually has a progressive course which eventually results in disappearance of the bone and its replacement with fibrous tissues. This condition is also known as Gorham–Stout syndrome, massive osteolysis, phantom bone disease, vanishing bone disease, disappearing bone disease, and progressive osteolysis.<sup>[1]</sup>

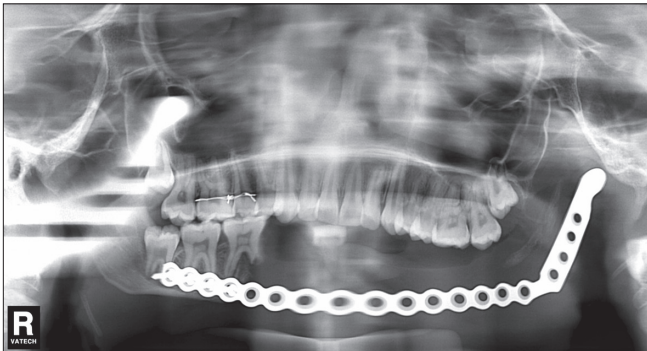A 19-year-old college student presented with complaint of pain in the left lower jaw along with loosening of teeth. On local examination, the patient had swelling in the left lower jaw. On radiograph, loss of bone was apparent in the left lower jaw suggestive of osteolysis with evident erosion of

left condylar process [Figure 1]. Contrast-enhanced computed tomography (CECT) scan was done which corroborated osteolysis in mandible with no lymphadenopathy or any other abnormality [Figure 2]. Histopathology was suggestive of chronic non-specific inflammation with lymphocytic infiltrates and absence of Langerhan's cells. The serum calcium level was normal, whereas serum alkaline phosphatase (ALP) was slightly elevated. Hence, in view of clinical and radiological features, a diagnosis of Gorham disease was made. Subsequently, debridement and reconstruction of mandible with a stainless steel plate were done [Figure 3]. The operative specimen histopathology was again showing fibrous connective tissue with features suggestive of chronic non-specific inflammation. After 6 weeks of surgery, the patient was treated with external beam radiotherapy by 40 Gy in 20 fractions over a period of 4 weeks [Figure 4]. He tolerated treatment well with only Grade 1 skin reactions. The patient has a follow-up of 7 months with sustained relief in pain [Figure 5].

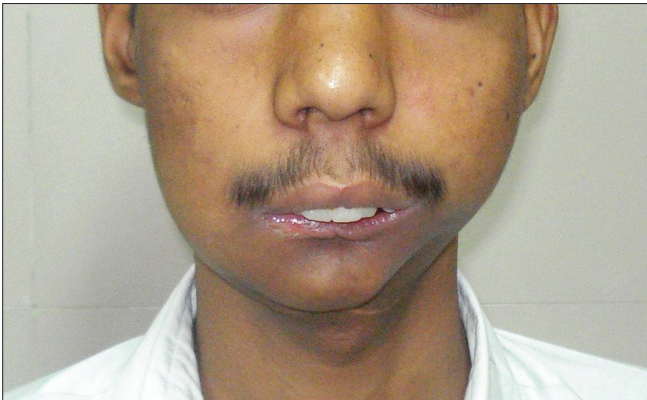
Gorham disease is a rare osteolytic disorder with only around 200 cases reported in English literature.



**Figure 1: Panoramic radiograph of mandible showing loss of bone of left lower mandible**



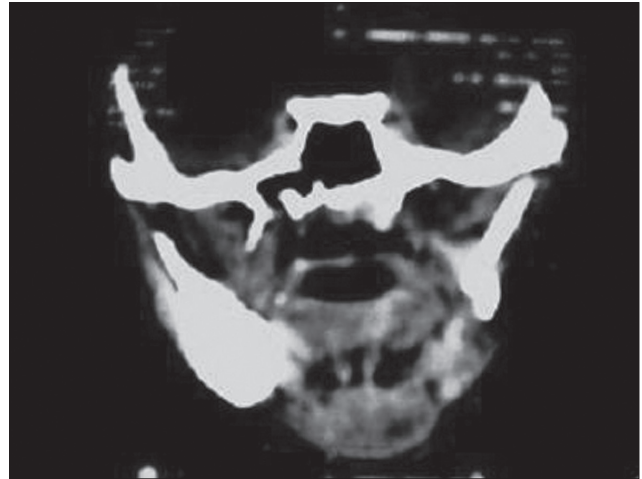
**Figure 3: Radiograph showing reconstruction of mandible with a stainless steel plate**



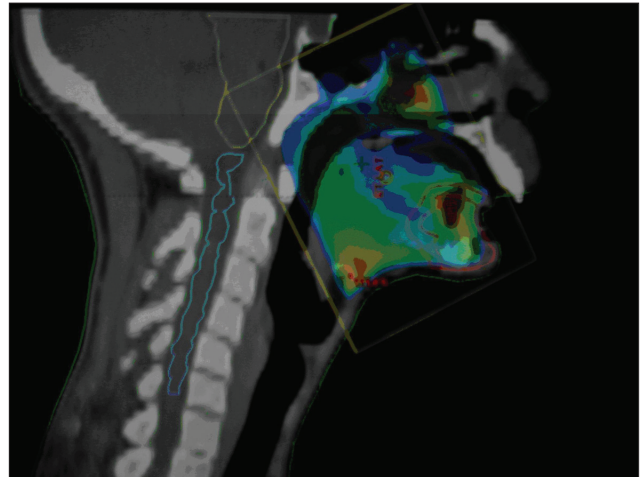
**Figure 5: Excellent cosmesis after 7 months of completion of radiotherapy**

Idiopathic osteolysis was first described by Jackson in 1838.<sup>[2]</sup> In 1955, Gorham and Stout established its clinical and pathological features, hence it is also known as Gorham–Stout disease. The age of onset as reported varies from 1 month to 75 years,<sup>[3]</sup> but is more commonly seen in the second and third decades of life. It can affect any bone of the body with predilection for pelvis, head and shaft of humerus, and mandible. About 40 cases involving maxillofacial region have been reported with mandible being the commonest site.<sup>[4]</sup>

Gorham disease is a diagnosis of exclusion which can be



**Figure 2: Preoperative computed tomography (CT) scan of face showing left lower mandible destruction**



**Figure 4: Eclipse treatment planning system image showing left lateral field and the dose color wash**

made only after reviewing the clinical, radiological and histopathological findings. Common bone diseases like hyperparathyroidism, metabolic bone disease and Paget's disease should be excluded to reach at this diagnosis. The patient may present with features of pathological fractures such as bony tenderness, deformity or muscular atrophy, and weakness secondary to bone loss. Blood investigations are essentially normal. Computed tomography (CT) scan can evaluate the extent of bone destruction and soft tissue extension. Magnetic resonance imaging (MRI) may be preferable for the purpose of soft tissue delineation.<sup>[5]</sup> Histopathological examination essentially remains non-contributory with findings of mostly non-specific features suggestive of chronic inflammation. Devlin *et al.*<sup>[6]</sup> implicated interleukin-6 (IL-6) as a potential humoral mediator. Their study demonstrated that levels of IL-6 in a patient with Gorham disease to be seven times the normal level. It was also seen that there was increased osteoclastogenesis and osteoclastic bone resorption *in vitro*

that was prevented with pre-treatment neutralizing antibody to IL-6.

Treatment aims at arresting the process of progressive osteolysis and providing mechanical support for the loss of bone. Surgery and radiotherapy are considered the mainstay of managing these lesions. Radiotherapy in moderate doses (25 Gy-40 Gy in conventional fractionation)<sup>[7]</sup> has been used to arrest osteolysis. Recently, long-term therapy with bisphosphonates has been used with benefit in this condition.<sup>[8]</sup> Other treatment options such as chemotherapy, calcium, fluoride, vitamin D, hormones, amino acids, adrenal extracts, UV radiation, somatotrophin, and transfusions of placental blood or blood from growing young children have been tried and have shown limited success.<sup>[9]</sup> Spontaneous recovery has also been documented in few cases.<sup>[10]</sup> This condition is usually compatible with life if involving extremity. However, it can be fatal in cases where vital structure like chest wall is involved.

In cases with active disease, it has been proposed that radical resection of involved bones followed by radiotherapy in moderate doses (30-50 Gy) should be delivered to arrest the disease process.<sup>[7,11,12]</sup> Surgical reconstruction should not be done in active phase due to risk of lyses of autologous bone grafts. In active disease where radical resections of bones are not possible, radiotherapy alone may be used as a definitive therapy.<sup>[11]</sup>

In conclusion, this report adds to the sparse literature on Gorham disease as a case which has been treated with surgery and post-operative radiotherapy with satisfactory outcome.

**Rakesh Kumar Gupta, Milind Kumar, Arun Verma,  
Subhash Pandit, Karuna Singh, Shipra Agarwal<sup>1</sup>,  
Bidhu K Mohanti, Goura Kishore Rath**

Departments of Radiation Oncology, and <sup>1</sup>Pathology, All India  
Institute of Medical Sciences, New Delhi, India

**Address for correspondence:** Dr. Milind Kumar,  
Departments of Radiation Oncology, and <sup>1</sup>Pathology, All India  
Institute of Medical Sciences, New Delhi, India  
E-mail: drmilindkumar@yahoo.com

## References

1. Gorham LW, Stout AP. Massive osteolysis (acute spontaneous absorption of bone, phantom bone, disappearing bone); its relation to hemangiomas. *J Bone Joint Surg Am* 1955;37-A:985-1004.
2. Jackson JB. A singular case of absorption of bone (a boneless arm). *Boston Med Surg J* 1838;18:368-9.
3. Boyer P, Bourgeois P, Boyer O, Catonné Y, Saillant G. Massive Gorham-Stout syndrome of the pelvis. *Clin Rheumatol* 2005;24: 551-5.
4. Escande C, Schouman T, Françoise G, Haroche J, Ménard P, Piette JC, *et al.* Histological features and management of a mandibular Gorham disease: A case report and review of maxillofacial cases in the literature. *Oral Surg Oral Med Oral Pathol Oral Radiol Endod* 2008;106:e30-7.
5. Kai B, Ryan A, Munk PL, Dunlop P. Gorham disease of bone: Three cases and review of radiological features. *Clin Radiol* 2006;61: 1058-64.
6. Devlin RD, Bone HG 3rd, Roodman GD. Interleukin-6: A potential mediator of the massive osteolysis in patients with Gorham-Stout disease. *J Clin Endocrinol Metab* 1996;81:1893-7.
7. Ricalde P, Ord RA, Sun CC. Vanishing bone disease in a five year old: Report of a case and review of the literature. *Int J Oral Maxillofac Surg* 2003;32:222-6.
8. Lehmann G, Pfeil A, Böttcher J, Kaiser WA, Füller J, Hein G, *et al.* Benefit of a 17-year long-term bisphosphonate therapy in a patient with Gorham-Stout syndrome. *Arch Orthop Trauma Surg* 2009;129:967-72.
9. Hagberg H, Lamberg K, Aström G. Alpha-2b interferon and oral clodronate for Gorham's disease. *Lancet* 1997;350:1822-3.
10. Chattopadhyay P, Bandyopadhyay A, Das S, Kundu AJ. Gorham's disease with spontaneous recovery. *Singapore Med J* 2009;50: e259-63.
11. Handl-Zeller L, Hohenberg G. Radiotherapy of Morbus Gorham-Stout: The biological value of low irradiation dose. *Br J Radiol* 1990;63:206-8.
12. Ohya T, Shibata S, Takeda Y. Massive osteolysis of the maxillofacial bones. Report of two cases. *Oral Surg Oral Med Oral Pathol* 1990;70:698-703.

### Access this article online

Quick Response Code:



Website:

www.sajc.org

DOI:

10.4103/2278-330X.103726

## NEWS

Congratulations to Dr Shailesh Bondarde for conducting a very successful  
ICON ASCO Cancer Research Workshop as well as 27<sup>th</sup> ICON Meeting at Nashik from  
14<sup>th</sup> and 16<sup>th</sup> September 2012

Congratulations to Dr Hemant Malhotra for conducting a very successful  
Best of ASCO Meeting at Jaipur from 22<sup>nd</sup> to 24<sup>th</sup> June 2012