

Sphincter-saving surgeries for rectal cancer: A single center study from Kashmir

Shabeer Ahmed Mir, Nisar A. Chowdri, Fazl Q. Parray, Parvez Ahmed Mir¹, Yasir Bashir², Muntakhab Nafae

Abstract

Summary and Background Data: The goals in the treatment of rectal cancer are cure, local control, and preservation of sphincter, bladder and sexual function. Surgical resection using sharp mesorectal dissection is important for achieving these goals. **Objectives:** The current treatment of choice for carcinoma rectum is sphincter saving procedures, which have practically replaced the previously done abdominoperineal resection. We performed a study in our institute to evaluate the surgical outcome and complications of rectal cancer. **Materials and Methods:** This prospective study included 117 patients, treated for primary rectal cancer by low anterior resection (LAR) from May 2007 to December 2010. All patients underwent standard total mesorectal excision (TME) followed by restoration of continuity. **Results:** The peri-operative mortality rate was 2.5% (3/117). Post-operative complications occurred in 32% of the patients. After a median follow up of 42 months, local recurrences developed in 6 (5%) patients and distant metastasis in 5 (4.2%). The survival rate was 93%. **Conclusion:** The concept of total mesorectal excision (TME), advances in stapling technology and neoadjuvant therapy have made it possible to preserve the anal sphincter in most of the patients. Rectal cancer needs to be managed especially in a specialized unit for better results.

Key words: Carcinoma rectum, sphincter saving procedure, low anterior resection, total mesorectal excision

Introduction

Colorectal cancer is one of the major causes of death worldwide and ranks third in the order.^[1] Surgical resection using sharp mesorectal dissection [Figure 1] is important for achieving cure, with preservation of sphincter and sexual function. The advent of staplers has increased the number of patients being benefitted by sphincter preserving surgery.^[2] Neoadjuvant therapy has also helped in tumor down staging, thereby reducing the number of patients with permanent stoma.^[3] The concept of total mesorectal excision (TME) proposed by Heald has been shown to improve both disease free survival and overall survival.^[4] Rectal cancer is on the rise in the valley of Kashmir, therefore the present study was undertaken with a view to assess the outcome of surgery in patients undergoing low anterior resection (LAR) for carcinoma rectum in this part of the world vis-à-vis rest of the world.

Material and Methods

In a prospective study conducted over a period of three and a half years, 117 patients were enrolled. After proper

approval from the ethics committee, a detailed history and general physical examination and evaluation were carried as per preset proforma. Anemia and poor nutritional status were addressed preoperatively. Diagnosis was confirmed by histopathology after endoscopic biopsy of the lesion. Contrast enhanced computed tomography (CECT) or magnetic resonance imaging (MRI) was done to assess the local status and distant spread of the lesion. Patients with unresectable tumors, distant metastasis, and growth below 4 cms from anal verge were excluded from the study.

Surgical technique

Except in nine patients in whom laparoscopic technique was used, in all other patients surgery was performed by the open method using conventional midline infra umbilical incision. Procedures like anterior resection (AR), i.e., resection of growth was done above the peritoneal reflections, low anterior resection LAR, which is defined as the resection of growth between 4-11 cms from anal verge

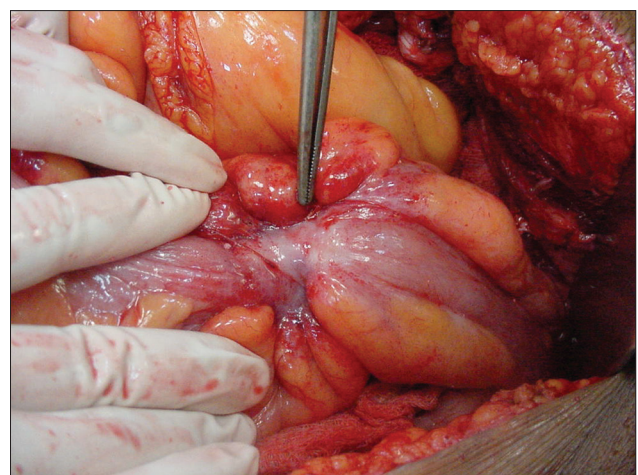


Figure 1: Stenosing rectal growth

Department of General and Minimal Access Surgery, Colorectal Division, ²Internal Medicine, Sheri Kashmir Institute of Medical Sciences, ¹Otorhinolaryngology, SMHS Hospital, Srinagar, Jammu and Kashmir, India

Correspondence to: Dr. Shabeer Ahmad Mir
Email: drshabeerahmad@gmail.com

Access this article online	
Quick Response Code: 	Website: www.sajc.org
	DOI: 10.4103/2278-330X.119929

and ultraLAR, i.e., when the distal margin of resection is less than 4 cms from anal verge, were performed depending upon the level of lesion from the anal verge, using the standard mesorectal excision technique. The gut continuity was restored by the stapling technique. In patients with ultra low anastomosis and those at high risk, a covering ileostomy was done routinely and closed after 812 weeks. Intra-operatively every attempt was made to stick to the oncological principles.

Neoadjuvant therapy was given to those patients with serosal infiltration and/or lymph node involvement. Patients with stage III, stage IV, and some patients with high risk stage II disease received adjuvant therapy. Patients were followed regularly as per standard protocol for results and complications of surgery. Initial follow-up was weekly for the first month, monthly for the next 6 months, and three monthly thereafter. The results were compiled and analyzed statistically using descriptive statistics, Chi-square test, and KaplanMeyer for survival analysis.

Results

Between May 2007 and Dec 2010, there were 117 patients included in the study, with a male:Female ratio of 1.17:1. Thirty-four percent of patients were aged 51-60 years with mean age of 52.1 ± 13.9 . Our youngest patient was 21 years and the oldest 80 years of age [Table 1].

Seventy-one patients had well differentiated adenocarcinoma, 21 had moderately differentiated adenocarcinoma and there were small numbers of patients with other pathologies [Table 2].

Out of 117 patients, 58 (50%) had stage II disease, 42 (36%) stage III, 14 (12%) stage I, and 3 patients had stage IV disease [Table 3]. The neoadjuvant therapy included concurrent radio and chemotherapy (5040 cGy delivered in fractions of 180 cGy per day, 5 days per week) and 5- fluorouracil (120-hour continuous intravenous infusion during the first and fifth weeks). 64 (55%) patients underwent LAR; 30 (25%) patients ultra- LAR and 23 patients (20%) AR [Table 4]. In 22 patients, colonic pouch was reconstructed. Overall 32% patients developed complications [Table 5], most common being urinary retention (10%). These patients were catheterized for 36 weeks but all of them eventually recovered. Eleven patients developed anastomotic leak out of which six patients needed repeat surgery in the form of abscess drainage and covering ileostomy which was closed after 1220 weeks. Three patients recovered after conservative treatment but two patients succumbed to disseminated sepsis. In addition 4 patients developed radiation enteritis due to radiotherapy.

The follow up period ranged from 360 months with a median follow up of 42 months.

One-hundred and twelve (96%) patients were continent and satisfied with their bowel frequency at 42 months of median follow-up. Three (2.5%) patients were incontinent to flatus and two (1.7%) had partial incontinence to liquid feces. Ninety-four (81%) patients including 20 patients

with colonic J-pouch had 1-3 motions per day; rest had 4-6 motions per day but stools eventually decreased to 2-4 per day after about 6 months. Three patients in our study developed sexual problems in the form of erectile dysfunction which was ascertained by using international index of erectile function questionnaire (IIEF).

Eleven patients developed recurrence at an average follow-up period of 42 months. Six patients developed local recurrence, three liver metastasis, and two patients developed multiple organ metastases (liver, lung and brain). In three patients repeat LAR was attempted, two underwent abdominoperineal resection (APR), and in one only diverting colostomy could be performed. Nine (7.6%) patients died, three in the immediate post-operative period, one because of pulmonary thromboembolism, and the other two due to post-operative sepsis. Three died during chemotherapy due to sepsis and the other three due to distant metastases, out of which two had liver metastases

Table 1: Age and gender distribution of the studied subjects

Age (yr)	Male n %	Female n %	Total n %	P value
21 to 30	7 (11.00)	5 (9.25)	12 (10.25)	0.996 (ns)
31 to 40	10 (15.8)	7 (12.96)	17 (14.52)	
41 to 50	14 (22.22)	9 (16.6)	23 (19.65)	
51 to 60	21 (33.33)	19 (35.18)	40 (34.18)	
>60	11 (17.46)	14 (25.9)	25 (21.36)	
Total	63 (54.0)	54 (46.0)	117 (100)	

Table 2: Histopathology of the studied patients

HPE	n (%)
Well differentiated adenocarcinoma	74 (63.24)
Moderately differentiated adenocarcinoma	24 (20.51)
Signet Cell adenocarcinoma	4 (3.41)
Poorly differentiated adenocarcinoma	3 (2.56)
Villous adenocarcinoma	3 (2.56)
Mucinous adenocarcinoma	2 (1.70)
Papillary adenocarcinoma	2 (1.70)
Squamous cell carcinoma	2 (1.70)
Carcinoma in SITU	2 (1.70)

HPE=Histopathological examination

Table 3: Stage wise distribution of patients

Stage	n (%)
I	9 (7.69.53)
II	59 (50.42)
III	42 (35.89)
IV	7 (5.9)

Table 4: Procedure in the studied patients (n=50)

Procedure	n (%)
Ultra low anterior resection	30 (25.0)
Low anterior resection	64 (55.0)
Anterior resection	23 (20.0)

pre-operatively and were down staged by neo-adjuvant therapy, i.e., concurrent chemo and radio therapy (5040 cGy delivered in fractions of 180 cGy per day, 5 days per week) and 5- fluorouracil (120-hour continuous intravenous infusion during the first and fifth weeks)

All patients with stage I, 95% with stage II, 90% (38/42) with stage III, and only one out of three (33%) with stage IV disease were alive at a median follow up of 42 months.

According to histology well differentiated, moderately differentiated and poorly differentiated adenocarcinoma had survival of 96.3, 89, and 50%, respectively [Table 6].

Discussion

In the treatment of carcinoma of mid and distal rectum, LAR is the mainstay of sphincter preserving-operations. Technical difficulties in patients, who otherwise deserve sphincter-preserving operations, have previously resulted in the use of pull-through procedures in approximately 10% of cases.^[5] All these operations involve either significant distortion of the distal rectal segment in order to achieve a primary anastomosis or, alternatively, healing by secondary intention. Both of these circumstances lead to frequent stricture or incontinence, except when the operation is performed by very experienced surgeons.^[6] In contrast to the pull-through operations, coloanal or low colorectal reconstruction is a primary end-to-end anastomosis that can be performed with a minimum of anal manipulation and sensory disturbance. Although the risk of pelvic sepsis is lower in this operation than after LAR, a safe period of complete healing is essential to ensure good function. This is best achieved by complete fecal diversion. It is unreasonable to expect normal continence and anorectal function in the immediate post-operative period and long-term functional results are dependent upon the absence of pelvic fibrosis, i.e., healing without sepsis, or hemorrhage. The factors associated with difficulty in sphincter preservation are male sex, morbid obesity, preoperative incontinence, direct involvement of anal sphincter muscles with carcinoma, and bulky tumor within 5 cms from anal verge.^[7]

Results of coloanal anastomosis have varied with individual reports. Killing back has reported on 43 cases of coloanal anastomosis, representing 12% of 350 cases of rectal cancer.^[8] He reported an operative mortality of 2.3% due to pelvic sepsis. In contrast to our results, at least one-half of his patients wore a pad and were incontinent for flatus. While some patients had only one bowel movement per day, others were vulnerable to “unpredictable bouts of frequency.”

The main post-operative complication in our patients was urinary retention (10%) which is about half as compared to that reported by Enker (19.5%).^[9] He also reported a major anastomotic leak rate of 5% compared to 10% in our study. Burt Cagir has reported a urinary dysfunction secondary to weakening of detrusor muscle in 35% patients.^[7] In our study, three patients (2.5%) developed impotence due to

erectile dysfunction, which in the past has been reported to occur in 570% of men, but recent reports indicate that the current incidence is lower.^[10]

Localio reported 14 deaths after 646 operations yielding an overall mortality rate of 2.2%.^[11] There were nine deaths (7.6%) post-operatively in our series. A total of 4% mortality rate has been reported after coloanal anastomosis (CAA) by Nicholls.^[12]

Shrikhande has reported an overall complication rate of 11.6% (16/138), including five anastomotic leaks, five wound infections, five sunken stomas, and one adhesive intestinal obstruction.^[13] There was one case of death in his study.

The anastomotic leak reported by Baren *et al.* was 2.7%, Moran *et al.* 9%, Redmond *et al.* 2.8%, Laxamana *et al.* 7.3%, and Kanellos *et al.* 9.7%.^[14-19] It was 9.4% in our study [Table 7]. So in other series the rate of anastomotic leak ranges from 2.7 to 9.7%. No routine radiological examination was made and only symptomatic leaks were taken in to account. The rate of anastomotic leak after LAR is usually 9% except for Localio *et al.* who reported a rate of 1%.^[11,20,24] The risk of leak does not seem to be reduced

Table 5: Complications

Complications	n (%)
Wound sepsis	5 (4.0)
Anastomotic leak	11 (10.0)
Urinary retention	11 (10.0)
Incontinence	5 (4.0)
Erectile dysfunction	3 (2.5)
Stricture	2 (1.7)

Table 6: Outcome w. r. t. Stage and HPE

	Surviving n (%)	Died n (%)
Stage		
I	20 (100.0)	
II	49 (95.0)	3 (5.0)
III	38 (90.0)	4 (10.0)
IV	1 (33.0)	2 (66.6)
Total	108 (92.0)	9 (8.0)
HPE		
Well differentiated adenocarcinoma	53 (96.3)	2 (3.7)
Moderately differentiated adenocarcinoma	30 (89.0)	4 (11.0)
Poorly differentiated adenocarcinoma	14 (50.0)	14 (50.0)

Table 7: Comparison of anastomotic leak rates

Study	Year	No. of patients	Leak rates %
Baren <i>et al.</i>	1992	104	2.7
Moran <i>et al.</i>	1992	55	9.0
Redmond <i>et al.</i>	1993	111	2.8
Laxamana <i>et al.</i>	1995	189	7.3
Kanellos <i>et al.</i>	2004	93	9.7
Our study	2007-2010	117	9.4

when stapled anastomosis is performed.^[5] The percentage leak in our patients was comparable to other series.^[9] In our study one patient developed peritonitis. None of our patients with leak led to permanent functional failure.

Functional results of our study were comparable to other studies.^[11,12,26-28] Enker reported that nine to twelve months after colostomy closure, 64% of all patients had complete continence and normal bowel habits, with only minor disturbances in anorectal function. Nineteen patients (86%) were completely continent with normal or near normal bowel function.^[9] In our study, 8 out of 15 patients who were incontinent after surgery, had improved function at 1 year of mean follow up. This might be because of reappearance of recto-anal inhibitory reflex.^[2,9] The number of stool motions per day in 95 patients were 1-3 and in rest >4. The former group included 20 patients with colonic J- pouch formation. Two patients with J-pouch had difficulty with stool evacuation which needed laxatives and enemas. Our results are comparable to the study by Rouanet in which the stool frequency ranged from 1 every 2 days to 6 daily, with a mean stool frequency of 1.6, depending on the type of surgery performed i.e., one daily stool or constipation after colonic pouch and 24 daily stools after straight coloanal anastomosis.^[30]

Six of our patients developed local recurrence which was much less than seen with other series e.g., 14.6% in study by Localio^[26] and 13% in study by Nicholls.^[12] The possible explanation is the shorter follow up. Prognosis also seems to be related to TNM stage, histopathology, and surgical procedure.^[8,9,21]

It may be pertinent to mention here that our department had admitted and treated only 75 patients of carcinoma rectum from May 2004 to Apr 2007 compared to 117 patients during the next three and half years spanning from May 2007 to December 2010, thus we are seeing an increased number of rectal cancer patients in our hospital.

Conclusion

The concepts of TME, advances in stapling technology and neoadjuvant therapy have made it possible to preserve anal sphincter in most patients, however emphasis should also be laid on preoperative staging, patient selection, procedure type, adherence to surgical oncological principles, and a meticulous follow up. Rectal cancer should be managed in a specialized unit for better results. Improved surgical techniques have improved the results in terms of survival and local recurrence and have brought down the complication rate to an acceptable level. Functional outcome in terms of bowel continence and frequency improves with passage of time and most of the patients do very well after a phase of adaptation even in LARs.

References

- American Cancer Society (2011). Cancer Facts and Figures 2011. Atlanta, GA: American Cancer Society; 2011.
- Sato H, Malsumoto M, Aoyama H. Modified double stapling technique in Low Ant. Resection for low rectal carcinoma. *J Surg Today* 2006;36:30-6.
- Vauthey JN, Marsh RW, Zlotecki RA, Abdalla EK, Solorzano CC, Bray EJ, *et al.* Recent advances in the treatment and outcome of locally advanced rectal cancer. *Ann Surg* 1999;228:745-54.
- Heald RJ, Moran BJ, Ryall RD, Sexton R, MacFarlane JK. Rectal cancer. The Basingstoke experience of total mesorectal excision 1978-1997. *Arch Surg* 1998;133:894-9.
- Stearns MW Jr. The choice among anterior resection, the pull-through, and abdominoperineal resection of the rectum. *Cancer* 1974;34:969-71.
- Kirwan WO, Turnbull RB Jr, Fazio VW, Weakly FL. Pull-through operation with delayed anastomosis for rectal cancer. *Br J Surg* 1978;65:695-8.
- Cagir B, Harris JE, Douglas RT. Rectal cancer treatment and management. Nov 11, 2011.
- Killingback MK. Quoted by Mc Dermott FT. carcinoma of the rectum. In: Hughes ES, Cuthbertson AM, Killingback MK, editors. *Colorectal surgery*. Melbourne: Churchill Livingstone; 1983. p. 377-9
- Enker WE, Stearns MW, Janov AL. Peranal coloanal anastomosis following low anterior resection for rectal carcinoma discolor rectum 1985;28:575-81.
- van Helmond J, Beart RW. Cancer of the rectum: Operative management and adjuvant therapy. In: *Current Therapy in Colon and Rectal Surgery*. 2nd ed. Philadelphia, Pa: Mosby; 2005.
- Localio-Mummery HE, Coppa GF. Abdominosacral resection for midrectal cancer. *Ann Surg* 1983;198:320-4.
- Nicholls RJ, Ritchie JK, Wadsworth J, Parks AG. Total excision or restorative resection for carcinoma of middle third of rectum *Br J Surg* 1979;66:625-7.
- Shrikhande SV, Saoji RR, Barreto SG, Kakade AC, Waterford SD, Ahire SB, *et al.* Outcomes of resection for rectal cancer in India: The impact of the double stapling technique. *World J Surg Oncol* 2007;5:35.
- Goligher JC. Current trends in use of sphincter saving excision in the treatment of carcinoma of the rectum. *Cancer* 1982;50:2627-30.
- Baran JJ, Goldstein SD, Resnik AM. The double-stapling technique in colorectal anastomosis. *Am Surg* 1992;58:270-2.
- Moran BJ, Blenkinsop J, Finnis D. Local recurrence after anterior resection for rectal cancer using a double stapling technique. *Br J Surg* 1992;79:836-8.
- Redmond HP, Austin OM, Clery AP, Deasy JM. Safety of double-stapled anastomosis in low anterior resection. *Br J Surg* 1993;80:924-7.
- Laxamana A, Solomon MJ, Cohen Z, Feinberg SM, Stern HS, McLeod RS. Long-term results of anterior resection using the double-stapling technique. *Dis Colon Rectum* 1995;38:1246-50.
- Kanellos I, Vasilidis K, Angelopoulos S, Tsachalis T, Pramateftakis MG, Mantzoros I, *et al.* Anastomotic leakage following anterior resection for rectal cancer. *Tech Coloproctol* 2004;8(Suppl 1):s79-81.
- Lockhart-Mummery HE, Ritchie JK, Hawley PR. The results of surgical treatment for carcinoma of rectum at St. Marks Hospital from 1948 to 1972. *Br J Surg* 1976;63:673-7.
- Waugh JM, Block MA, Gage RP. Three and five year survivals following combined abdominoperineal resection, abdominoperineal resection with sphincter preservation and anterior resection for carcinoma of the rectum and lower part of sigmoid colon. *Ann Surg* 1955;142:752-7.
- Waugh JM, Turner JC. A study of 268 patients with carcinoma of middle rectum treated by abdominoperineal resection with sphincter preservation. *Surg Gynecol Obstet* 1958;102:777-83.
- Wilson SM, Beahrs OH. The curative treatment of carcinoma of the sigmoid, rectosigmoid and rectum. *Ann Surg* 1976;181:556-65.
- Williams NS, Johnston D. Survival and recurrence after sphincter saving resection and abdominoperineal resection for carcinoma of the middle third of rectum. *Br J Surg* 1984;71:278-82.
- Goligher JC. Use of circular stapling gun with peranal insertion of anorectal purse-string suture for construction of very low colorectal or coloanal anastomosis. *Br J Surg* 1979;66:501-4.
- Localio A, Eng K. Sphincter-saving operations for cancer of the

- rectum. N Engl J Med 1979;300:1028-30.
27. Nicholls RJ. Rectal cancer: Anterior resection with per anal coloanal anastomosis. Bull Cancer 1983;70:304-7.
 28. Parks AG, Percy JP. Rectal carcinoma: Restorative resection using a sutured colo-anal anastomosis. Int Surg 1983;68:7-11.
 29. Suzuki H, Mutsumoto K, Fujioka M, Honzumi M. Anorectal pressure and rectal compliance after low anterior resection. Br J Surg 1980; 67:655-7.
 30. Rouanet P, Fabre JM, Dubois JB, Dravet F, Saint Aubert B, Pradel J,

et al. Conservative surgery for low rectal carcinoma after high dose radiation-functional and oncological results. Ann Surg 1995; 221:67-73.

How to cite this article: Mir SA, Chowdri NA, Parray FQ, Mir PA, Bashir Y, Nafae M. Sphincter-saving surgeries for rectal cancer: A single center study from Kashmir. South Asian J Cancer 2013;2:227-31.
Source of Support: Nil. **Conflict of Interest:** None declared.

News

**8th SAARC Federation of Oncology (SFO) Conference
13th to 15th December 2013
Kathmandu, Nepal**

Abstract submission deadline is October 30th 2013.

For further details please:

visit: www.sfon.org.np

Contact: saghimire@hotmail.com

Dr. Sarita Ghimire

General Secretary, Conference organising committee