

Simultaneous integrated boost with intensity modulated radiation therapy in brain oligometastases: A feasible technique for developing countries

Vivek Tiwari, Subodh C. Pande, Kamal Verma, Sandeep Goel

Abstract

Introduction: To analyze the pattern of brain metastasis (BM), and to use intensity modulated radiation therapy (IMRT) for target dose escalation in cases with ≤ 3 metastatic lesions (oligometastases). **Materials and Methods:** Thirty-two consecutive cases of BM treated during September 2009 to August 2012 were analyzed retrospectively. **Results:** The study comprised 13 males (40.62%) and 19 females (59.37%). Thirteen (40%) patients presented with disseminated intracranial metastases, while 19 (60%) had ≤ 3 foci. In 25 cases (78%), the primary was located either in the breast (14 cases) or lung (11 cases). The 13 patients with disseminated intracranial metastases received whole brain radiation therapy to a dose of 30 Gy/10-12 daily fractions (Group A) while the 19 cases with ≤ 3 lesions received an additional dose of 6-10 Gy to gross lesions using a simultaneous integrated boost (SIB) with IMRT thus receiving a total dose of 36-40 Gy/12-15 fractions (Group B). Overall survival (OS) for the breast primary was 6.3 and lung primary was 5.3 months, respectively. The mean OS for breast cases in Group B was higher (9.5 months) as compared to Group A cases (1.9 months) and was statistically significant ($P = 0.0056$). Similarly, primary lung cancer cases in Group B showed a mean OS of 8.75 months versus 2.6 months for Group A cases ($P = 0.213$). **Conclusions:** IMRT is a safe and effective technique in cases with oligometastases for dose escalation in the form of SIB.

Key words: Intensity modulated radiation therapy, oligometastases, simultaneous integrated boost

Introduction

Brain metastases (BM) account for 10-40% of all cancer cases and display a rising trend owing to the advancements in imaging techniques and systemic therapy along with increased longevity of cancer.^[1] BM are associated with a median survival of 2.3-13.5 months depending upon factors such as age and functional status of the patient, extent of systemic disease, and the number of metastases.^[1,2] Majority of BM originate from primary cancers located in the lung (40-50%) and breast (20-30%) followed by melanoma, lymphoma, gastrointestinal cancers, etc.^[3] The vast majority (70-80%) of these patients have 1-3 metastases (oligometastases) with more than three metastases seen in only 20-30% of the patients.^[4] Disseminated BM are usually treated with whole brain radiation therapy (WBRT) along with steroids, while those with < 3 metastatic lesions (oligometastases) are considered for surgery and/or radiosurgery with or without WBRT.^[5] A variety of fractionation schedules have been tried for WBRT, and have demonstrated a median survival of about 4-7 months.^[1,2] Use of higher dose schedules to further augment survival has remained restricted because of quality-of-life (QOL) considerations and is generally recommended for select patients of younger age, higher performance status (PS) and without detectable primary or extra cranial disease.^[5] Trials with enhanced dose to limited metastatic foci using WBRT in conjunction with stereotactic radiosurgery (SRS) for patients with oligometastases have shown improved time to local failure and higher survival compared with WBRT alone without adversely affecting PS.^[6,7] As an alternative to SRS, dose augmentation using conformational fractionated external beam RT “boost” to individual intracranial foci of BM from lung cancer has recently been shown in a multi-institutional study to result in a remarkable estimated 1 year local control rate of $> 75\%$.^[8] Such dose escalation can also be undertaken with intensity modulated radiotherapy (IMRT) using the simultaneous

integrated boost (SIB) technique^[9] in a linear accelerator (LA) that has the potential to deliver differential therapeutic dose levels to multiple target volumes while affording safety to organs at risk within a single treatment session. The present communication is aimed at analyzing the feasibility of using IMRT based SIB for target dose escalation in a select group of cases with oligometastases to achieve improved outcome. Such an approach may be important in the setting of developing countries that have constrained infrastructure and cater to a large number of patients.

Materials and Methods

During the period of month from September 2009 to August 2012, 32 consecutive cases of BM arising from various primary sites that were treated in our department were analyzed retrospectively. All patients had received standard therapy for a biopsy proven primary cancer and had clinical and radiological evidence of BM. These patients were evaluated and found eligible for palliative radiotherapy. As part of the pretherapy planning, all patients were subjected to a contrast magnetic resonance (MR) scan in addition to the treatment planning computerized tomography scan and both were fused on the Tomocon® workstation (ELEKTA™) to allow optimum delineation of the relevant planning volumes. Patients with disseminated metastases were treated with WBRT using two parallel and opposing fields to a dose of 30 Gy in 10-12 daily fractions (Group A) while those with ≤ 3 metastatic lesions were subjected to IMRT planning for WBRT with incorporation of a “boost” dose of 6-10 Gy to the gross metastatic lesions delivered as a SIB thus taking the total dose to 36-40 Gy in 12-15 fractions (Group B) [Figure 1]. The primary end point of response to radiotherapy was overall survival (OS) and the response was based on the follow-up MR appearances of the metastatic lesions and was divided into three categories: (i) Progressive disease (PD) denoting increase in the number or in contrast enhancement of the original lesions; (ii) stable disease (SD) that signified no apparent change in either the number or enhancement characteristics; (iii) excellent response (ER) that reflected both, reduction in number and/or enhancement pattern.

The results were interpreted by online *t*-test calculator (GraphPad software, QuickCalcs) using unpaired *t*-test. $P < 0.05$ was considered statistically significant.

Access this article online

Quick Response Code:



Website: www.sajc.org

DOI: 10.4103/2278-330X.149927

Department of Radiation Oncology, Artemis Health Institute, Gurgaon, Haryana, India

Correspondence to: Dr. Vivek Tiwari,
E-mail: dr_vivektiwari@rediffmail.com

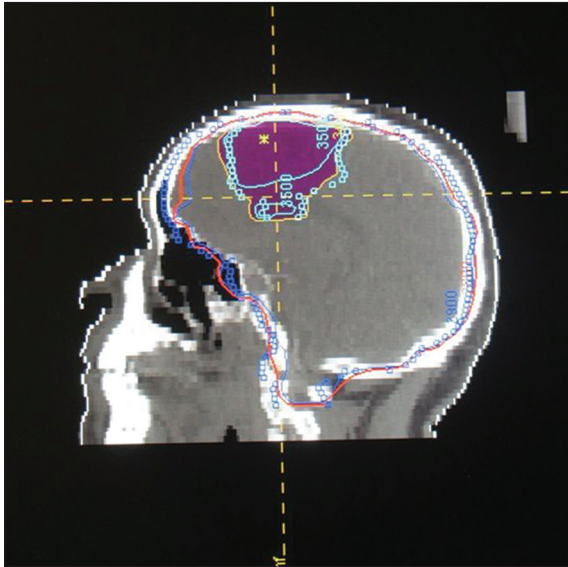


Figure 1: Dose distribution

Results

Patient characteristics

This study includes 32 patients with BM arising from multiple primary sites. Of these, 13 (40.62%) were males and 19 (59.37%) were females. The total number of patients analyzed was 29 [Table 1].

Tumor characteristics

In 25 (78%) cases, the primary was located in either breast (14 cases) or lung (11 cases). There was one case each (3.12%) with primary diagnosis of malignant melanoma, nonHodgkin’s lymphoma, carcinoma colon, carcinoma urinary bladder, hepatocellular carcinoma, carcinoma ovary, and neuroendocrine carcinoma of the prostate. Thirteen (40%) patients had disseminated intracranial lesions, 19 (60%) had ≤3 lesions of which 9 (47%) were solitary. The overall mean interval between diagnosis of the primary and presentation of BM was 27.81 months (range: 0-140 months), which was 50.9 months (range: 8-140 months) for breast primary and 3.8 months (range: 0-26 months) for the lung primary cases.

Treatment characteristics

Group A patients (n = 12) received a WBRT dose to 30 Gy/10-12 fractions while Group B patients (n = 17) received an additional SIB of 6-10 Gy to a total dose of 36-40 Gy/12-15 fractions using IMRT. Three (9.4%) patients did not complete the prescribed treatment, and were not taken into consideration for comparison of doses and outcomes [Table 2].

Response assessment

Of the 29 patients completing the prescribed treatment, 11 (38%) patients showed SD, 17 (58.62%) showed ER, while 1 (3.44%) patient had a PD.

Of the 12 patients in Group A, 9 (75%) patients had a SD and 3 (25%) had an ER at a mean follow-up period (post-RT completion) of 1.91 months (range: 0-8 months), whereas in Group B, 14 (82%) patients achieved ER, 2 (11.76%) achieved SD, while 1 (5.9%) patient had a PD at a mean follow-up period of 7.36 months (range: 0-23 months).

Survival

The mean OS for the 29 cases that completed the planned treatment was 5.62 months (range: 0-23 months). These included

Table 1: Patient characteristics

Patient characteristics	n	Percentage
Age (years)		
<50	6	18.75
50-69	21	65.63
>69	5	15.63
Mean age Group A patients	58.38 (range:33-75) years	
Mean age Group B patients	60.88 (range:39-76) years	
Gender		
Male	13	40.62
Female	19	59.37
	Pre-RT	Post-RT
Median KPS		
Group A	80	80
Group B	90	90
Primary		
Breast	14	43.75
Lung	11	34.375
Others	7	21.875
Type of metastasis		
Solitary	9	28.12
Oligo	10	31.25
Multiple	13	14.62
	Group A	Group B
Primary+brain metastases	5	6
Primary+brain+extra cranial metastases	7	11

KPS=Karnofsky performance status, RT=Radiation therapy

Table 2: Treatment characteristics

Treatment characteristics	n	Percentage
Group A	12	37.5
Group B	17	53.12
Treatment dropouts	3	9.37
Treatment response	Group A	Group B
ER	3	14
SD	9	2
PD	0	1

ER=Excellent response, SD=Stable disease, PD=Progressive disease

14 cases with breast and 11 with lung primaries, the OS for which was 6.3 months (range: 0-17 months) and 5.3 months (range: 1-23 months) respectively. The mean OS in the breast cases treated with additional IMRT boost (n = 8) was 9.5 months (range: 0-17 months), while those treated only with WBRT (n = 5) was 1 (where is the one last case for breast making n to 14) months (range: 0-2 months) and was statistically significant using unpaired t-test (P = 0.0056, t = 3.4288) [Table 3 and 4].

The mean OS in the lung cases treated with additional IMRT boost (n = 4) was 8.75 months (range: 2-23 months), while those treated only with WBRT (n = 5) was 2.6 months (range: 1-8 months) and was not found to be statistically significant using unpaired t-test (P = 0.2133, t = 1.3690).

The 13 cases with primary breast cancer had a mean OS of 6.3 months while the 9 cases with primary lung had a mean OS of 5.3 months. Breast cases in Group B had a significantly better survival than those in Group A (9.5 months vs. 1.0 month). Similarly, primary lung cancer cases in Group B showed a mean OS of 8.75 months versus 2.6 months for Group A cases (P < 0.213).

Table 3: Survival

	<i>n</i>	Survival (months)	Range (months)
Overall	29	5.62	0-23
Breast cases	14	6.3	0-17
Lung cases	11	5.3	1-23
Group A	12	1.8	
Group B	17	9.3	
Group A (breast)		1	0-2
Group A (lung)		2.6	1-8
Group B (breast)		9.5	0-17
Group B (lung)		8.75	2-23

Table 4: Statistical comparison between Groups A and B for primary breast and lung

	Breast		Lung	
	Group A	Group B	Group A	Group B
<i>n</i>	5	8	5	4
<i>P</i> value	0.0056		0.2133	
95% CI	-13.96 to -3.04		-16.77 to 4.47	
<i>T</i>	3.4288		1.3690	
Degrees of freedom	11		7	
SED	2.479		4.492	
SD	1	5.40	3.05	9.60
SEM	0.45	1.91	1.36	4.80

CI=Confidence interval, SD=Standard deviation, SEM=Standard error of the mean, SED=Standard error of the difference

Performance status

The median Karnofsky performance status (KPS) for Groups A and B was 80 and 90 respectively pretreatment, and was well-maintained and preserved posttreatment as well.

Discussion

In our study, we observed a long time lag (mean: 50.9 months) in cases of breast primary to present with BM while those with a lung primary had a comparatively shorter time lag (mean: 3.8 months).

Brain metastasis is the most common intracranial tumor with a rising incidence the source for which is varied and its therapy is restricted. The management options for selected patients with BM include steroids (to treat brain edema), anticonvulsants (to treat seizures), surgery (for limited lesion BM), WBRT, SRS, either alone or in combination. Survival, local control, overall symptomatic control, and neurocognitive outcomes should influence management decisions.^[10] WBRT alone is the modality of choice in patients who have multiple BM or lesions that are too large, numerous, or inaccessible for surgery or SRS.^[11] WBRT is effective for palliation of symptoms of BM and may result in 30-100% of 1 year local failure.^[7]

Since progression of BM adversely impacts on neurocognitive function and QOL, there is ample justification for improving local control using avenues for selective dose escalation of gross metastatic lesions.^[8] There are evidences to suggest an advantage in terms of local control with the addition of additional dose to the WBRT as suggested by various studies, especially in oligometastases.^[12-14] The possible reasons may include a complex tumor biology varying with different primary, the pattern and time of presentation of the BM during the course of the disease.

Improvement of local control of BM may not necessarily lead to improved survival, but is of paramount importance

to maintain neurological function and may be a worthwhile objective, especially in subsets of patients with a better prognosis that includes younger age, good PS, controlled primary tumor, absence of extra cranial disease and/or limited number of BM who might benefit from dose escalation.^[5]

Stereotactic radiosurgery has an established role for treating selected patients with single or multiple BM, with local tumor control rates at 1 year of around 80% and with median survival of 6-12 months.^[15] SRS may replace conventional surgery for single BM without major mass effect. However, by its focal nature, SRS does not prevent relapse at other sites within the brain, which is very common in many cancers.^[15] The RTOG 9508 randomized trial has demonstrated that the addition of SRS to WBRT significantly increases median survival from 4.9-6.9 months for oligometastases and favorable KPS,^[6] but at the same time entails prolongation of treatment time. The treatment is typically biphasic, Phase 1 for WBRT followed by re planning and implementation of SRS in Phase 2. In addition, SRS has major cost implications and bearing in mind that such therapy is palliative, must therefore be under scrutiny for rationing.^[15]

These two factors are of major concern in developing countries where the facilities and resources are limited and the infrastructure, more often than not is overburdened with a large number of patients requiring specialized care. Many countries of low or middle income, notably in the Asia-Pacific region, have limited access to radiotherapy.^[16] Given such a scenario, stereotactic RT utilizing a LA is suggested as a safe and effective approach for RT to brain provided the dose-volume-time relationship is well-controlled.^[17] With modern IMRT technology, higher dose concomitant dose boosts to oligo BM could provide the advantages of SRS during WBRT and obviate the need for the extra procedure and associated cost factors.

Simultaneous integrated boost using IMRT is a comparatively simple technique that can be undertaken in most modern LA and involves less complexity compared with SRS. The use of SIB moreover entails reduced treatment duration as it can be incorporated within the WBRT schedule and cuts down the treatment time.

Conclusion

Dose escalation in BM is of value for a better local control and an improved survival as demonstrated in our analysis. Thirteen patients (76%) out of 17 in Group B demonstrated clinic-radiologic control of the BM. Although not analyzed, there was also a significant improvement in terms of steroid dependence. We propose that patients with oligo BM may benefit with the time sparing radiation delivery using SIB providing a clinically relevant brain control of metastatic disease and less need for recourse for later SRS, both being of benefit to the patient and reducing the overall costs of treatment that is of particular relevance in developing countries.

Though limited by a small number of patients included, our analysis shows that SIB-IMRT with the dose/fractionation used in this study is feasible and safe, with a survival outcome similar to the historical control. The shortening of treatment time by using SIB-IMRT may be of value, although further investigation is warranted to prove its survival advantage.

References

1. Ellis TL, Neal MT, Chan MD. The role of surgery, radiosurgery and whole brain radiation therapy in the management of patients with metastatic brain tumors. *Int J Surg Oncol* 2012;2012:952345.
2. Norden AD, Wen PY, Kesari S. Brain metastases. *Curr Opin Neurol* 2005;18:654-61.
3. Rahmathulla G, Toms SA, Weil RJ. The molecular biology of brain metastasis. *J Oncol* 2012;2012:723541.
4. Gupta T. Stereotactic radiosurgery for brain oligometastases: Good for some, better for all? *Ann Oncol* 2005;16:1749-54.
5. Weber DC, Caparrotti F, Laouiti M, Malek K. Simultaneous in-field boost for patients with 1 to 4 brain metastasis/es treated with volumetric modulated arc therapy: A prospective study on quality-of-life. *Radiat Oncol* 2011;6:79.
6. Kondziolka D, Patel A, Lunsford LD, Kassam A, Flickinger JC. Stereotactic radiosurgery plus whole brain radiotherapy versus radiotherapy alone for patients with multiple brain metastases. *Int J Radiat Oncol Biol Phys* 1999;45:427-34.
7. Andrews DW, Scott CB, Sperduto PW, Flanders AE, Gaspar LE, Schell MC, *et al.* Whole brain radiation therapy with or without stereotactic radiosurgery boost for patients with one to three brain metastases: Phase III results of the RTOG 9508 randomised trial. *Lancet* 2004;363:1665-72.
8. Casanova N, Mazouni Z, Bieri S, Combescure C, Pica A, Weber DC. Whole brain radiotherapy with a conformational external beam radiation boost for lung cancer patients with 1-3 brain metastasis: A multi institutional study. *Radiat Oncol* 2010;5:13.
9. Bruzzaniti V, Abate A, Pedrini M, Benassi M, Strigari L. IsoBED: A tool for automatic calculation of biologically equivalent fractionation schedules in radiotherapy using IMRT with a simultaneous integrated boost (SIB) technique. *J Exp Clin Cancer Res* 2011;30:52.
10. Tsao MN, Khuntia D, Mehta MP. Brain metastases: What's new with an old problem? *Curr Opin Support Palliat Care* 2012;6:85-90.
11. Khuntia D, Brown P, Li J, Mehta MP. Whole-brain radiotherapy in the management of brain metastasis. *J Clin Oncol* 2006;24:1295-304.
12. Assouline A, Levy A, Chargari C, Lamproglou I, Mazon JJ, Krzisch C. Whole brain radiotherapy: Prognostic factors and results of a radiation boost delivered through a conventional linear accelerator. *Radiother Oncol* 2011;99:214-7.
13. Akhtar MS, Kousar F, Fatmi S, Jabeen K, Akhtar K. Quality of life and symptoms control in brain metastasis after palliative whole brain radiotherapy using two different protocols. *J Coll Physicians Surg Pak* 2012;22:311-6.
14. Rades D, Kueter JD, Gliemroth J, Veninga T, Pluemer A, Schild SE. Resection plus whole-brain irradiation versus resection plus whole-brain irradiation plus boost for the treatment of single brain metastasis. *Strahlenther Onkol* 2012;188:143-7.
15. Edwards AA, Kegg E, Plowman PN. The developing role for intensity-modulated radiation therapy (IMRT) in the non-surgical treatment of brain metastases. *Br J Radiol* 2010;83:133-6.
16. Barton MB, Frommer M, Shafiq J. Role of radiotherapy in cancer control in low-income and middle-income countries. *Lancet Oncol* 2006;7:584-95.
17. Shirato H, Isu T, Shimizu Y, Nishioka T, Nonaka M, Abe S, *et al.* Prospective dose-escalation study in stereotactic radiotherapy utilizing a linear accelerator: Report from East Hokkaido Radiosurgery Study Group (EHRSSG). *No Shinkei Geka* 1993;21:1089-95.

How to cite this article: Tiwari V, Pande SC, Verma K, Goel S. Simultaneous integrated boost with intensity modulated radiation therapy in brain oligometastases: A feasible technique for developing countries. *South Asian J Cancer* 2015;4:11-4.

Source of Support: Nil. **Conflict of Interest:** None declared.