

# Impact of changing trends of treatment on outcome of cerebral gliosarcoma: A tertiary care centre experience

Narendra Kumar, Tapesh Bhattacharyya, Karan Chanchalani, Praveen Shalunke<sup>1</sup>, B D Radotra<sup>2</sup>, Budhi Singh Yadav

## Abstract

**Aim:** To assess clinicopathological features and outcomes in patients of primary gliosarcoma with changing trends of treatment. **Materials and Methods:** Medical records were reviewed and data collected on primary gliosarcoma over a 5-year period (2009–2013) from the departmental case files. **Results:** A total 27 patients were included in this study. The median age of presentation was 54 years. There was a slight male preponderance, with male to female ratio of 1.25:1. The most common location of the tumor was temporal lobe (44.4%). Gross total resection was possible in 19 cases, near total excision was done in five cases, and only partial excision with decompression in three cases. Of the 27 patients, 80.8% patients received post-operative radical external beam radiotherapy of 60 Gy/30#/6 weeks. Concurrent and adjuvant temozolomide was used in 42.3% cases, depending on affordability and tolerance. Median overall survival was 9 months. On subgroup analysis, median overall survival in the radiotherapy plus temozolomide group was 10 months as compared to 9 months in the radiotherapy alone group; however, this was not statistically significant ( $P = 0.244$ ). **Conclusion:** Treating Gliosarcoma is a major therapeutic challenge for a clinician because of its poor prognosis, aggressive clinical behavior, rarity, and limited clinical experience. With surgery and concurrent chemoradiation, we were able to achieve a median overall survival of 9 months. Addition of temozolomide has shown a better trend in survival though it is not statistically significant.

**Key words:** Gliosarcoma, radiotherapy, temozolomide

## Introduction

Gliosarcoma is a rare but distinct clinicopathological entity in the classification of central nervous system tumors and constitutes approximately 2% of all the malignant glial neoplasms.<sup>[1]</sup> It is considered as a grade IV neoplasm and classified as a variant of glioblastoma multiforme (GBM) in the revised 2007 WHO classification.<sup>[2]</sup> Gliosarcoma was first reported by Heinrich Strobe in 1895 as a brain tumor consisting of both glial and mesenchymal components.<sup>[3]</sup> Malignant astrocytes constitute the majority of the glial component in gliosarcomas; however, oligodendroglial components have also been described. Typically sarcomatous components resemble fibrosarcoma or malignant fibrous histiocytoma. The purpose of this study is to evaluate retrospectively the clinicopathological features and treatment outcomes in patients of primary gliosarcoma.

## Materials and Methods

Medical records of patients registered over a 5-year period (2009-2013) in the Regional Cancer Centre, PGIMER, Chandigarh, were retrospectively analyzed, and data was collected on primary gliosarcomas. Treatment outcomes were analyzed using SPSS version 18.

## Results

### Patient characteristics

Twenty-seven patients were included in this study, the characteristics of whom are presented. Median age at diagnosis was 54 years (range, 9-69 years), with a male predominance (male to female ratio, 1.25:1). Most patients presented with signs and symptoms of raised intracranial pressure, the median duration of symptoms being 2 months (range, 2-6 months), with a Karnofsky performance status (KPS) of 70. Localizing symptoms were also a common presenting feature, ranging from motor deficits (48.1%), cognitive impairment (22%), seizures (18.5%), to visual impairment (11.1%).

## Radiological picture

On Computed tomography (CT) scan, they are often seen as supratentorial, sharply defined, lobulated or round hyperdense solid masses, with a relatively homogeneous contrast enhancement, along with peritumoral edema. On magnetic resonance imaging (MRI), they are characteristically seen as well-demarcated peripheral lesions abutting a dural surface, with uneven and thick-walls having ring-like enhancement and intratumoral strip enhancement [Figure 1]. In this retrospective analysis, all tumors were supratentorial in location with temporal lobe being the most common (48.1%). Frontal and parietal involvement was seen in 11 and eight patients, respectively. Occipital location was found in two cases. Tumors were multilobed in 11 patients and multicentric in three patients.

## Surgery

All patients underwent maximally possible safe surgery. Gross total resection was done in 16 (59.3%) cases, near total resection in five cases, while only subtotal resection for decompression was possible in six cases.

## Histopathology

All tumors in this study fulfilled the criteria for gliosarcoma showing biphasic histologic pattern consisting of a gliomatous and sarcomatous components as shown in Figure 2. Glial component was strongly positive for glial fibrillary acidic protein (GFAP), with vascular proliferation, nuclear atypia, and areas of necrosis; the sarcomatous component was positive for vimentin and reticulin but further characterization was not done. Molecular profiling could not be done in most of our patients because of financial constraints in a developing country like ours.

## Adjuvant treatment

Postoperative radiotherapy (PORT) was delivered in 26 cases, with one drop-out after registration. The median interval between surgery and PORT was 6 weeks. Twenty-one patients received external beam radiotherapy of 60 Gy in 30 fractions over a 6-week period. Four patients received hypofractionated radiotherapy of 40 Gy in 15 fractions in three weeks due to poor performance status. All patients were treated with conformal radiotherapy. One patient defaulted due to poor tolerance. Radiation is delivered in two phases—phase I (base): 40 Gy/20#/4 weeks to contrast enhancing tumor (on T1-weighted MRI) with a margin of 3 cm; phase II (boost):

Access this article online

Quick Response Code:



Website: www.sajc.org

DOI: 10.4103/2278-330X.149931

Department of Radiation Oncology, <sup>1</sup>Neurosurgery, <sup>2</sup>Histopathology Post Graduate Institute of Medical Education and Research, Chandigarh, India

**Correspondence to:** Dr. Narendra Kumar,  
E-mail: drnarendra74@gmail.com

20 Gy/10#2 weeks to contrast enhancing tumor with a margin of 1 cm. Temozolomide was given concurrently at 75 mg/m<sup>2</sup> throughout the course of radiation including weekends, followed by adjuvant temozolomide at 150-200 mg/m<sup>2</sup> from day 1 to day 5 at 4 weekly intervals for six cycles in 11 patients who could afford and tolerate the drug.

### Response to treatment

Ten patients were asymptomatic at completion of treatment. Six patients improved clinically, and six patients deteriorated during or at completion of radiotherapy. Neurological status improved in 20% of patients. Salvage surgery was not done in any of our patients for recurrence. One of the patients received bevacizumab 10 mg/kg 2 weekly for six cycles. Another patient received lomustine 80 mg 6 weekly for three cycles.

### Survival analysis

All 27 patients were eligible for demographic analysis. However, for adjuvant treatment, the drop outs were excluded, and 26 patients were analyzed. The median follow up period was 6.2 months. Median overall survival was 9 months (range, 2-22 months). Six month overall survival was 70%. On subgroup analysis, median overall survival in the radiotherapy plus temozolomide group was 10 months as compared to 9 months in the radiotherapy alone group; however, this was not statistically significant ( $P = 0.244$ ). [Figure 3].

### Discussion

Gliosarcoma is a rare intracranial neoplasm and comprises 1.8-2.8% of all GBMs.<sup>[1]</sup> In our center, gliosarcomas constitute 3.61% (27/748) of all GBM in the last 5 years.

The histogenesis of the sarcomatous portion of gliosarcoma has been a matter of controversy since its initial description. Early reports suggested that the sarcomatous components originated from the neoplastic transformation of hyperplastic blood vessels commonly found in high-grade gliomas. Recent genetic studies revealed the presence of identical p53 and phosphatase and tensin homolog (PTEN) mutations and similar chromosomal imbalances and cytogenetic alterations in both components of gliosarcomas suggesting a monoclonal origin.<sup>[4,5]</sup> The predominance of sarcomatosis is associated with a better prognosis and a longer period of time without recurrence.<sup>[6]</sup>

Gliosarcomas typically affect adults in their fourth to sixth decade, with significant male preponderance (male: female = 1.8:1).<sup>[7]</sup> Median age of presentation of our patients is 54 years, which is identical to other series.

The striking features of gliosarcoma that distinguish it from GBM include its location and its differential radiographic and gross appearance. Gliosarcomas are usually supratentorial in location with temporal lobe being the most common site involved.<sup>[7,8]</sup> This retrospective analysis also showed temporal lobe predilection followed by frontal and parietal lobe involvement.

Though extracranial metastasis from GBM is rare, gliosarcomas are well-known for their systemic dissemination. Most common sites of extracranial metastasis are the lungs and the liver.<sup>[9]</sup> Smith *et al.*,<sup>[10]</sup> in their largest series of seven cases of metastatic gliosarcoma noted that in two cases the metastatic foci were composed solely sarcomatous components. Metastatic potential of gliosarcoma is due to its sarcomatous component that has a strong propensity for hematogenous spread.

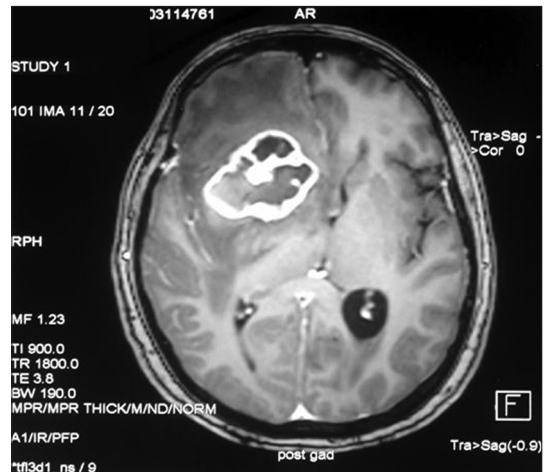


Figure 1: T1 weighted contrast enhanced MRI showing heterogeneously enhancing lesion in Right fronto temporal region with significant perilesional edema and mass effect

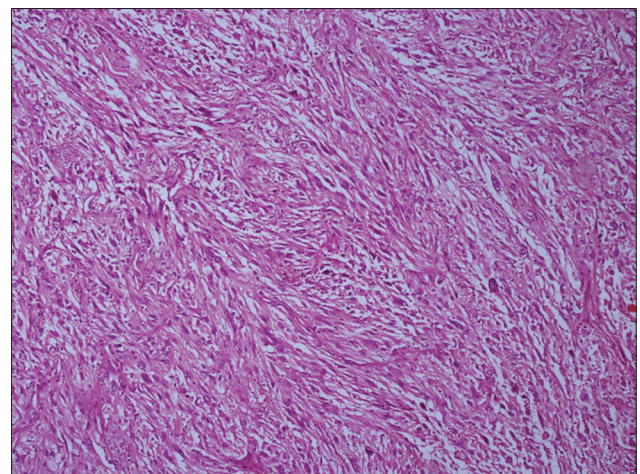


Figure 2: Photomicrograph of gliosarcoma showing fascicles of sarcomatous area alternating with gliomatous areas

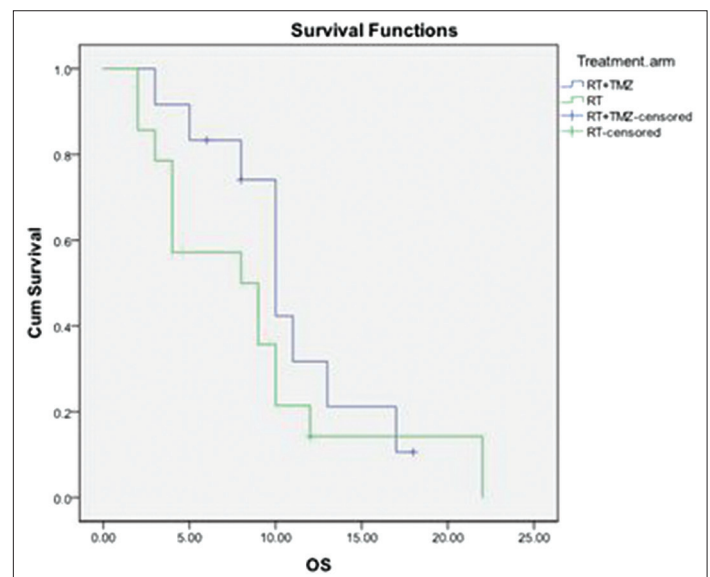


Figure 3: Kaplan Meier curve showing impact of addition of Temozolomide to Radiotherapy alone on survival

The majority of information on primary gliosarcoma therapy is derived from published case series. Typically, the described therapeutic approach is based on the prevailing treatment recommendations for GBM, including maximal safe surgical resection followed by adjuvant radiation therapy and

temozolomide-based chemotherapy.<sup>[11]</sup> The total dose delivered in radiotherapy ranged from 45 to 81 Gy in different reports.<sup>[1,7]</sup> The benefit of radiation therapy on survival of patients was described by Perry *et al.*, as radiation-treated patients had median survival of 10.6 months compared to 6.25 months in patients not treated with radiation ( $P = 0.025$ ).<sup>[12]</sup> At our center, 80.76% patients received the standard dose external beam radiotherapy of 60 Gy in 30 fractions after maximal safe surgery. Conformal radiotherapy was used in all of our patients, unlike our previously published study where only 46.7% received 3d-CRT.<sup>[13]</sup>

Although chemotherapy with temozolomide is now the standard of care for GBM, the precise role of chemotherapy remains uncertain for primary gliosarcoma. Morantz *et al.*, observed a modest increase in survival for these patients when chemotherapy with mithramycin and amephterin (dose not reported) was added to postsurgical radiation alone (36, 33 weeks respectively, no  $P$  value given).<sup>[14]</sup> Other authors did not offer chemotherapy to study participants, citing its ill-defined role. Though the role of chemotherapy in the management of gliosarcoma is not well defined, we have used concurrent and adjuvant temozolomide following the lines of management of GBM; 42.3% patients received concurrent and adjuvant temozolomide, which was much higher from our previous series where only two patients received temozolomide. With addition of temozolomide in a fair number of patients, median overall survival improved by one month in the chemoradiation arm. Though it was not statistically significant, it has definitely shown a trend towards benefit.

The prognosis for gliosarcoma is generally poor, with an average survival ranging from 8-24 months from the onset of symptoms.<sup>[14]</sup> Meis *et al.*,<sup>[15]</sup> reported median survival of 8.3 months for gliosarcoma patients as compared to 9.6 months for GBM patients. Multiple other case series<sup>[16,17]</sup> have shown similar results with poorer outcomes for primary gliosarcomas as compared to GBMs. In our series, median overall survival is approximately 9 months, which is considerably comparable with other studies. We could improve the outcomes from our previous series<sup>[13]</sup> possibly because of improved dose delivery by conformal techniques and increased use of temozolomide as radiosensitizer. Though addition of temozolomide has not significantly improved survival, it has shown a definite trend towards benefit compared to radiation alone. However, there is room for further improvement if we could decrease the median gap between surgery and radiotherapy because of delayed referrals and long waiting lists from 6 weeks in our series to the recommended 2-4 weeks.

There is very little data regarding the response of gliosarcomas to novel therapies. In future, attention needs to be focused on the cellular and molecular biology of gliosarcoma pertaining to tumor proliferation, invasion, angiogenesis, interaction with extracellular matrix and promoter methylation status of the DNA repair enzyme O6-methylguanine DNA methyltransferase (MGMT), and amplification of EGFR. Studies have shown a strong association between MGMT promoter-methylated tumors and PTEN positivity with improved survival.<sup>[18]</sup>

## Conclusion

Gliosarcoma is a rare clinicopathological entity. The optimum treatment of gliosarcoma is not yet well defined; however, they are treated along the lines of GBM as of now. Increased use of conformal radiation and concurrent temozolomide helped us improve the median overall survival and 6-month survival to 9 months and 70% as compared to 8.27 months and 60.7%, respectively, from our previously published series. In future, attention needs to be focused on the cellular and molecular biology of gliosarcoma, which will help us to modify the treatment and may improve further survival.

## References

- Lutterbach J, Guttenberger R, Pagenstecher A. Gliosarcoma: A clinical study. *Radiother Oncol* 2001;61:57-64.
- Louis DN, Ohgaki H, Wiestler OD, Cavenee WK, Burger PC, Jouvet A, *et al.* The 2007 WHO classification of tumours of the central nervous system. *Acta Neuropathol* 2007;114:97-109.
- Stroebe H. Ueber Entstehung und Bau der Gehirnglioma. *Beitr Pathol Anat Allg Pathol* 1895;19:405-86.
- Reis RM, Konu-Lebleblicioglu D, Lopes JM, Kleihues P, Ohgaki H. Genetic profile of gliosarcomas. *Am J Pathol* 2000;156:425-32.
- Boerman RH, Anderl K, Herath J, Borell T, Johnson N, Schaeffer-Klein J, *et al.* The glial and mesenchymal elements of gliosarcomas share similar genetic alterations. *J Neuropathol Exp Neurol* 1996;55:973-81.
- di Norcia V, Piccirilli M, Giangaspero F, Salvati M. Gliosarcomas in the elderly: Analysis of 7 cases and clinico-pathological remarks. *Tumori* 2008;94:493-6.
- Han SJ, Yang I, Tihan J, Prados MD, Parsa AT. Primary gliosarcoma: Key clinical and pathologic distinctions from glioblastoma with implications as a unique oncologic entity. *J Neurooncol* 2010;96:313-20.
- Galani E, Buckner JC, Dinapoli RP, Scheithauer BW, Jenkins RB, Wang CH, *et al.* Clinical outcome of gliosarcoma compared with glioblastoma multiforme: North Central Cancer Treatment Group results. *J Neurosurg* 1998;89:425-30.
- Ehrenreich T, Devlin JF. A complex of glioblastoma and spindle-cell sarcoma with pulmonary metastases. *AMA Arch Pathol* 1958;66:536-49.
- Smith D, Hardman JM, Earle KM. Glioblastoma multiforme and fibrosarcoma with extracranial metastasis. *Cancer* 1969;24:270-6.
- Stupp R, Mason WP, van den Bent MJ, Weller M, Fisher B, Taphoorn MJ, *et al.*, European Organisation for Research and Treatment of Cancer Brain Tumor and Radiotherapy Groups, National Cancer Institute of Canada Clinical Trials Group. Radiotherapy plus concomitant and adjuvant temozolomide for glioblastoma. *N Engl J Med* 2005;352:987-96.
- Perry JR, Ang LC, Bilbao JM, Muller PJ. Clinicopathologic features of primary and postirradiation cerebral gliosarcoma. *Cancer* 1995;75:2910-8.
- Biswas A, Kumar N, Kumar P, Vasistha RK, Gupta K, Sharma SC, *et al.* Primary Gliosarcoma—clinical experience from a regional cancer centre in North India. *Br J Neurosurg* 2011;25:723-9.
- Morantz R, Feigin I, Ransohoff J 3<sup>rd</sup>. Clinical and pathological study of 24 cases of gliosarcoma. *J Neurosurg* 1976;45:398-408.
- Meis J, Martz KL, Nelson JS. Mixed glioblastoma multiforme and sarcoma. A clinicopathologic study of 26 radiation therapy oncology group cases. *Cancer* 1990;67:2342-9.
- Miller CR, Perry A. Glioblastoma: Morphologic and molecular genetic diversity. *Arch Pathol Lab Med* 2007;131:397-406.
- Maiuri F, Stella L, Benvenuti D, Giamundo A, Pettinato G. Cerebral gliosarcomas: Correlation of computed tomographic findings, surgical aspect, pathological features, and prognosis. *Neurosurgery* 1990;26:261-2.
- Prados MD, Chang SM, Butowski N, DeBoer R, Parvataneni R, Carliner H, *et al.* Phase II study of erlotinib plus temozolomide during and after radiation therapy in patients with newly diagnosed glioblastoma multiforme or gliosarcoma. *J Clin Oncol* 2009;27:579-84.

**How to cite this article:** Kumar N, Bhattacharyya T, Chanchalani K, Shalunke P, Radotra BD, Yadav BS. Impact of changing trends of treatment on outcome of cerebral gliosarcoma: A tertiary care centre experience. *South Asian J Cancer* 2015;4: 15-7.

**Source of Support:** Nil. **Conflict of Interest:** None declared.