

Addition of magnetic resonance imaging to computed tomography-based three-dimensional conformal radiotherapy planning for postoperative treatment of astrocytomas: Changes in tumor volume and isocenter shift

Puneet Kumar Bagri, Akhil Kapoor, Daleep Singh, Mukesh Kumar Singhal, Satya Narayan, Harvindra Singh Kumar

Abstract

Introduction: Postoperative radiotherapy is the current gold standard treatment in astrocytomas. Computed tomography (CT)-based radiotherapy planning leads to either missing of the tumor volume or underdosing. The aim of this prospective study was to study the changes in tumor volume on addition of magnetic resonance imaging (MRI) to CT-based three-dimensional radiotherapy treatment planning of astrocytomas. **Materials and Methods:** Twenty-five consecutive patients of astrocytoma (WHO grades I-IV) for postoperative three-dimensional conformal radiotherapy were included in this prospective study. Postoperative tumor volumes were contoured on CT-based images and recontoured on CT-MRI images after automated MRI co-registration on treatment planning system Eclipse 8.9.15 as per ICRU-50 report. Tumor volumes were compared with each other. **Result:** The MRI-based mean and median tumor volume was 24.24 cc \pm 13.489 and 18.72 cc (range 5.6–46.48 cc), respectively, while for CT it was 19.4 cc \pm 11.218 and 16.24 cc (range: 5.1–38.72 cc), respectively. The mean and median isocenter shift between CT and MRI was 4.05 mm and 4.39 mm (range 0.92–6.32 mm), respectively. There is a linear relationship between MRI and CT volume with a good correlation coefficient of $R^2 = 0.989$, and MRI-based tumor volume was 1.208 times as compared to CT volume. Statistical analysis using paired sample *t*-test for the difference in CT and MRI tumor volume was highly significant ($P < 0.001$). **Conclusion:** Addition of MRI to the CT-based three-dimensional radiation treatment planning reduces the chances of geographical miss or tumor under dosing. Thus, MRI should be an integral part of three-dimensional planning of astrocytomas.

Key words: Astrocytoma, computed tomography-magnetic resonance imaging fusion, isocenter shift, postoperative radiotherapy, tumor volume

Introduction

Modern anatomic imaging technologies, such as computed tomography (CT) and magnetic resonance imaging (MRI), provide a fully three-dimensional model of the cancer patient's anatomy. Such advanced imaging allows the radiation oncologists to accurately delineate tumor volumes and their relationship with other critical normal organs. CT provides geometrically precise scans, but it gives less information about the soft tissues as compared to MRI. The resolution of the brain parenchyma is far superior in an MRI as it provides greater detail and better topographic distribution of the abnormal lesions.^[1-4] The possibility of obtaining high-quality images without the bone artifact makes MRI particularly attractive for evaluating lesions in the posterior fossa, at the vertex, and the base of the skull. Although MRI is adequately sensitive for the detection of intracranial lesions, it lacks specificity in pronouncing tumor cell type or grade. Further, MRI abnormalities seen in astrocytomas overlap with those seen in stroke and demyelinating disease. CT-MRI fusion is the standard imaging technique for three-dimensional radiotherapy treatment planning for brain tumors. The aim of this prospective study was to study the advantages of addition of MRI- to CT-based three-dimensional radiotherapy treatment planning of primary brain tumors.

Materials and Methods

Twenty-five consecutive patients with histopathologically proven astrocytoma (WHO grades I-IV) referred to our regional cancer institute for postoperative three-dimensional conformal radiotherapy were included in this prospective study. Immobilization was done using ORFIT thermoplastic cast (ORFIT Industries, Belgium), and contrast-enhanced CT and MRI was done with the cast *in situ*.

Computed tomography simulation was done with the patients immobilized on the flat couch of the diagnostic CT unit (CT Hispeed Nxi, Wipro GE, Bangalore, India). Following early intravenous contrast, axial scans of 3 mm slice thickness were taken from the vertex to the base of the skull. These images were transferred to the radiation therapy treatment planning system (TPS) Eclipse 8.9.15 (Varian, Palo Alto, USA).

Magnetic resonance imaging scans were taken with a standard head coil (1.5 T, Philips, USA). A custom-made Perspex base plate was used for fixing the cast during MRI, which was similar to the one used during CT acquisition. Spin-echo (SE) sequence, having the least image distortion, was used to obtain images from the vertex to the base of the skull.^[5] The conventional SE T2-weighted plain and postgadolinium contrast T1-weighted axial MRI images of 3 mm slice thickness were obtained. The MRI images were transferred to the radiation therapy TPS Eclipse 8.9.15.

Postoperative tumor volumes were contoured on CT-based images as per the recommendations of ICRU-50 report.^[6] Tumor volumes were recontoured on composite CT-MRI images after automated MRI co-registration. All the contourings were done by same person to eliminate interobserver variability, and the contouring process was double-blinded. Tumor volumes were measured and compared with each other. Geometrical center of the target volume was taken as isocenter of tumor volume contoured on CT and MRI. Isocenter shift of tumor was determined with the distance formula. Total tumor dose delivered was 50.4–64.8 Gy depending on astrocytoma grade. Statistical analysis was done using SPSS statistical software for Windows, version 20.0 (IBM Corp., Armonk, NY, USA).

Results

For postoperative three-dimensional conformal radiotherapy planning, CT simulation was done, and MRI was carried out within 3 days of CT simulation. The mean and median interval between surgery and postoperative CT was 23.32 and 24 days. The mean and median time interval between CT and MRI was 1.48 days and 1 day, respectively. High-grade astrocytoma patients were more than with low grade (17:8). The main operative procedures were either subtotal resection or tumor

Access this article online

Quick Response Code:



Website: www.sajc.org

DOI: 10.4103/2278-330X.149939

Department of Radiation Oncology, Acharya Tulsi Regional Cancer Treatment and Research Institute, Bikaner, Rajasthan, India

Correspondence to: Dr. Puneet Kumar Bagri, E-mail: drpuneetkb@yahoo.com

decompression. Total resection was done in only two patients. Table 1 shows the baseline characteristics of the patients.

The MRI-based mean and median tumor volume was 24.24 cc ± 13.489 and 18.72 cc (range 5.6–46.48 cc), respectively, while for CT it was 19.4 cc ± 11.218 and 16.24 cc (range: 5.1–38.72 cc) respectively. The mean and median isocenter shift between CT and MRI was 4.05 mm and 4.39 mm (range 0.92–6.32 mm), respectively. There is a linear relationship between MRI and CT volume with a good correlation coefficient of $R^2 = 0.989$ and MRI-based tumor volume was 1.208 times as compared to CT volume [Figure 1a]. Bland-Altman test shows that MRI volume is larger than CT volume [Figure 1b]. Statistical analysis using paired sample *t*-test for the difference in CT and MRI tumor volume was highly significant ($P < 0.001$). Compared to MRI, CT significantly underestimated the volumes, resulting in a mean difference between the imaging modalities (CT volume – MRI volume) of -4.684 ± 2.754 cc ($P < 0.001$) [Table 2]. The percentage difference calculated taking the CT volume as baseline [(CT-based volume – MRI-based volume)/CT-based volume × 100] shows that for tumor volume, the mean percentage difference was -25.9% (SD: ±11.6). The isocenter shift decreases with an increase in tumor volume [Figure 1c].

The comparison of CT and MRI-based tumor volumes was also done separately for low grade (grades I and II) and high grade (grades III and IV) astrocytoma [Table 2]. The

MRI-based volumes were significantly higher ($P < 0.001$) in the low grade as well as high-grade astrocytoma. Figure 1d shows the histogram with normal distribution curve depicting percentage difference in tumor volume for low grade versus high-grade astrocytoma. Figure 1e shows the histogram for percentage difference in tumor volume for overall patients included in the study.

Discussion

Whole brain radiotherapy was the standard of care in the era of nonavailability of sophisticated imaging modalities.

Table 1: Patient characteristics (n=25)

Characteristics	Distribution
Age (years)	42.52±9.549 (range: 23-64)*
Sex (male:female)	18:7
Location of tumor (frontal: parietal:temporal:occipital)	10:4:8:3
Laterality (right:left)	9:16
Surgery (DCN:STR:TR)	10:13:2
Astrocytoma WHO grade (I:II:III:IV)	2:6:10:7
Total tumor dose (gray)	58.896±4.72 (range: 50.4-64.8)
Gross tumor volume (cc)	
CT	19.4±11.218 (range: 5.1-38.72)
MRI	24.24±13.489 (range: 5.6-46.48)

*Mean±SD. DCN=Decompression, STR=Subtotal resection, TR=Total resection, SD=Standard deviation, WHO=World Health Organization, CT=Computed tomography, MRI=Magnetic resonance imaging

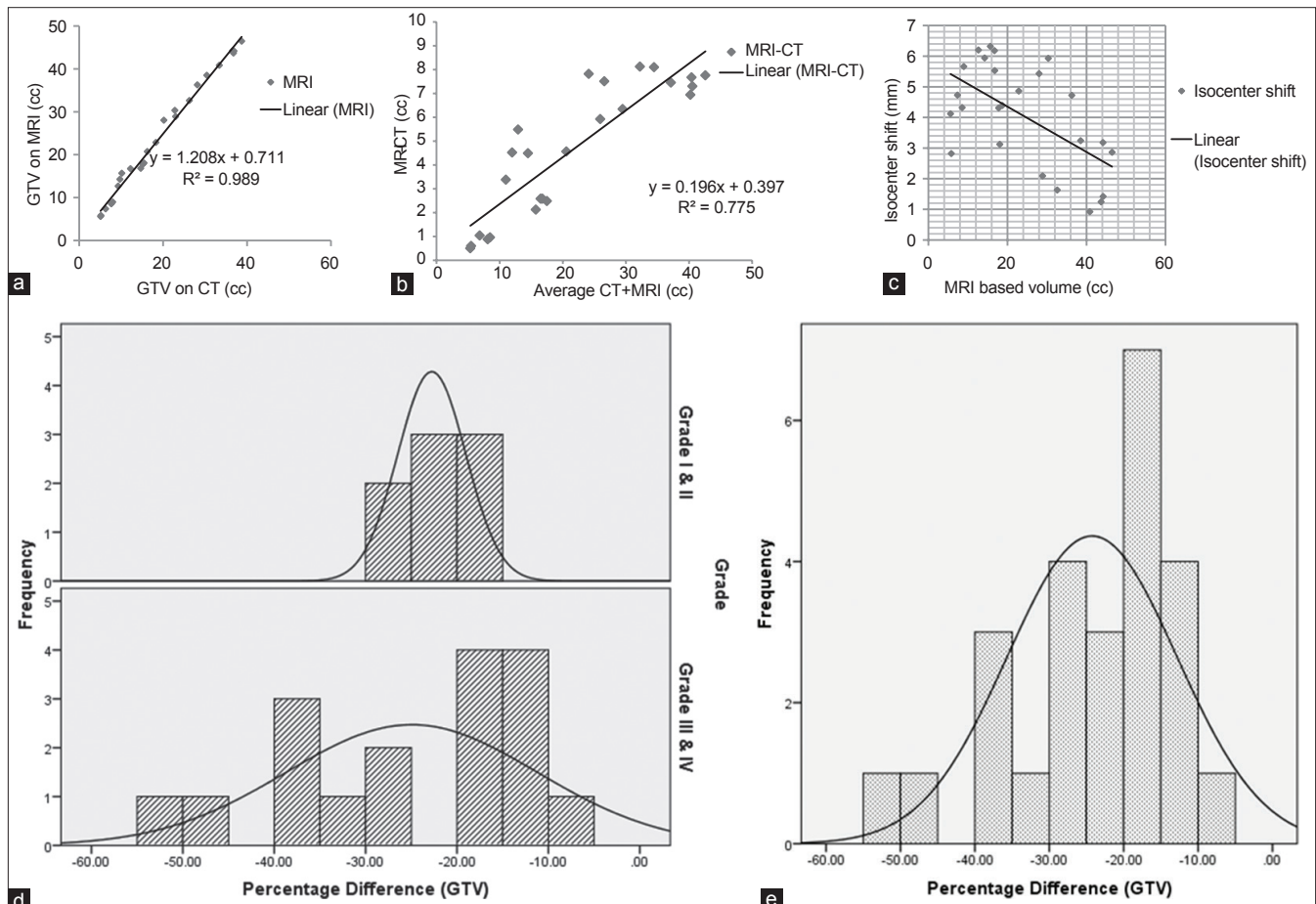


Figure 1: (a) Scatter diagram for computed tomography (CT) and magnetic resonance imaging (MRI) based gross tumor volume. The curve represents linear relationship ($R^2 = 0.989$). MRI shows 1.208 times more volume as compared to CT volume. (b) Bland-Altman test for computed tomography and MRI-based tumor volume. (c) Isocenter shift decreases with an increase in tumor volume. (d) Histogram with normal distribution curve depicting percentage difference in tumor volume for low grade versus high-grade astrocytoma. (e) Histogram with normal distribution curve for percentage difference in tumor volume for overall patients included in the study

Table 2: Mean differences in tumor volumes and isocenter shift as evident on CT and MRI

Volume (cc)	CT (cc)	MRI (cc)	Difference (cc) CT-MRI	Isocenter shift (mm)	P*
All patients (n=25)	19.4±11.218	24.24±13.489	-4.684±2.754	4.0±1.732	<0.001
Grade I, II (n=8)	33.38±4.868	40.88±4.549	-7.46±0.061	2.38±1.408	<0.001
Grade III, IV (n=17)	12.82±5.897	16.41±7.771	-3.37±2.356	4.76±1.3	<0.001

*Paired sample *t*-test; all volumes indicate mean±SD. SD=Standard deviation, CT=Computed tomography, MRI=Magnetic resonance imaging

However, with poor outcomes after the treatment of malignant astrocytoma, partial brain irradiation after surgery is the current gold standard. It has been realized that the region of recurrence in malignant astrocytoma is usually the tumor bed itself, stressing on the fact that accurate target volume delineation is mandatory especially while giving the boost dose to the surgical bed. Delineation of the target volume is highly dependent on the observer (both inter and intra observer variations).^[7,8] With the help of CT-MRI fusion based planning, the chances of geographical miss are minimal. Treatment planning based on CT only will lead to either miss the tumor volume or under dosing of the tumor. In this study, use of MRI caused 25.9% increase in gross tumor volume. This showed the importance of MRI in tumor delineation for tumors in the brain. Shift of isocenter also showed the possibilities of under dosing of the tumor. The fact that MRI shows larger tumor volume compared to CT is well in accord with the published results. As the tumor volume increases, the isocenter shift decreases. This clearly indicates that the chances of tumor miss are more when tumor is small and planning is done based only on CT scan. CT-MRI fusion is necessary for planning of brain tumors to rule out geographical misses. Initial study for radiation treatment planning using MRI demonstrates a 30% reduction of treatment volume.^[9] But the other studies show that the use of MRI in tumor volume delineation increases the tumor volume.^[10-13] Hence, MRI is superior to provide the detail of tumor volume and volume of organs at risk.^[14]

Conclusion

We conclude that addition of MRI- to the CT-based three-dimensional radiation treatment planning reduces the chances of geographical miss or tumor under dosing. Thus, MRI should be an integral part of three-dimensional planning of astrocytomas.

Acknowledgment

The support of Department of Radiation Oncology, Acharya Tulsi Regional Cancer Treatment and Research Institute, Bikaner, Rajasthan, India is gratefully acknowledged.

References

1. Berg G, Blomquist E, Cavallin-Ståhl E. A systematic overview of radiation

- therapy effects in brain tumours. *Acta Oncol* 2003;42:582-8.
2. Jansen EP, Dewit LG, van Herk M, Bartelink H. Target volumes in radiotherapy for high-grade malignant glioma of the brain. *Radiother Oncol* 2000;56:151-6.
3. Byrne TN. Imaging of gliomas. *Semin Oncol* 1994;21:162-71.
4. Madison MT, Hall WA, Latchaw RE, Loes DJ. Radiologic diagnosis, staging, and follow-up of adult central nervous system primary malignant glioma. *Radiol Clin North Am* 1994;32:183-96.
5. Mizowaki T, Nagata Y, Okajima K, Kokubo M, Negoro Y, Araki N, et al. Reproducibility of geometric distortion in magnetic resonance imaging based on phantom studies. *Radiother Oncol* 2000;57:237-42.
6. ICRU-50. Prescribing, Recording and Reporting Photon Beam Therapy. Bethesda: ICRU; 1993.
7. Weiss E, Hess CF. The impact of gross tumor volume (GTV) and clinical target volume (CTV) definition on the total accuracy in radiotherapy theoretical aspects and practical experiences. *Strahlenther Onkol* 2003;179:21-30.
8. Weltens C, Menten J, Feron M, Bellon E, Demaerel P, Maes F, et al. Interobserver variations in gross tumor volume delineation of brain tumors on computed tomography and impact of magnetic resonance imaging. *Radiother Oncol* 2001;60:49-59.
9. Websy G, Adamis MK, Edelmann RR. Artifacts in MRI: Description, causes and solutions. In: Edelmann RR, Hesselink JK, Zlatkin MB, editors. *Clinical Magnetic Resonance Imaging*. Philadelphia, PA: Saunders; 1996. p. 88-144.
10. Ten Haken RK, Thornton AF Jr, Sandler HM, LaVigne ML, Quint DJ, Fraass BA, et al. A quantitative assessment of the addition of MRI to CT-based, 3-D treatment planning of brain tumors. *Radiother Oncol* 1992;25:121-33.
11. Thornton AF Jr, Sandler HM, Ten Haken RK, McShan DL, Fraass BA, La Vigne ML, et al. The clinical utility of magnetic resonance imaging in 3-dimensional treatment planning of brain neoplasms. *Int J Radiat Oncol Biol Phys* 1992;24:767-75.
12. Datta NR, David R, Gupta RK, Lal P. Implications of contrast-enhanced CT-based and MRI-based target volume delineations in radiotherapy treatment planning for brain tumors. *J Cancer Res Ther* 2008;4:9-13.
13. Prabhakar R, Haresh KP, Ganesh T, Joshi RC, Julka PK, Rath GK. Comparison of computed tomography and magnetic resonance based target volume in brain tumors. *J Cancer Res Ther* 2007;3:121-3.
14. Kessler ML, Ten Haken RK, Fraass BA, McShan DL. Expanding the use and effectiveness of dose-volume histograms for 3-D treatment planning. I: Integration of 3-D dose-display. *Int J Radiat Oncol Biol Phys* 1994;29:1125-31.

How to cite this article: Bagri PK, Kapoor A, Singh D, Singhal MK, Narayan S, Kumar HS. Addition of magnetic resonance imaging to computed tomography-based three-dimensional conformal radiotherapy planning for postoperative treatment of astrocytomas: Changes in tumor volume and isocenter shift. *South Asian J Cancer* 2015;4: 18-20.

Source of Support: Department of Radiation Oncology, Acharya Tulsi Regional Cancer Treatment and Research Institute, Bikaner, Rajasthan, India.

Conflict of Interest: None declared.