

Laparoscopic management of sigmoidorectal intussusception caused by sigmoid carcinoma

DOI: 10.4103/2278-330X.149952

Dear Editor,

Colo-colic intussusception involving left colon in adults is rare. Intussusception in adults is usually associated with some pathology as the lead point, unlike pediatric age group where it is usually idiopathic. Surgical resection followed by anastomosis remains the standard treatment in cases of large bowel intussusception. There is no consensus on the role of reduction of intussusception before resection. Herein, we are presenting a case of sigmoidorectal intussusception, which was managed laparoscopically.

Sixty-two years old, otherwise healthy gentleman presented to us with history of bleeding per rectum of 4-month duration. Per rectal examination revealed a polypoidal growth at 7 cm from anal verge. Magnetic resonance imaging (MRI) of pelvis showed mass arising from sigmoid colon causing sigmoidorectal intussusception [Figure 1a]. Colonoscopy revealed an ulcero proliferative growth arising in sigmoid colon at 20 cm from anal verge and biopsy proved it to be adenocarcinoma. Patient was planned for laparoscopic definitive surgery. Intra-operatively there was sigmoidorectal intussusception, but otherwise healthy bowel wall with no gross edema or necrosis [Figure 1b]. Intussusception was reduced with gentle manipulation using a swab [Figure 1c]. Once reduced, it was found that the mass was arising from the apex of sigmoid colon loop. Sigmoid colectomy was done [Figure 1d]. Intra-operative and post operative course was uneventful. Patient was discharged on fourth post operative day. Final histopathology revealed, moderately differentiated adenocarcinoma pT2 N1a. One out of thirteen nodes showed deposits of adenocarcinoma with perinodal extension. Proximal and distal margins were adequate. Patient was planned for CAPEOX chemotherapy.

Adult intussusception accounts for 1% of cases of intestinal obstruction in adults though it is the most common cause of intestinal obstruction in infants. Unlike in children where it is idiopathic, adult intussusception is caused by malignant tumors in 64% to 87% of patients and by benign tumors in 29% to 33% of patients.^[1] Colo-colic intussusception is more common in adults with the most cases affecting the right colon. Sigmoidorectal intussusception is distinctly rare. Conventionally, these cases are managed by surgical resection. Reduction of

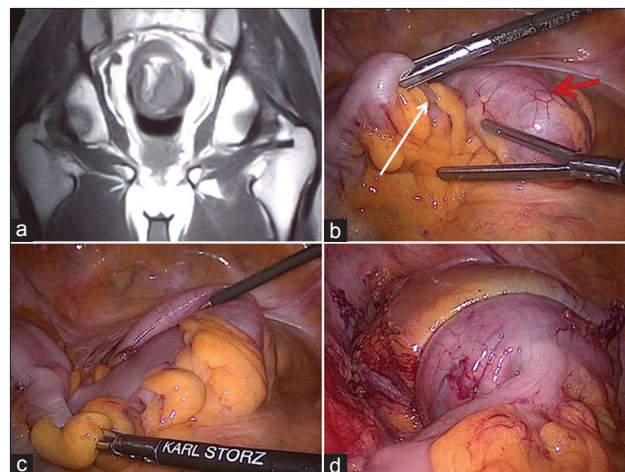


Figure 1: (a) MRI pelvis showing sigmoidorectal intussusception. (b) Intra-operative picture showing sigmoidorectal intussusception. red arrow –Intussusciens; white arrow – Intussuseptum. (c) Reduction of sigmoidorectal intussusception. (d) Anastomosis between descending colon and rectum after sigmoid colectomy

intussusception prior to resection is deemed unsafe particularly in the presence of underlying mass.^[2] In our patient, if reduction was not attempted, patient would have required anterior resection, which is more morbid surgery than sigmoid colectomy. There are couple of prior reports of successful reduction of sigmoidorectal intussusception by laparoscopic technique.^[3,4]

Sigmoidorectal intussusception can be successfully managed by laparoscopic technique and careful reduction of intussusception may avoid more radical procedures at this site.

Vishwas D. Pai, Ashwin Desouza, Manish Bhandare, A. P. Saklani

Department of Surgical Oncology, TATA Memorial Hospital, Mumbai, Maharashtra, India

Correspondence to: Dr. Vishwas D. Pai,
E-mail: vishpai88@gmail.com

References

1. Nagorney DM, Sarr MG, McIlrath DC. Surgical management of intussusception in the adult. *Ann Surg* 1981;193:230-6.
2. Begos DG, Sandor A, Modlin IM. The diagnosis and management of adult intussusception. *Am J Surg* 1997;173:88-94.
3. Lee SY, Park WC, Lee JK, Kang DB, Kim Y, Yun KJ, *et al*. Laparoscopic treatment of adult sigmoidorectal intussusception caused by a mucinous adenocarcinoma of the sigmoid colon: A case report. *J Korean Soc Coloproctol* 2011;27:44-9.
4. Chuang CH, Hsieh CB, Lin CH, Yu JC. Laparoscopic management of sigmoid colon intussusception caused by a malignant tumor: Case report. *Rev Esp Enferm Dig* 2007;99:615-6.