

Impact and prognostic value of ¹⁸F-fluorodeoxyglucose positron emission tomography-computed tomography scan in the evaluation of residual head and neck cancer: Single-center experience from Pakistan

Saima Riaz, Humayun Bashir, Hassan Iqbal¹, Arif Jamshed², Ahmad Murtaza³, Raza Hussain¹

Abstract

Background: Overview of clinical impact of positron emission tomography-computed tomography (PET-CT) scans in patients with head and neck carcinomas at our center. **Methods:** Retrospective review of posttreatment ¹⁸F-fluorodeoxyglucose (¹⁸F-FDG) PET-CT scans in patients with head and neck carcinomas with risk of residual disease. Clinical outcome served as the reference standard. **Results:** This study included 93 patients (65.6% males, mean age: 48.8 years \pm 17.2 standard deviation) with squamous cell carcinoma as most frequent histopathology (91.4%). PET-CT scans were performed on average 6 months posttreatment. Diagnostic accuracy, positive predictive value, and negative predictive value of PET-CT for disease were found to be 88%, 88%, and 92%, respectively. A median follow-up of 24 months was available for 91 patients. Kaplan–Meier curves showed significantly higher disease-free survival with negative PET-CT as compared to positive PET-CT ($P = 0.01$) and maximum standardized uptake values of <5.0 ($P = 0.01$). **Conclusion:** FDG PET-CT has diagnostic and prognostic implications in treated patient of head and neck cancers.

Key words: ¹⁸F-fluorodeoxyglucose positron emission tomography-computed tomography scan, disease-free survival, head and neck cancer, maximum standardized uptake values, squamous cell carcinoma

Introduction

Approximately, 550,000 cases of head and neck carcinomas are reported annually worldwide.^[1] The diagnostic workup for head and neck cancers is accomplished with computed tomography (CT) and magnetic resonance imaging delineating the anatomical details and extent of tumor. The metabolic and functional imaging with positron emission tomography-CT (PET-CT) is usually reserved for the assessment of nodal involvement, distant metastasis, treatment response evaluation, and disease recurrence.^[2]

The accuracy of hybrid PET-CT imaging is superior to the conventional anatomic imaging for restaging and radiotherapy planning in squamous cell carcinomas. A negative fluorodeoxyglucose (FDG) PET-CT scan acquired 2–3 months postchemoradiotherapy has high-negative predictive value (NPV). This prevents overtreatment with neck dissection and unnecessary diagnostic workup.^[3]

This study was conducted to review and analyze the clinical impact of the FDG PET-CT scans in carcinomas of head and neck in our oncological referral.

Methods

A consecutive, retrospective cohort of database was reviewed comprising ¹⁸F-FDG PET-CT scans acquired in patients with carcinomas of head and neck with high clinical risk of residual or recurrent disease after chemoradiotherapy during. Electronic data of 93 patients, from January 2010 to June 2014, were analyzed, available on institutional medical record system. At our institute, PET-CT is only employed in cases when there is a question of residual/recurrent disease on conventional imaging at least 4–6 months after the completion of chemoradiotherapy. Median time for PET-CT scans from completion of chemoradiotherapy was 6 months, excluding the chances of posttherapy metabolic changes. PET images were quantitatively (visual appearance and intensity of FDG activity in

the lesion under question, lesser or greater than that of the liver) and qualitatively (maximum standardized uptake values [SUV_{max}]) were assessed by the qualified nuclear physicians and radiologists with at least 5 years' experience at hand.

SUV_{max} values were compared amongst different histopathologies, degree of differentiation, and primary tumor location to identify any statistical correlation using Pearson's correlation coefficient. In all cases, statistical significance was accepted for $P < 0.05$.

The data set were evaluated for the presence or absence of metabolically active residual disease on ¹⁸F-FDG PET-CT scans in terms of frequency, identifying true positive, true negative, false positive, and false negative based on the clinical outcome and histopathological correlation as available. The data were sub-classified as posttreatment PET-CT positive and PET-CT negative groups.

Kaplan–Meier survival analyses curves were generated using SPSS program (SPSS Inc. Released 2008. SPSS Statistics for Windows, Version 17.0. Chicago) to assess disease-free survival (DFS), in terms of PET-CT outcome and SUV_{max} values. Survival differences between groups were evaluated by the log-rank test with a significance level of $P < 0.05$.

Results

A total of 93 patients with head and neck cancer underwent ¹⁸F-FDG PET-CT during the study period. Of these, 61 (65.6%) were males and 32 (34.4%) females [Table 1].

¹⁸F-fluorodeoxyglucose positron emission tomography-computed tomography scan outcome

About 68/93 had positive posttreatment PET-CT scans. In sixty patients, metabolically active residual disease (true positive) was identified (active residual $n = 33$; disease progression $n = 27$). One PET-CT scan revealed false positive FDG uptake in cervical node in a case of carcinoma buccal mucosa, which

This is an open access article distributed under the terms of the Creative Commons Attribution-NonCommercial-ShareAlike 3.0 License, which allows others to remix, tweak, and build upon the work non-commercially, as long as the author is credited and the new creations are licensed under the identical terms.

For reprints contact: reprints@medknow.com

How to cite this article: Riaz S, Bashir H, Iqbal H, Jamshed A, Murtaza A, Hussain R. Impact and prognostic value of ¹⁸F-fluorodeoxyglucose positron emission tomography-computed tomography scan in the evaluation of residual head and neck cancer: Single-center experience from Pakistan. South Asian J Cancer 2017;6:81-3.

Access this article online

Quick Response Code:



Website: www.sajc.org

DOI: 10.4103/2278-330X.208851

Departments of Nuclear Medicine, ¹Surgical Oncology, ²Radiation Oncology and ³Radiology, Shaukat Khanum Memorial Cancer Hospital and Research Centre, Lahore, Pakistan

Correspondence to: Dr. Saima Riaz, E-mail: saimarz.dr@gmail.com

turned out to be a benign histopathology on biopsy. Similarly, FDG uptake without corresponding morphologic abnormality was reported in seven scans, correlating with nonspecific postradiotherapy changes.

About 25/93 had negative posttreatment PET-CT scans. FDG nonavid morphologic residual was reported in five cases (true negative) while 18 were metabolically and morphologically unremarkable. False negative results were reported in two cases. An ill-defined soft tissue in a case of nasopharyngeal carcinoma with FDG uptake, which was labeled as reactive, however it turned out to be to be active disease on postsurgical histopathology. Similarly, FDG nonavid residual in one case of laryngeal carcinoma showed disease on postsurgical histopathology.

Accuracy, positive predictive value (PPV), and NPV of PET-CT for the evaluation of persistent disease were found to be 88%, 88%, and 92%, respectively.

On bivariate analysis, no significant correlation was found between the histopathology and SUV_{max} ($P = 0.001$, insignificant as the data set was skewed) or degree of differentiation and the SUV_{max} of the primary tumor ($P = 0.690$).

No correlation was seen between the SUV_{max} of the primary lesion and the location of tumor ($P = 0.142$). The SUV ranges in reference to the tumor location and histopathology are reported in Table 2.

The patients with FDG avid residual disease were further treated with chemoradiation (39.2%), surgical resection (10%), or palliative management (50.7%). Patients with negative PET-CT scans were put on follow-up.

Disease-free survival based on positron emission tomography-computed tomography findings and maximum standardized uptake values

DFS patients with posttreatment PET-CT scans was estimated over a median duration of 24 months, with maximum available duration of 57 months after PET-CT scan. Out of sixty patients whose posttreatment PET-CT scan demonstrated avid disease, 11 got cured and fifty were not cured (35 alive with disease, 15 died during the study period). No follow-up is available for seven patients.

Of 25 patients whose posttreatment PET-CT scan demonstrated no disease, 17 are alive, and cured, 5 alive with disease, and 3 patients died during the study period Figure 1.

The overall 3-year DFS was found to be higher (71%) in patients with negative PET-CT scan as compared to positive PET-CT scan (11%) after treatment. The difference in survival between the two groups was statistically significant (log-rank test; $P < 0.01$). The Kaplan–Meier survival curve is shown in Figure 2.

Based on SUV_{max} values on PET-CT scans, DFS rates were $SUV_{max} < 5 = 62\%$, $SUV_{max} 5–10 = 42\%$, and $SUV_{max} > 10 = 6\%$. The log-rank test showed a statistically significant difference in the percent survival ($P < 0.01$) Figure 3.

Discussion

Head and neck tumors demonstrate heterogeneity in terms of location and histopathology. However, squamous cell carcinoma is the most frequently encountered histopathology in head and neck cancers, which has been reported in

Table 1: Patients' and disease characteristics (n=93)

Characteristics	n
Patients' age, years	
Mean (SD)	48.8±17.2
Time to posttreatment PET/CT scan, months	
Median	6
Primary tumor location	
Oral cavity	26
Nasopharynx	32
Pharynx	10
Larynx	18
Para-nasal sinuses	1
Salivary glands	6
Histologic classification	
Squamous cell carcinoma	85
Adenocarcinoma	2
Olfactory neuroblastoma	3
Small cell carcinoma	1
Clear cell carcinoma	1
Anaplastic carcinoma	1
Degree of differentiation	
Well differentiated	10
Moderately differentiated	40
Poorly differentiated	29
Not available	14

SD=Standard deviation, PET=Positron emission tomography, CT=Computed tomography

Table 2: Standardized uptake value ranges in reference to the tumor location and histopathology

	SUV_{max} (SD)
Primary tumor location	
Oral cavity	6.2±3.3
Nasopharynx	4.8±3.9
Pharynx	5.1±4.3
Larynx	3.4±2.8
Paranasal sinuses	6.02±4.2
Salivary glands	7.7±3.7
Histologic classification	
Squamous cell carcinomas	5.8±4.2
Adenocarcinoma	6.4±1.4
Olfactory neuroblastoma	5.7±1.4
Others	4.2±1.7
Degree of differentiation	
Well differentiated	5.4±3.4
Moderately differentiated	5.3±4.0
Poorly differentiated	5.1±4.9

SUV_{max} =Maximum standardized uptake value, SD=Standard deviation

approximately more than 90% of cases.^[4] Similar high frequency (91.4%) of squamous cell carcinomas was observed in our data group. Furthermore, varied histology such as adenocarcinoma, neuroblastoma, small cell, clear cell, and anaplastic carcinomas enabled us to evaluate FDG avidity in these not very frequently seen tumors. Standardized uptake value, taken as an indicator for the degree of metabolic activity, remained inconclusive in terms of identifying any statistically significant difference between histopathological classification, degree of differentiation ($P = 0.690$), or tumor location ($P = 0.142$). Overall, 26.5% response rate was seen on postchemoradiotherapy PET-CT scans. We found 88% accuracy of PET-CT in detecting the viable residual disease. The PPVs

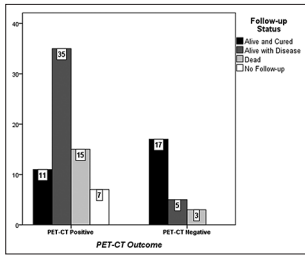


Figure 1: Comparison of follow-up status between posttreatment fluorodeoxyglucose positron emission tomography-computed tomography positive and negative groups

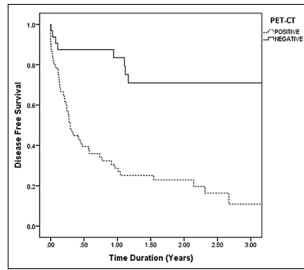


Figure 2: Kaplan–Meier 3-year disease free survival curve in patients with posttreatment positron emission tomography-computed tomography findings (positive positron emission tomography-computed tomography scan = 11%, negative positron emission tomography-computed tomography scan = 71%). The log-rank test shows a significant difference in the percent survival ($P < 0.001$)

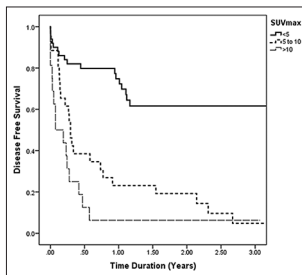


Figure 3: Kaplan–Meier 3-year disease free survival curve based on maximum standardized uptake values on positron emission tomography-computed tomography ($5 = 62\%, 5-10 = 42\%, >10 = 6\%$). Log-rank test $P < 0.001$

and NPVs were 77% and 92%, respectively. Gupta *et al.* in a meta-analysis review reported the similar low PPV (58.6%) and exceptionally high NPV (95.1%). This lower PPV is the result of posttherapy inflammatory changes frequently observed in head and neck cancer patients.^[5]

In our center, we perform posttreatment PET-CT scan at least 4–6 months after the completion of chemoradiotherapy. Average time observed in this data group was 6 months. This complies with the general consensus that this optimum time before ¹⁸F-FDG PET-CT allows the posttherapy changes to settle down, thereby reducing false positive results.^[3]

The high NPV of FDG PET-CT, ruling out the presence of viable disease, helps in decision making regarding further treatment or surveillance. As suggested by Porceddu *et al.* and Ware *et al.*, PET-CT has added value in restaging patients with morphological residual disease after definitive treatment, modifying decision regarding surgical interventions.^[6,7]

Despite high NPV, the controversies still exist where there is a question of microscopic disease. In our cohort, 32% of patients with negative posttherapy PET-CT scan developed recurrent disease within 6–12 months. All these patients had higher stage with moderate to poorly differentiated histology, to begin with. This fact highlights that FDG PET-CT cannot be the sole factor in decision making and other factors such as initial stage and histology of the primary tumor remain the mainstay in prognostication.

We found favorable prognosis in patients with negative posttreatment PET-CT scan. Overall, 3-year DFS rate for

negative PET-CT (71%) was higher than positive PET-CT scan (11%).

Ito *et al.* and Torizuka *et al.* has reported that SUV_{max} can provide prognostic survival estimates of at least 2 years.^[8,9] Similarly, in our analysis, better prognosis was observed in patients with lower SUV_{max} values as compared to those with higher SUV_{max} values ($P < 0.01$). Metabolic response indicates the aggressive behavior of the disease, necessitating aggressive treatment approach. As most of the recurrent disease is seen during 1st year posttreatment,^[3] induction of PET-CT as follow-up after treatment can provide early indication of metabolically active residual or recurrent disease. This coupled with histopathological evidence has a better prognostic implication.

Limitations of the study

A small cohort database was the major limitation of our study. We had statistically significantly comparable groups in terms of location and degree of differentiation of the primary head and neck carcinoma. However, based on the histopathological classification, our groups were not statistically comparable, since 91% of the patients had squamous cell carcinoma versus other histology seen.

Conclusion

¹⁸F-FDG PET-CT has diagnostic and prognostic implications in patients treated for head and neck cancer. With results of our study clearly showing a high NPV in treated patients with head and neck cancer, role of PET-CT is strongly advocated. Statistically significant DFS period also noted among patients with negative posttreatment scans.

Financial support and sponsorship

Nil.

Conflicts of interest

There are no conflicts of interest.

References

- Jemal A, Bray F, Center MM, Ferlay J, Ward E, Forman D. Global cancer statistics. *CA Cancer J Clin* 2011;61:69-90.
- Abraham J. Imaging for head and neck cancer. *Surg Oncol Clin N Am* 2015;24:455-71.
- Castaldi P, Leccisotti L, Bussu F, Miccichè F, Rufini V. Role of (18) F-FDG PET-CT in head and neck squamous cell carcinoma. *Acta Otorhinolaryngol Ital* 2013;33:1-8.
- Sanderson RJ, Ironside JA. Squamous cell carcinomas of the head and neck. *BMJ* 2002;325:822-7.
- Gupta T, Master Z, Kannan S, Agarwal JP, Ghosh-Laskar S, Rangarajan V, *et al.* Diagnostic performance of post-treatment FDG PET or FDG PET/CT imaging in head and neck cancer: A systematic review and meta-analysis. *Eur J Nucl Med Mol Imaging* 2011;38:2083-95.
- Ware RE, Matthews JP, Hicks RJ, Porceddu S, Hogg A, Rischin D, *et al.* Usefulness of fluorine-18 fluorodeoxyglucose positron emission tomography in patients with a residual structural abnormality after definitive treatment for squamous cell carcinoma of the head and neck. *Head Neck* 2004;26: 1008-17.
- Porceddu SV, Pryor DI, Burmeister E, Burmeister BH, Poulsen MG, Foote MC, *et al.* Results of a prospective study of positron emission tomography-directed management of residual nodal abnormalities in node-positive head and neck cancer after definitive radiotherapy with or without systemic therapy. *Head Neck* 2011;33:1675-82.
- Ito K, Shimoji K, Miyata Y, Kamiya K, Minamimoto R, Kubota K, *et al.* Prognostic value of post-treatment (18) F-FDG PET/CT for advanced head and neck cancer after combined intra-arterial chemotherapy and radiotherapy. *Chin J Cancer Res* 2014;26:30-7.
- Torizuka T, Tanizaki Y, Kanno T, Futatsubashi M, Naitou K, Ueda Y, *et al.* Prognostic value of 18F-FDG PET in patients with head and neck squamous cell cancer. *AJR Am J Roentgenol* 2009;192:W156-60.