

Assessment of smile architecture and pink aesthetics: A successful methodology in cosmetic dentistry

Shital Hungund, Dhwani Gohil, Rakesh Mishra

Department of Periodontology and Implantology, Darshan Dental College and Hospital, Loyara, Udaipur, Rajasthan, India

Address for correspondence:

Dr. Shital Hungund,
Prof and Head, Department of
Periodontology and Implantology,
Darshan Dental College and Hospital,
Loyara, Udaipur, Rajasthan, India.
E-mail: drdhwani611@gmail.com

ABSTRACT

Objective: Aesthetic restorative treatment plays a very essential role in smile appearance. The aim of this study is to assess smile architecture and periodontium outlook for aesthetic evaluation. **Materials and Methods:** One hundred subjects (50 women and 50 men) aged from 18 to 62 years were enrolled and photographed. Standardized digital photographs were taken to assess smile architecture and gingival biotype during regular and expanded smile. Smile was assessed on the basis of following criteria: 1) extremely high smile line; 2) high smile line; 3) moderate smile line; and 4) low smile line. Patients were also classified by age group and gender as follows: a) males aged from 18 to 30 years; b) females aged from 18 to 30 years; c) males aged 31 years and above; and d) females aged 31 years and above. Gingival biotype was analysed using visual assessment method. Statistical analysis was performed using Chi-square test to assess differences between groups. **Results:** Assessment revealed that subjects with regular smile had the following: Class 1, 2%; Class 2, 10%; Class 3, 45%; and Class 4, 43%. With expanded smile, subjects revealed the following: Class 1, 9%; Class 2, 13%; Class 3, 58%; and Class 4, 20%. The periodontal outlook was more prevalent in the expanded and regular smile for younger age group than the older one. Age and gender influenced the position of the smile architecture. About 80% of the subjects were concerned of aesthetics. **Conclusion:** Assessment of smile architecture and pink aesthetics becomes mandatory for both regular and expanded smile for both the genders.

Key words

Aesthetic, periodontium, smile, smile architecture

INTRODUCTION

A smile is considered a universal, friendly greeting in all cultures and modern society. It is regarded as one of the most important communication skills a person should pursue.^[1] Gingival smile line is an anatomical feature that exposes gingiva superior to maxillary anterior teeth.^[2] Improving smile aesthetics prior to restorative treatment is often one consideration that the patients seek.^[3] Assessment of smile provides information about the relationship between the teeth and surrounding pink tissue, and is a key element of diagnosis and treatment planning in cosmetic dentistry. It has been seen that cosmetic dentistry usually considers restorative and

orthodontic field. However, one finds that periodontics can also contribute immensely in improving the appearance of patients.^[4]

In particular, the periodontist can influence the appearance of the patient's smile.^[5]

The relationship between upper lip and display of gingival tissues and teeth defines that periodontal outlook depends on the smile architecture. An imaginary line following the lower margin of the upper lip, with a convex appearance is defined as smile line.^[6,7] Very less literature exists regarding periodontal outlook and smile architecture in relation to age and gender. Crispin and Watson reported that with maximal smiling, 84% of the participants revealed their gingival margin.^[6] But the report did not include information on individuals with lost interproximal papilla although the lack of papilla represented aesthetic damage.

The practitioner has to look not only at marginal gingiva display (the stage before the “gummy smile”), but also at the display of gingival embrasures to determine periodontium outlook. Secondly, the practitioner should consider both

Access this article online

Quick Response Code:



Website:
www.ejgd.org

DOI:
10.4103/2278-9626.103385

the regular smile [Figure 1] and the expanded smile [Figure 2] when assessing the position of the smile line, and even consider the difference in gingival display in relation to age and gender. When the practitioner asks a patient to smile, the patient usually takes a cautious attitude and reveals a more or less natural smile. However, outside of the office, the patient can reveal more periodontium by forcing the smile to the maximum degree of lip contraction, thereby making the smile less aesthetically pleasing.

The aim of this study is to assess smile architecture and periodontium outlook for aesthetic evaluation.

MATERIALS AND METHODS

The research proposal was approved by the ethical committee and informed consent was obtained from each subject.

Subjects

One hundred subjects of both the sexes were enrolled in this study. Subjects were divided into four groups: a) males (18–30 years), b) females (18–30 years), c) males (31 years and above), and females (31 years and above), with a mean age of 31.66 years. Groups consisted of 25 subjects each. The subjects with no facial disharmonies and with natural dentition without any prosthesis were photographed.

Technique to photograph

Standardized digital photographs were taken to assess smile architecture and gingival biotype during regular and expanded smile. The headrest was aligned to allow positioning of the head in the Frankfort horizontal plane to assure optimal angulation. Subjects were photographed for the regular and expanded smile. The architecture of the smile was determined from the pictures taken.

The smile was assessed on the basis of the following criteria:

Class 1: Extremely high smile line: More than 2 mm of marginal gingiva visible or more than 2 mm

apical to the cemento-enamel junction visible for the reduced but healthy periodontium. This could be the gummy smile [Figure 3a]

Class 2: High smile line: Between 0 and 2 mm of marginal gingiva visible or between 0 and 2 mm apical to the cemento-enamel junction visible for the reduced but healthy periodontium [Figure 3b]

Class 3: Moderate smile line: Gingival embrasures only visible [Figure 3c]

Class 4: Low smile line: Gingival embrasures and cemento-enamel junctions not visible [Figure 3d].

All the subjects were evaluated for the gingival biotype on the basis of thick or thin by visual assessment method according to age.

Statistical analysis

Descriptive analysis was performed with all data recorded. Chi-square test was applied for testing the difference between age and sexes. A probability of $P < 0.05$ was accepted to reject the null hypothesis.

RESULTS

The sample consisted of 50 women and 50 men, aged from 18 to 62 years (mean age: 31.66 years). The main result of this study is shown in Figure 4. Class 3 was the most frequent (45% for regular smile and 58% for expanded smile). Extremely high smile line during regular smile was 2% while during expanded smile was 9%. During regular smile, 43% had a low smile line while during expanded smile 20% had a low smile line. The gingival display was more in the expanded smile (Class 1 + Class 2 + Class 3 = 80%) than in the regular smile (Class 1 + Class 2 + Class 3 = 57%). During expanded smile, the cemento-enamel junctions were revealed in 22% of the subjects (Class 1 + 2).

The frequency distribution of the study population according to age and gender during regular and expanded smile is presented in Table 1. During regular smile, 35% women were more likely to show their periodontium

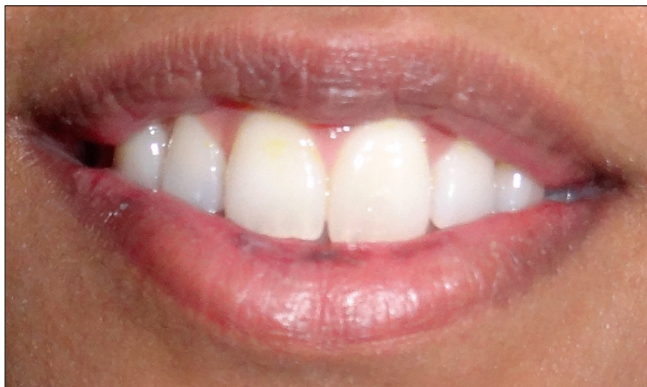

Figure 1: Regular smile

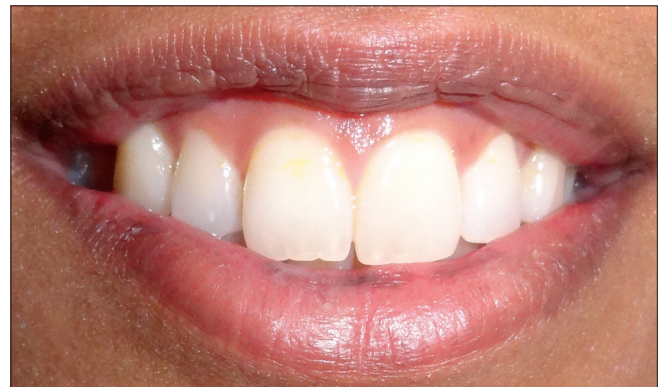

Figure 2: Expanded smile

(Class 1 + Class 2 + Class 3) than men (23%) [Figure 5]. The difference was significant. While during expanded smile, there was significant difference between women (45%) and men (35%) [Figure 6].

During regular smile, significant differences were observed in young participants compared with the two older participant groups [Figure 7]. The high smile line class had the lowest percentage in the younger subject

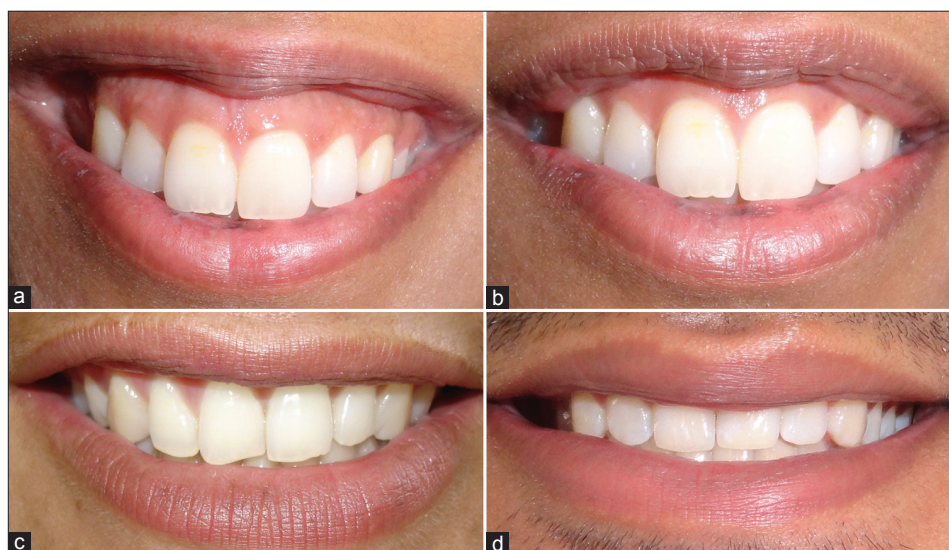

Figure 3: (a) Class 1; (b) Class 2; (c) Class 3; (d) Class 4

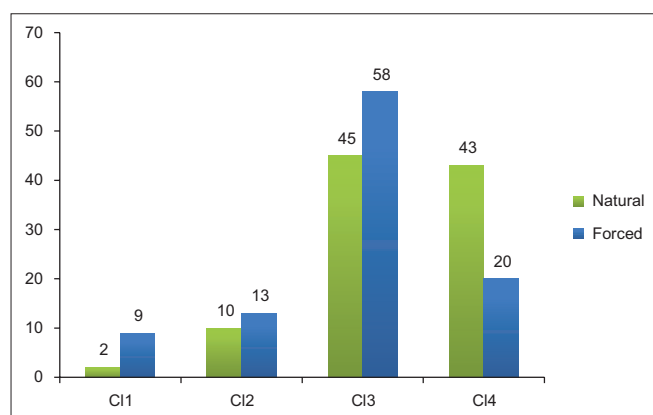


Figure 4: Frequency distribution on the study population according for the regular smile and the expanded smile

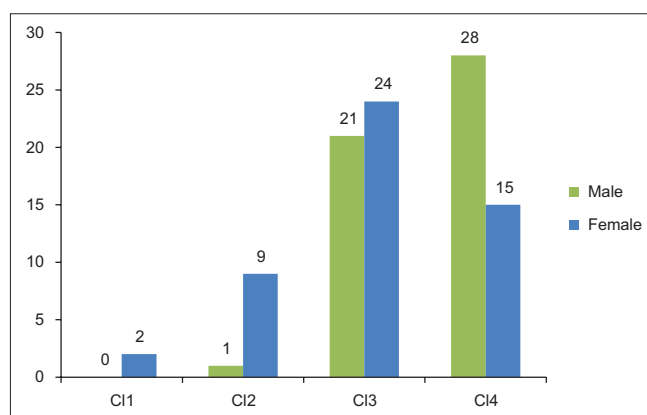


Figure 5: Frequency distribution for males and females during regular smile

Sex	Age (years)		Regular smile				Total	Expanded smile				Total
			CI 1	CI 2	CI 3	CI 4		CI 1	CI 2	CI 3	CI 4	
M	18-30	Count		1	12	12	25	2	1	19	3	25
		% of total		2.0	24.0	24.0	50.0	4.0	2.0	38.0	6.0	50.0
	31-62	Count		0	9	16	25	0	1	12	12	25
		% of total		0	18.0	32.0	50.0	0	2.0	24.0	24.0	50.0
Total	Count		1	21	28	50	2	2	31	15	50	
	% of total		2.0	42.0	56.0	100.0	4.0	4.0	62.0	30.0	100.0	
F	18-30	Count	1	2	16	10	29	4	2	21	2	29
		% of total	2	4.0	32.0	20.0	58.0	8.0	4.0	42.0	4.0	58.0
	31-62	Count	1	7	8	5	21	3	9	6	3	21
		% of total	2	14.0	16.0	10.0	42.0	6.0	18.0	12.0	6.0	42.0
	Total	Count	2	9	24	15	50	7	11	27	5	50
		% of total	4	18.0	48.0	30.0	100.0	14.0	22.0	54.0	10.0	100.0

group during regular and expanded smiles. They displayed their gingival embrasures in 49% of cases (Class 1 + Class 2 + Class 3) and their cemento-enamel junctions in 9% of cases (Class 1 + Class 2) during expanded smile [Figure 8].

No significant difference was noted in the gingival biotype of the subjects (mean age value being 31.66 years). Subjects younger than 45 years showed thin and scalloped gingival biotype with triangular tooth shape.

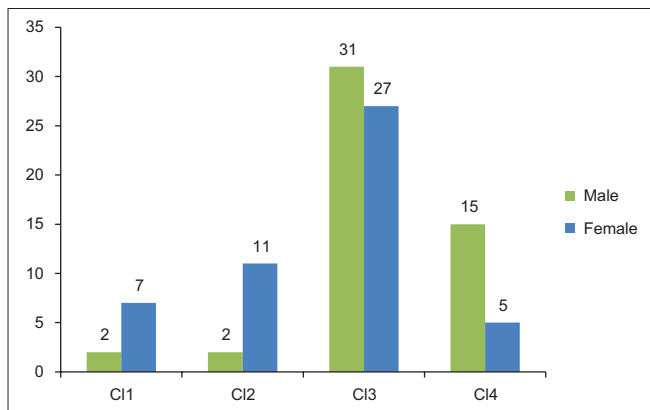


Figure 6: Frequency distribution for males and females during expanded smile

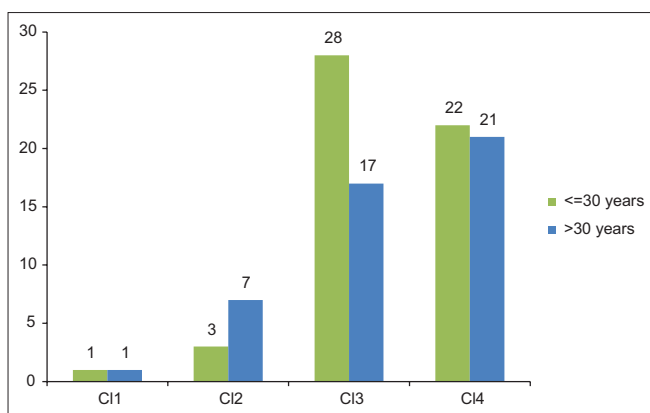


Figure 7: Frequency distribution for age groups during regular smile

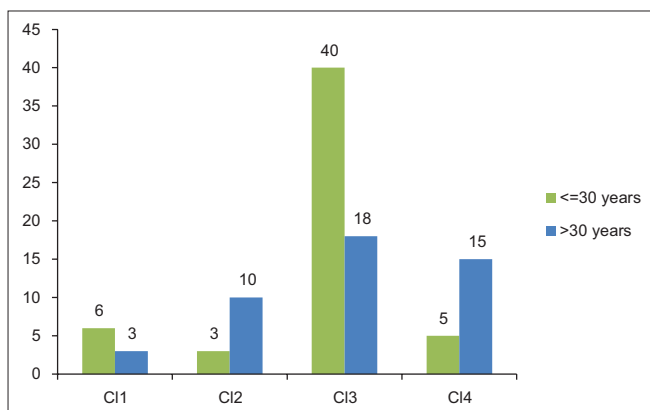


Figure 8: Frequency distribution for age groups during expanded smile

DISCUSSION

Aesthetic considerations in prosthetic restorations have become more important in making patients' decision for dental therapy. An attractive smile involves harmonious interaction of the lips, teeth, and surrounding gingival scaffold. Position of lip during smile defines the type of smile and influences the clinical and technical procedures required for aesthetic restorations.^[8] This study identified variations in smile line and gingival display amongst different age groups and gender. 80% of subjects displayed their gingiva during regular and expanded smile. This proportion is very important because this classification considered the whole papilla and the forced smile.

In the present study, the periodontium or its supposed localization was visible for participants in Class 1, Class 2, and Class 3. Using this criterion for smile line, Class 3 allowed for the detection of subjects whose interproximal papilla was exposed, but not the gingival margin. Class 3 was important for aesthetic appearance and individual self-perception. According to the data collected, Class 3 was most frequently encountered during regular and expanded smile.

For an attractive smile, gingival health and appearance are essential components.^[7,9,10] Black triangles formed due to loss of papilla are considered unaesthetic.^[11] It has been reported that the papilla could enhance a youthful appearance as a complementary factor in age interpretation and has been considered a critical asset in dental aesthetics.^[12,13] In this study, we have considered the gingival embrasure with the presence or absence of papilla. More importantly, younger and older age groups were compared for smile architecture and changes in it with aging.

However, there are no data comparing the smile line at different ages and the gender distribution. The periodontist should consider the maximal gingiva-revealing smile. In the present study, the subjects were photographed during regular smile and during maximal smile (also called the expanded smile).

In a study, Jensen *et al.* reported that about 70% of patients revealed more than 25% of their periodontium in their usual contact smile.^[14] This data cannot be compared as we do not know how many subjects had revealed their gingiva. In the present study, 80% of participants had visible gingival embrasures and/or marginal gingiva.

It has been noted that age and gender have an influence on satisfaction with oral appearance.^[15] In the present study, the position of the smile line was significantly lower with age. Authors suggested that the elasticity of soft tissues might decrease with age owing to age-related

alterations in the connective tissue metabolism, possibly resulting in “sinking” of the facial tissues.^[14]

Higher smile line position was more seen in women compared to men. Comparing the age groups, 18–30 years old group presented higher smile line for expanded smile in both the genders. Women revealed more gingival margin than men during maximal smile and the position of the smile line was lower with age. Hence, we conclude that age and gender influence the position of the smile line.

CONCLUSIONS

Women display a greater amount of gingiva during smiling than men. Around 80% of subjects revealed their gingiva during maximal smile which is a very high rate. We conclude that gingival display must be examined during expanded smile for aesthetic consideration. This indicates that pink aesthetics is a paramount factor in cosmetic dentistry for restorative dentists and periodontists. Attention must be paid to the fact that the visual impact of the smile is not associated exclusively with the beauty of individual teeth, but also with the periodontium.

REFERENCES

1. Maulik C, Nanda R. Dynamic smile analysis in young adults. *Am J Orthod Dentofacial Orthop* 2007;132:307-15.
2. Peck S, Peck L, Kataja M. The gingival smile line. *Angle Orthod* 1992;62:91-100.
3. Charreul S, Perez C, Foti B, Camps J, Monnet Corti V. Gingival contour assessment: Clinical parameters useful for esthetic diagnosis and treatment. *J Periodontol* 2008;79:795-801.
4. Henry M, Niles M. The periodontist and cosmetic dentistry. *J Periodontol* 1961;32:82-4.
5. Garber DA, Salama MA. The aesthetic smile: Diagnosis and treatment. *Periodontol* 2000 1996;11:18-28.
6. Crispin BJ, Watson JF. Margin placement of esthetic veneer crowns. Part II: Posterior tooth visibility. *J Prosthet Dent* 1981;45:389-91.
7. Townsend CL. Resective surgery: An esthetic application. *Quintessence Int* 1993;24:535-42.
8. Dunn WJ, Murchison DF, Broome JC. Esthetics: Patients' perceptions of dental attractiveness. *J Prosthodont* 1996;5:166-71.
9. Morley J, Eubank J. Macroesthetic elements of smile design. *J Am Dent Assoc* 2001;132:39-45.
10. Dolt AH 3rd, Robbins JW. Altered passive eruption: An etiology of short clinical crowns. *Quintessence Int* 1997;28:363-72.
11. Chiche G, Pinault A. *CriteÅresartistiquesetscientifiques en dentisterieesthetique*. Paris: CDP; 1995. p. 177-94.
12. Tarnow DP, Eskow RN, Zanzok J. Aesthetics and implant dentistry. *Periodontol* 2000 1996;11:85-4.
13. Lombardi RE. The principles of visual perception and their clinical application to denture esthetics. *J Prosthet Dent* 1973;29:358-85.
14. Jensen J, Joss A, Lang NP. The smile line of different ethnic groups in relation to age and gender. *Acta Med Dent Helv* 1999;4:38-6.
15. Neumann LM, Christensen C, Cavanaugh C. Dental esthetic satisfaction in adults. *J Am Dent Assoc* 1989;118:565-70.

How to cite this article: Hungund S, Gohil D, Mishra R. Assessment of smile architecture and pink aesthetics: A successful methodology in cosmetic dentistry. *Eur J Gen Dent* 2012;1:85-9.

Source of Support: Nil, **Conflict of Interest:** None declared.

Author Help: Online submission of the manuscripts

Articles can be submitted online from <http://www.journalonweb.com>. For online submission, the articles should be prepared in two files (first page file and article file). Images should be submitted separately.

- 1) **First Page File:**
Prepare the title page, covering letter, acknowledgement etc. using a word processor program. All information related to your identity should be included here. Use text/rtf/doc/pdf files. Do not zip the files.
- 2) **Article File:**
The main text of the article, beginning with the Abstract to References (including tables) should be in this file. Do not include any information (such as acknowledgement, your names in page headers etc.) in this file. Use text/rtf/doc/pdf files. Do not zip the files. Limit the file size to 1 MB. Do not incorporate images in the file. If file size is large, graphs can be submitted separately as images, without their being incorporated in the article file. This will reduce the size of the file.
- 3) **Images:**
Submit good quality color images. Each image should be less than 4096 kb (4 MB) in size. The size of the image can be reduced by decreasing the actual height and width of the images (keep up to about 6 inches and up to about 1800 x 1200 pixels). JPEG is the most suitable file format. The image quality should be good enough to judge the scientific value of the image. For the purpose of printing, always retain a good quality, high resolution image. This high resolution image should be sent to the editorial office at the time of sending a revised article.
- 4) **Legends:**
Legends for the figures/images should be included at the end of the article file.