

# Endodontic management of maxillary second molar with 2 palatal roots and root canals: A rare case report

Padmanabh Jha, Vineeta Nikhil, Mesha Jha

Department of Conservative Dentistry and Endodontics, Subharti Dental College, Swami Vivekanand Subharti University, Subhartipuram, Meerut, Uttar Pradesh, India

Address for correspondence:

Dr. Padmanabh Jha,  
Department of Conservative Dentistry  
and Endodontics, Subharti Dental College,  
Swami Vivekanand Subharti University,  
Subhartipuram, N.H. 58, Delhi Haridwar  
Bypass, Meerut, Uttar Pradesh, India.  
E-mail: drpadmanabh.jha@gmail.com

## ABSTRACT

This case report presents the endodontic management of a maxillary second molar with 2 palatal roots, which have canals with separate orifices and apical foramen. The diagnosis was confirmed by the clinical and radiographic examination of the tooth. Root-canal treatment was performed using rotary instrumentation with Protaper files and obturated with corresponding protaper gutta percha cones and AH Plus sealer.

## Key words

Maxillary second molar, root canal anatomy, 2 palatal roots

## INTRODUCTION

The goal of root canal treatment is to clean the root canal system as thoroughly as possible and to fill it 3 dimensionally.<sup>[1]</sup> In-depth knowledge of the root canal anatomy of each tooth is crucial in order to reach this goal.

The maxillary first molar most commonly has 3 or 4 canals, with 1 canal in both the palatal and distobuccal roots and 1 or 2 in the mesiobuccal root. The incidence of a mesiolingual canal has been reported between 18%<sup>[2]</sup> and 96.1%<sup>[3]</sup> (Hartwell and Bellizzi 1982, Kulild and Peters 1990). Cecic *et al.* (1982),<sup>[4]</sup> Jacobsen and Nii (1994),<sup>[5]</sup> and Stone and Stroner (1981)<sup>[6]</sup> found cases of maxillary first molars, in which the palatal canal contained one orifice, a bifurcated canal, and 2 separate foramina. Beatty (1984)<sup>[7]</sup> presented a case of a maxillary first molar with 5 canals, 3 of which were located in the mesiobuccal root. Bond *et al.* (1988)<sup>[8]</sup> reported a case of a maxillary first molar with 6 canals: Two canals with separate foramina in the mesiobuccal root, 2 canals with separate foramina in the distobuccal root, and 2 canals joining in

the apical third of the palatal root. Hulsmann (1997)<sup>[9]</sup> presented a maxillary first molar with 2 distinct canals in the distobuccal root. Slowey (1979)<sup>[10]</sup> showed a case of a maxillary molar with 2 palatal canals and separate foramina. Martinez-Berna and Ruiz-Badanelli (1983)<sup>[11]</sup> reported 3 cases of maxillary first molars with 6 canals: Three canals in the mesiobuccal root, 2 in the distobuccal root, and 1 in the palatal root and finally, Wong (1991)<sup>[12]</sup> reported a case, in which the palatal root had a single canal orifice, a trifurcation in the apical third, and 3 separate foramina.

The frequency of 2 palatal roots is low; however, a few cases have been reported in the literature [Table 1]. Stone and Stroner (1981)<sup>[6]</sup> reported variations of the palatal root of maxillary molars, such as a single root

**Table 1: Reported canal configuration of maxillary first molar**

Year	Author	Palatal root	Mesio-buccal root	Disto-buccal root
1979	Slowey	2	1	1
1979	Thews	2	1	1
1982	Cecic	2	2	1
1983	Martinez-Berna	1	3	2
1984	Beatty	1	3	1
1988	Bond	2	2	2
1991	Wong	3	1	1
1994	Jacobsen	2	1	1
1997	Hulsmann	1	1	2

### Access this article online

#### Quick Response Code:



Website:  
www.ejgd.org

DOI:  
10.4103/2278-9626.105387

with 2 separate orifices, 2 separate canals and 2 separate foramina; 2 separate roots, each with 1 orifice, 1 canal and 1 foramen; single root with 1 orifice, a bifurcated canal and 2 separate foramina. Benenati (1985)<sup>[13]</sup> reported a maxillary second molar with 2 palatal roots and a groove located in this side of the tooth. According to the author, this groove was the result of the formation of 2 palatal roots. Christie *et al.* (1991)<sup>[14]</sup> analyzed endodontic treatment in 16 maxillary molars and of 6 extracted teeth with 2 palatal roots and classified these 22 molars into 3 types (I-III), according to the root separation level and their divergences. According to this same classification, Di Fiore (1999a,b)<sup>[15,16]</sup> classified as type II : A case of a maxillary first molar with 4 independent roots. Anatomical variations can occur in maxillary permanent molars. Although not very common, Christie *et al.* (1991)<sup>[14]</sup> speculated that maxillary molars with 2 palatal roots may be encountered once every 3 years in a busy endodontic practice. Peikoff *et al.* (1996)<sup>[17]</sup> observed that 1.4% of maxillary molars might have second palatal roots.

The rarity of literature on this anatomical variation has led us to report this case of maxillary second molar with 2 palatal roots.

## CASE REPORT

A 28-year-old Indian male patient presented with pain, both spontaneous and temperature related, on the right side of the face for several days. The patient's medical history was non-contributory. Clinically, the right maxillary second molar had a deep carious lesion. Electric pulp testing (Vitality Scanner; Analytic Technology, Glendora, CA) was indicative of irreversible pulp damage. The clinical diagnosis was irreversible pulpitis. A pre-treatment radiograph was taken, [Figure 1] and conventional coronal access was performed. The patient received local anesthesia of 2% lidocaine with 1:100,000 epinephrine. After removing pulpal tissues located in the pulp chamber, clinical evaluation of the internal anatomy revealed 3 principal root canal systems: MB, distobuccal (DB), and

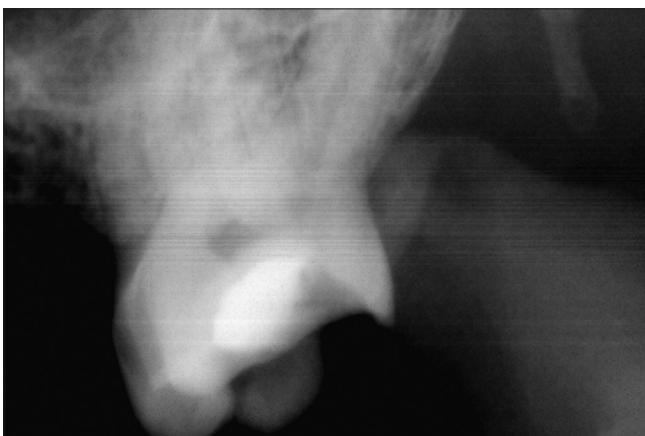

Figure 1: Pre-operative radiograph

palatal. After probing with a Hu-Friedy (Chicago, IL) DG 16 endodontic explorer, a small hemorrhagic point was noted near the orifice of the main palatal canal. A small amount of dentin that was occluding the orifice of the second palatal canal was removed with the help of Endo Access bur no. A0164 (Dentsply Maillefer, Ballaigues, Switzerland). The conventional triangular access was modified to a trapezoidal shape with the help of slow-speed diamond KGS3203 (Dentsply Maillefer) to improve access to the additional canal. The pulp was extirpated, and the appointment was then concluded. At the next visit, the working lengths of each canal were estimated by means of an electronic apex locator (Root ZX; Morita, Tokyo, Japan) and then confirmed by a radiograph [Figure 2]. The canals were initially instrumented with #15 nickel-titanium files (Dentsply Maillefer). Biomechanical preparation was done using the crown-down technique with rotary Protaper files (Dentsply/Maillefer, Ballaigues, Switzerland) attached to Xsmart endomotor (Dentsply/Maillefer, Ballaigues, Switzerland). Apical preparation was performed till F2. Canal preparation was accompanied with irrigation using 2.5% NaOCl and EDTA. Obturation was performed with the aid of corresponding Protaper gutta-percha cones (Dentsply/Maillefer, Ballaigues, Switzerland) and AH Plus sealer (Dentsply/Maillefer, Ballaigues, Switzerland). Final radiograph was taken to establish the quality of the obturation [Figure 3]. After completion of root canal treatment, the tooth was restored with a posterior composite filling (P60; 3M Dental Products, St Paul, MN).

Radiographs taken during treatment [Figure 2] showed 2 independent palatal roots, which were relatively broad, presenting 2 distinct foramina. This indicates a type II tooth, according to the classification of Christie *et al.* (1991).

## DISCUSSION

Anatomical variations can occur in maxillary permanent molars. The tooth described in this case report had totally separated palatal roots, each with a distinct root

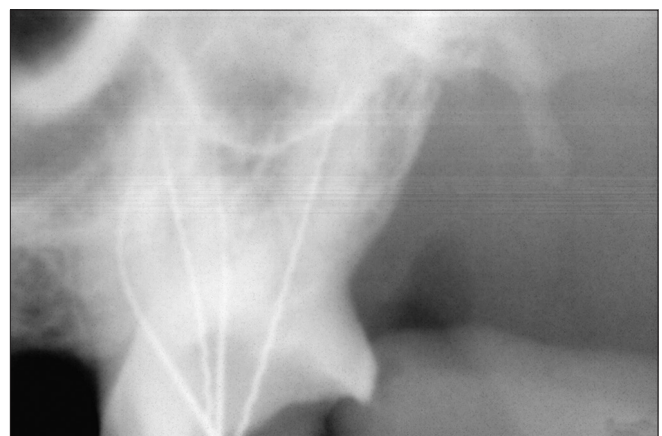
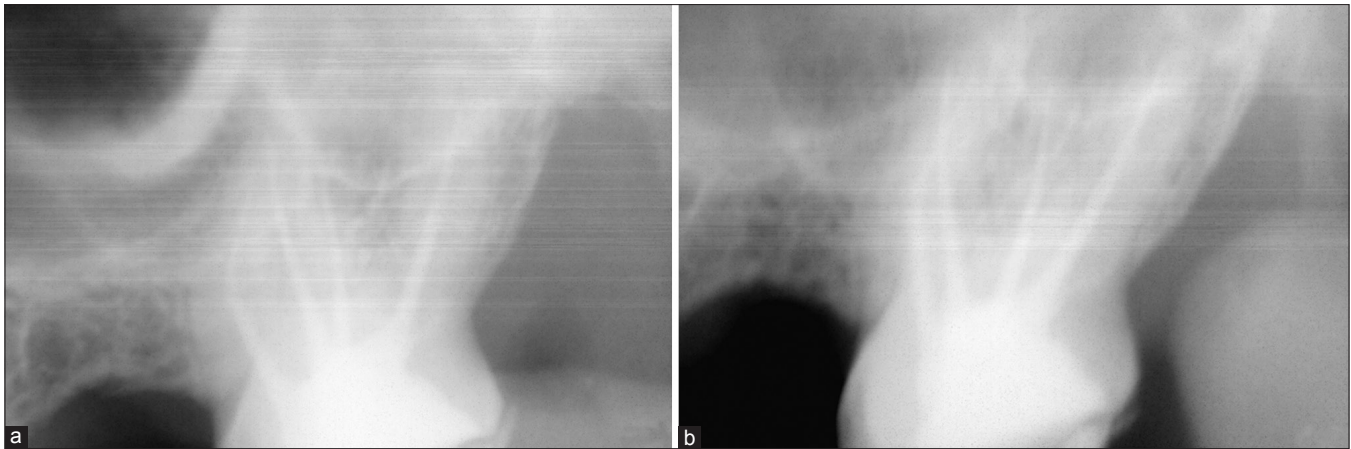

Figure 2: Working length radiograph



**Figure 3:** Post-operative radiographs (a) immediately after treatment, (b) after two months

canal. The majority of endodontic literature describes the maxillary molars as having 3 roots with 3 or 4 root canals.<sup>[12]</sup> The prevalence of maxillary second molars with 2 palatal canals is rare. Also, literature is scarce regarding presence of 2 separate palatal roots, which have canals with separate orifices and separate foramen.

When indistinct images of palatal roots are presented in pre-operative X-ray images, the clinician must consider the possibility of 2 palatal roots. Dissociation of images must be performed and, if this anomaly is confirmed, a broad coronal access will allow the correct localization of root canals.<sup>[18]</sup> Shape of pulp cavity is variable, making every treatment unique. Properly designed and prepared access cavities help the clinician to diagnose and negotiate the root canal morphology.<sup>[19]</sup> In the presented case, a large access was required to locate the 2 palatal canals. The access cavity on maxillary molars exhibiting 2 palatal canals should be wider than usual on the palatal aspect. The access outline will be trapezoidal rather than triangular. In the current case, the 2 palatal orifices were also found to be well-developed and large. Treatment sequence and prognosis for molars with 2 palatal canals should be considered to be the same as those for any maxillary molar.<sup>[20]</sup> A clinician should open his/her mind to the various possible canal morphologies and should not stick only to a limited and standard number of canal patterns. In certain conditions, the root canals might be left untreated during the endodontic therapy if the practitioner is unable to detect their presence. These undetected extra roots or root canals are a major reason for the failure of endodontic treatment.<sup>[20]</sup> Hence, the ability to locate all the canals in the root canal system is an important factor in determining the eventual success of a case.

## CONCLUSION

Anatomic variations can occur in any tooth, and maxillary second molar is no exception. Careful examination of radiographs and internal anatomy of teeth is essential. Although such cases occur infrequently, the clinician

should be aware of them when considering endodontic treatment of a maxillary first molar.

## REFERENCES

1. Cohen S, Burns RC. Pathways of the Pulp, 7<sup>th</sup> ed. St. Louis, Missouri, USA: Mosby Co; 1998.
2. Hartwell G, Bellizzi R. Clinical investigation of *in vivo* endodontically treated mandibular and maxillary molars. J Endod 1982;8:555-7.
3. Kulild JC, Peters DD. Incidence and configuration of canal systems in the mesiobuccal root of maxillary first and second molars. J Endod 1990;16:311-7.
4. Cecic P, Hartwell G, Bellizzi R. The multiple root canal system in the maxillary first molar: A case report. J Endod 1982;8:113-5.
5. Jacobsen EL, Nii C. Unusual palatal root canal morphology in maxillary molars. Endod Dent Traumatol 1994;10:19-22.
6. Stone LH, Stroner WF. Maxillary molars demonstrating more than one palatal root canal. Oral Surg Oral Med Oral Pathol 1981;51:649-52.
7. Beatty RG. A five-canal maxillary first molar. J Endod 1984;10:156-7.
8. Bond JL, Hartwell G, Portell FR. Maxillary first molar with six canals. J Endod 1988;14:258-60.
9. Hulsmann M. A maxillary first molar with two disto-buccal root canals. J Endod 1997;23:707-8.
10. Slowey RR. Root canal anatomy- road map to successful endodontics. Dent Clin North Am 1979;23:555-73.
11. Martinez-Berna A, Ruiz-Badanelli P. Maxillary first molars with six canals. J Endod 1983;9:375-81.
12. Wong M. Maxillary first molar with three palatal canals. J Endod 1991;17:298-9.
13. Benenati FW. Maxillary second molar with two palatal canals and a palatogingival groove. J Endod 1985;11:308-10.
14. Christie WH, Peikoff MD, Fogel HM. Maxillary molars with two palatal roots: A retrospective clinical study. J Endod 1991;17:80-4.
15. Di Fiore PM. A four-rooted quadrangular maxillary molar. J Endod 1999;25:695-7.
16. Di Fiore PM. Complications of surgical crown lengthening for a maxillary molar with four roots: A clinical report. J Prosthet Dent 1999;82:266-8.
17. Peikoff MD, Christie WH, Fogel HM. The maxillary second molar: Variations in the number of roots and canals. Int Endod J 1996;29:365-9.
18. Baratto-Filho F, Fariniuk LF, Ferreira EL, Pecora JD, Cruz-Filho AM, Sousa-Neto MD. Clinical and macroscopic study of maxillary molars with two palatal roots. Int Endod J 2002;35:796-801.

19. Reeh ES. Seven canals in a lower first molar. *J Endod* 1998;24:497-9.
20. Vivek Aggarwal, Mamta Singla, Ajay Logani, Naseem Shah. Endodontic Management of a Maxillary First Molar with Two Palatal Canals with the Aid of Spiral Computed Tomography: A Case Report. *J Endod* 2009;35:137-9.

**How to cite this article:** Jha P, Nikhil V, Jha M. Endodontic management of maxillary second molar with 2 palatal roots and root canals: A rare case report. *Eur J Gen Dent* 2012;1:197-200.

**Source of Support:** Nil, **Conflict of Interest:** None declared.

### Author Help: Online submission of the manuscripts

Articles can be submitted online from <http://www.journalonweb.com>. For online submission, the articles should be prepared in two files (first page file and article file). Images should be submitted separately.

1) **First Page File:**

Prepare the title page, covering letter, acknowledgement etc. using a word processor program. All information related to your identity should be included here. Use text/rtf/doc/pdf files. Do not zip the files.

2) **Article File:**

The main text of the article, beginning with the Abstract to References (including tables) should be in this file. Do not include any information (such as acknowledgement, your names in page headers etc.) in this file. Use text/rtf/doc/pdf files. Do not zip the files. Limit the file size to 1 MB. Do not incorporate images in the file. If file size is large, graphs can be submitted separately as images, without their being incorporated in the article file. This will reduce the size of the file.

3) **Images:**

Submit good quality color images. Each image should be less than 4096 kb (4 MB) in size. The size of the image can be reduced by decreasing the actual height and width of the images (keep up to about 6 inches and up to about 1800 x 1200 pixels). JPEG is the most suitable file format. The image quality should be good enough to judge the scientific value of the image. For the purpose of printing, always retain a good quality, high resolution image. This high resolution image should be sent to the editorial office at the time of sending a revised article.

4) **Legends:**

Legends for the figures/images should be included at the end of the article file.