

## A maxillary central incisor with four root canals

Fábio de Almeida-Gomes, Claudio Maniglia-Ferreira, Marcelo D. M. Vitoriano<sup>1</sup>,  
Bruno C. de Sousa<sup>2</sup>, Roberto A. dos Santos<sup>3</sup>, Marco A. H. Duarte<sup>3</sup>

University of Fortaleza, <sup>2</sup>Federal University of Ceará, Ceará, <sup>3</sup>Department of Endodontics, University of Pernambuco, Pernambuco, <sup>4</sup>Department of Endodontics, University of São Paulo, São Paulo, Brazil

Address for correspondence:

Dr. Fábio de Almeida-Gomes,  
Rua Paula Ney, 925 apt 501, Aldeota  
Fortaleza, Ceará, Brazil.  
E-mail: fabiogomesce@yahoo.com.br

### ABSTRACT

The objective of the present study is to present a case report of endodontic treatment of a maxillary central incisor with 1 root and 4 root canals. The success of endodontic treatment requires knowledge of dental anatomy and its variations. This clinical article reports an unusual anatomy detected in a maxillary central incisor with 4 root canals with an associated periapical lesion. The incidence of 4 root canals in this tooth is rare. However, it must be taken into consideration, the clinical and radiographic evaluations during the endodontic treatment in order to enhance the diagnostic. Many times, the presence of a supernumerary canal is noticed only after canal treatment due to continuing post-operative discomfort or treatment failure.

### Key words

Dental anatomy, maxillary central incisor, root canal, tooth morphology

### INTRODUCTION

The main objective of endodontic treatment is the thorough mechanical and chemical cleaning of the entire pulp space, to achieve an appropriate disinfection degree for after filling, with an inert material and a coronal filling, preventing the ingress of micro-organisms.<sup>[1]</sup>

One of the main reasons associated to endodontic failure is the persistence of microbial infection in the root canal system.<sup>[2]</sup>

However, the persistence of microbial infection can be related to many reasons, such as diagnosis mistakes, debridement and shaping errors in the root canal systems, instrument fractures, unsatisfactory restorations, and anatomic variations.

Thus, the knowledge of the internal dental anatomy and its variations are extremely important for correct endodontic treatment.<sup>[3]</sup>

These variations can also be found in the maxillary incisors.<sup>[3-6]</sup>

The maxillary incisors normally show 1 root with 1 canal. However, in the literature, case reports can be found which described maxillary anterior teeth with 2 canals in 1 or 2 separated roots.<sup>[3,5,7,8]</sup> Gondim Jr, *et al.*<sup>[6]</sup> presenting maxillary central incisors with 3 root canals.

The objective of the present study is to present a clinical case of endodontic treatment of a maxillary central incisor with 1 root and 4 root canals.

### CASE REPORT

A 26-year-old woman was referred to the University of Fortaleza's clinic for endodontic treatment of the maxillary central incisor (tooth 21). She reported a previous trauma in the area, about 2 years before searching for treatment. The pulp sensibility test was negative, suggesting pulp necrosis. A clinical examination revealed swelling and pain when the tooth area was touched. A radiographic examination revealed radiolucency around the root canal, an unusual root anatomy, and external root resorption [Figure 1]. From the clinical and radiographic findings, the maxillary central incisor was diagnosed as an acute periapical abscess, with an aberrant root canal system, for which root canal treatment was planned.

The patient was administered local anesthesia (2% lignocaine with 1:100,000 epinephrine). The tooth was then accessed under rubber dam isolation after drainage of the abscess [Figure 2]. A 2% chlorhexidine gel was used as an intra-canal medication for 7 days.

Through a microscopic examination, a calcification

Access this article online	
Quick Response Code:	Website: www.ejgd.org
	DOI: 10.4103/2278-9626.105388

was identified, which subdivided the root canal into 4 canals [Figure 3]. The working length was determined by an electronic apex locator (Root ZX; J Morita, Tokyo, Japan) and radiographically confirmed [Figure 4]. The canals were cleaned and shaped with K<sup>[3]</sup> nickel-titanium rotatory instruments (SybronEndo, USA). Saline solution and 2% chlorhexidine gel were used as irrigants. The canals were filled with a Taggers technique using gutta-percha points and root canal sealer (Rickerts Sealer, Pulp Canal Sealer EWT, SybronEndo, USA). After filling, the final radiograph showed the 4 root canals [Figure 5]. At the 12 month up, the tooth was asymptomatic and radiographic findings suggested partial resolution of the periapical lesion [Figure 6].

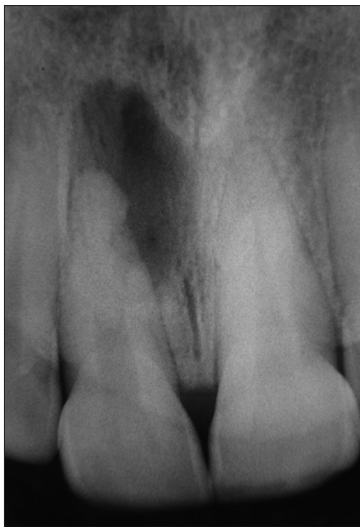## DISCUSSION

Most endodontic and anatomy texts describe the human maxillary central incisors with a single root and a

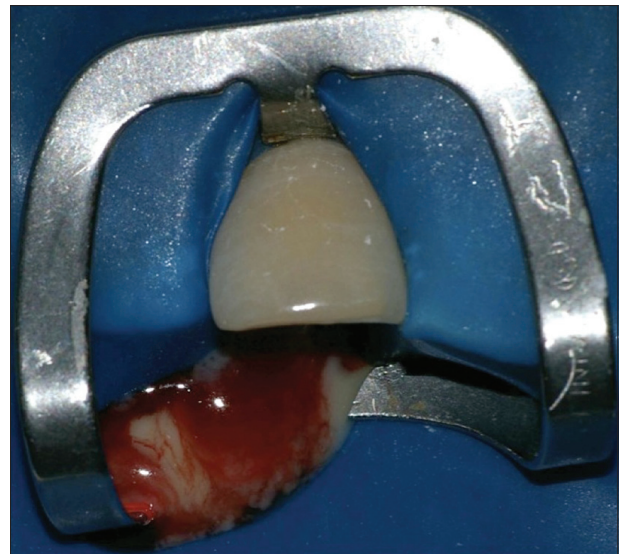
single canal.<sup>[9]</sup> The case reports an unusual case of a maxillary central incisor with 4 root canals without a morphological anomaly of the crown. Cases reporting unusual morphology have an important didactic value of enhancing the possibility of anatomical variations. According to the literature, there are no limits for the morphological variability. Their documentation in case reports may facilitate the recognition and successful management of similar cases that should require endodontic therapy.

There were few case reports describing an additional canal in the central maxillary incisors,<sup>[3,5,6,10]</sup> and most of them present morphological alterations, such as macrodontia, fusion, and a geminated tooth.<sup>[11,12]</sup>

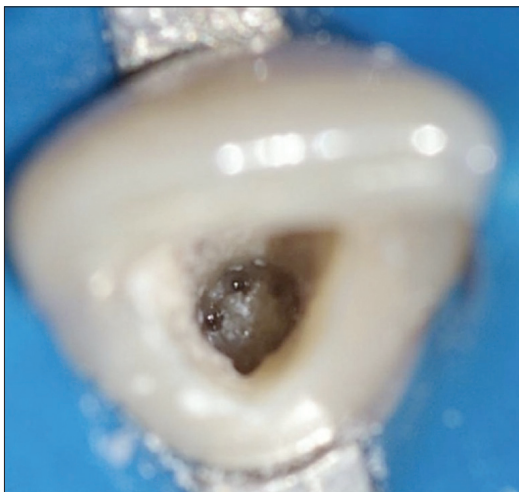According to Leonardo,<sup>[11]</sup> an inability to detect, locate, negotiate, and instrument all root canals may lead to endodontic failure. Textbooks describing details of



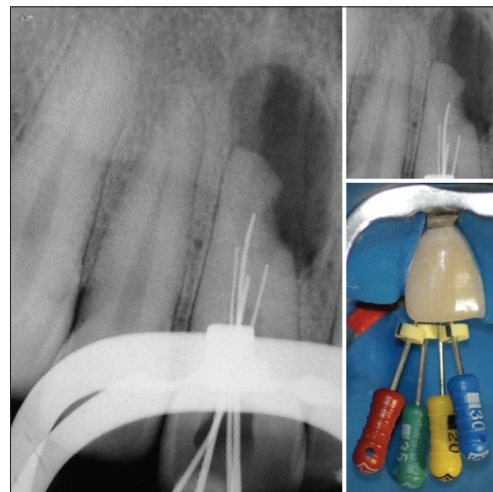
**Figure 1:** Radiographic exam revealed radiolucency around the root canal, an unusual root anatomy, and external root resorption



**Figure 2:** Drainage of the abscess



**Figure 3:** Root canal divided into 4 canals



**Figure 4:** Four canals radiographically confirmed

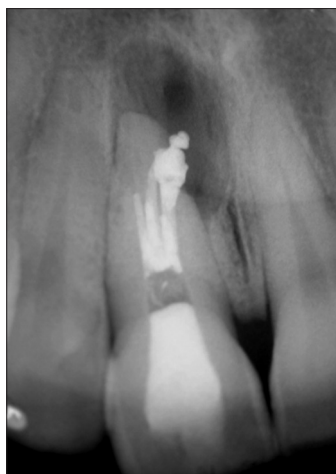

Figure 5: After filling, the final radiograph showed the 4 root canals

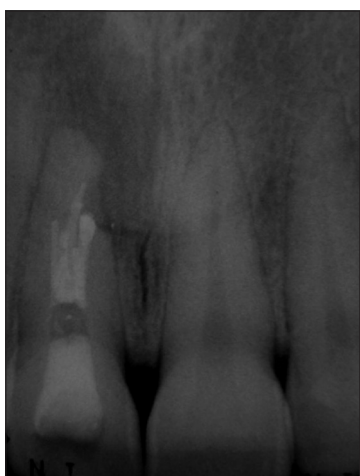

Figure 6: 12 month follow-up

the “typical morphology” of any tooth are easily found. However, case reports presenting variations and/or irregularities of the pulp space are not easily found, but they should be, in order to help similar cases.

Accurate pre-operative radiographs, straight and angled, using a parallel technique and the use of a dental microscope, are essential in providing clues to the number of root canals.

Endodontic success in teeth with a number of canals above that normally found requires a correct diagnosis and careful clinical radiographic inspection. Morphological

variations in pulpal anatomy must be considered before the treatment begins. The case presented a maxillary central incisor with 4 root canals.

## CONCLUSION

Knowledge of dental anatomy is fundamental for a good endodontic practice. When root canal treatment has to be performed, the clinician should be aware that both external and internal anatomy may be abnormal. The frequency of maxillary first molars with 4 root canals is rare; however, each case should be investigated carefully, clinically, and radiographically to detect the possible presence of anatomical anomalies.

## REFERENCES

1. Vertucci FJ. Root canal morphology and its relationship to endodontic procedures. *Endod Topics* 2005;10:3-29.
2. Nair PN. On the causes of persistent apical periodontitis: A review. *Int Endod J* 2006;39:249-81.
3. Sponchiado EC Jr, Ismail HA, Braga MR, Carvalho FK, Simões CA. Maxillary central incisor with two root canals: A case report. *J Endod* 2006;32:1002-4.
4. Kottoor J, Murugesan R, Albuquerque DV. A maxillary lateral incisor with four root canals. *Int Endod J* 2012;45:393-7.
5. Almeida-Gomes F, Guimarães NL, Maniglia-Ferreira C, Santos RA, Vitoriano MM, Sousa BC. Two root canals in maxillary central incisor. *RSBO* 2010;8:341-4.
6. Gondim E Jr, Setzer F, Zingg P, Karabucak B. A maxillary central incisor with three root canals: A case report. *J Endod* 2009;35:1445-7.
7. Benenati FW. Endodontic treatment of a maxillary central incisor with two separate roots: Case report. *Gen Dent* 2006;54:265-6.
8. Yavuz MS, Keleş A, Özgöz M, Ahmetoğlu F. Comprehensive treatment of the infected maxillary lateral incisor with an accessory root. *J Endod* 2008;34:1134-7.
9. Vertucci FJ. Root canal anatomy of the human permanent teeth. *Oral Surg Oral Med Oral Pathol* 1984;58:589-99.
10. Rodrigues EA, Silva SJ. A case of unusual anatomy: Maxillary central incisor with two root canals. *Int J of Morphol* 2009;27:827-30.
11. Libfeld H, Stabholz A, Friedman S. Endodontic therapy of bilateral geminated permanent maxillary central incisor. *J Endod* 1986;12:214-6.
12. Cimili H, Kartal N. Endodontic treatment of unusual central incisors. *J Endod* 2002;28:480-1.

**How to cite this article:** Almeida Gomes Fd, Maniglia Ferreira C, Vitoriano MD, de Sousa BC, dos Santos RA, Duarte MA. A maxillary central incisor with four root canals. *Eur J Gen Dent* 2012;1:201-3.

**Source of Support:** Nil, **Conflict of Interest:** None declared.