

# Evaluation of stability of immediately placed implants in infected sockets

Uma Shankar Pal, Nimisha Singh, R. K. Singh, Shadab Mohammad, Laxman R. Malkunje, Parveen Akhtar Loan<sup>1</sup>

Department of Oral and Maxillofacial Surgery, K. G. Medical University, Lucknow, Uttar Pradesh, <sup>1</sup>Government Dental College, Jammu, India

Address for correspondence:

Dr. Uma Shankar Pal,  
Department of Oral and Maxillofacial  
Surgery, K.G. Medical University,  
Lucknow - 226 003, Uttar Pradesh, India.  
E-mail: uspalkgmc@yahoo.co.in

## ABSTRACT

**Purpose:** To describe a protocol for the immediate placement of implant into the infected alveolar socket. **Materials and Methods:** In this study, a total number of 40 implants were placed immediately into the extraction sockets. Each case had a different periapical condition (acute, endodontic and periodontal infection). Great care had been taken in debridement of the socket, extraction of tooth/teeth and guided bone regeneration along with the use of pre-operative and post-operative anti-microbial agent. **Results:** All except three implants were osseointegrated within 6 months to 1 year. The complications were due to the extraction procedure and bone regeneration process. **Conclusion:** Predisposing factors for failures are incomplete debridement of the socket, poor oral hygiene, incomplete closure of the wound, and systemic factors like hormones. From this study, we may conclude that immediate implants are a viable treatment option for patients with periapical infections.

## Key words

Alveolar socket, dental implants, periapical pathology

## INTRODUCTION

Immediate implants are often deferred or avoided at a site where infection is present because of the fear of failure. Recent comparative studies have concluded that similar success rates have been reported for implants placed in infected sites compared to implants placed in non-infected sites.<sup>[1]</sup> Studies suggest that the presence of chronic infection, periapical or periodontal, does not influence osseointegration.<sup>[2]</sup> The placement of immediate implants represents an alternative to compromised teeth involved with infectious conditions. Furthermore, evidence arising from the treatment of vertebral osteomyelitis in orthopedic surgery suggests that immediate implants may be a viable option. Subacute bone infection in vertebral osteomyelitis can be successfully managed by meticulous bone debridement and antibiotic therapy combined with titanium mesh cages that provide immediate support and stability

for the weakened vertebrae.<sup>[3,4]</sup> Despite the preceding significant infectious state, these titanium cages were reported to achieve radiographic bone fusion, which is the orthopedic equivalent of osseointegration in implant dentistry. Alveolar ridge resorption after tooth extraction may considerably reduce the residual bone volume and compromise the favorable positioning of implants required for optimal restoration.<sup>[5]</sup> Following the correct clinical indications the immediate placement of the implants into the extraction sockets avoids this undesirable resorption.<sup>[6,7]</sup> Additional benefits, which are also valued by patients, are the avoidance of a second surgical intervention and the reduction in rehabilitation treatment time. Considering that immediate implants can be placed into infected sockets, this paper describes the procedure and evaluates marginal bone loss and intra-osseous stability of immediately placed implants into the infected alveolar socket.

## MATERIALS AND METHODS

A total of 40 implants were immediately placed in the infected socket. Informed consent and pre operative preparation was done in all the patients and a follow up of 6-12 month was recorded. The protocol we followed for immediate placement of dental implants was:

- Tab Clavum (Amoxicillin and clavulonic acid) 625 mg TDS given for 3 days before operation and next 5 days after operation

### Access this article online

#### Quick Response Code:



Website:  
www.ejgd.org

DOI:  
10.4103/2278-9626.106809

- Extraction was done with minimum trauma with the help of drill, endodontic file without any damage to the buccal cortical plates. Removal of the pathology was performed with a small size curette
- Preparation of the socket was done by sequential drilling that was extended up to 3-5 mm beyond the root apex
- After the placement of the implant residual alveolar defect was filled either with Bio-oss (xenograft) or bone harvested from the adjacent site (same site inter-radicular or buccal or lingual cortical plates)
- Platelet rich plasma (PRP) was used in all cases
- Dexamethasone was used in acute cases (doses were 16 mg i.v. stat followed by 8 mg i.v. eight hourly for 2 days)
- Defect was closed with proper suturing of the flap. In some of the cases membrane was used for guided bone regeneration, and in some cases flap was advanced for proper closure.

## RESULTS

The present study was carried out to evaluate the placement of the implants in infected alveolar socket. A total of 40 cases of immediate implantation were performed by the pre-decided treatment protocol. The implants were placed both in the maxilla and mandible. Specially designed clinical

parameters were used for post implantation observations. These parameters included pain, swelling, stability, gingival status, mean probing depth, peri-implant radiolucency and marginal bone loss. The Observations were made post operatively on the 1<sup>st</sup> day, and subsequently on the 1<sup>st</sup>, 3<sup>rd</sup>, 6<sup>th</sup> and 12<sup>th</sup> week. All implants were successfully osseointegrated except four [Figures 1-5].

It was observed that the marginal bone loss was absent on the 1<sup>st</sup> day and 1<sup>st</sup> week in all patients. Bone loss was present in four patients (10%) after 3<sup>rd</sup>, 6<sup>th</sup> and 12<sup>th</sup> week. Although marginal bone loss reduced with time, but this was non-significant [Table 1]. Stability was present in all the patients (100%) at the 1<sup>st</sup> day, 1<sup>st</sup> week and 3<sup>rd</sup> week. After the 6<sup>th</sup> week, mobility was observed in four patients (10%) only. There the difference in stability was non-significant with time [Table 2].

## DISCUSSION

Immediate implant placement of dental implants into fresh extraction sockets was shown to be a predictable and successful procedure when proper protocols were followed. Placement of implants in infected sites were considered a relative contraindication. Literature suggests that periapical pathology may be a cause of implant failure.<sup>[5,8,9]</sup> Thus, many surgeons hesitate in placing the implants

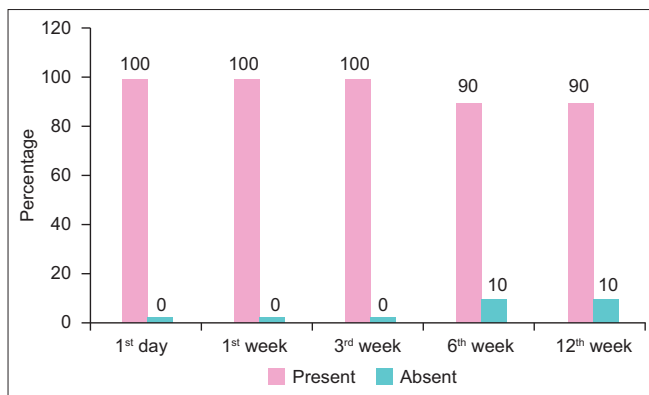


Figure 1: Graphic presentation of implant stability

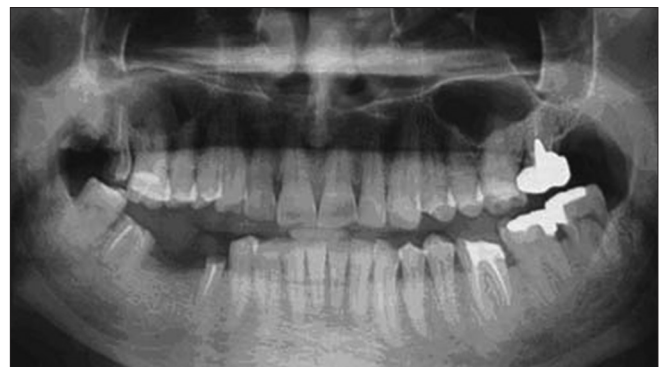

Figure 2: Pre-operative orthopantomogram showing periapical pathology in relation to tooth no. 47

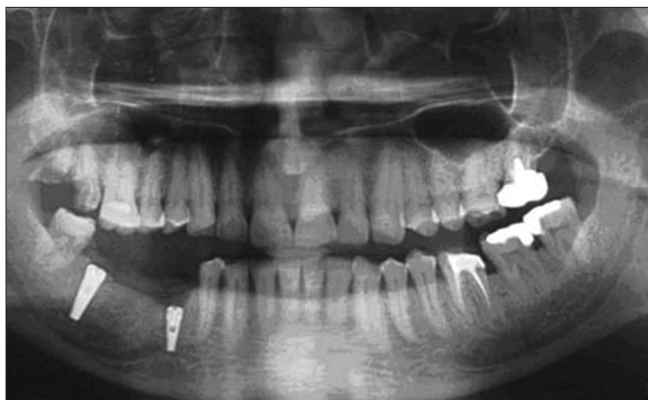

Figure 3: Post-operative orthopantomogram - after 1 week

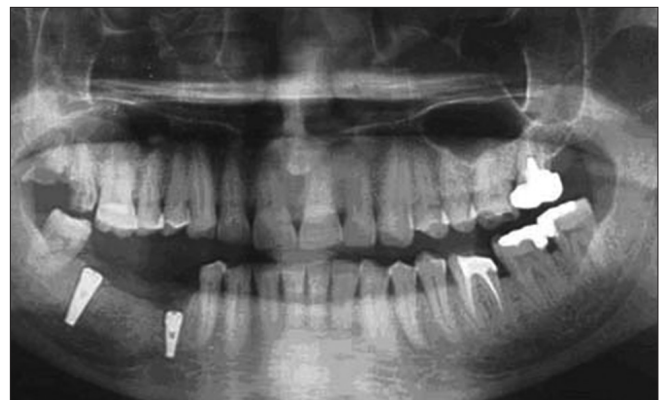

Figure 4: Post-operative orthopantomogram - after 6 weeks

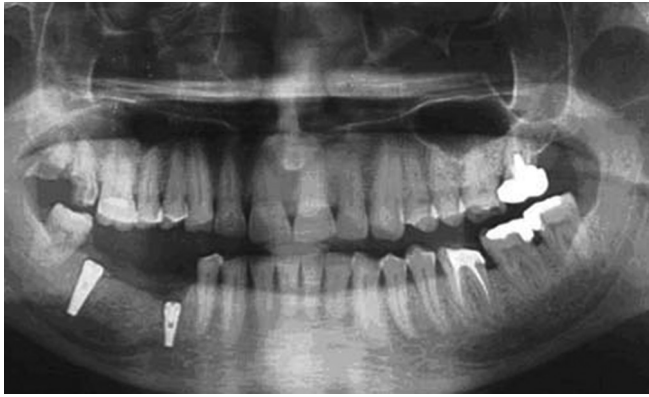

Figure 5: Post-operative orthopantomogram - after 12 weeks

**Table 1: Marginal bone loss**

	1 <sup>st</sup> day		1 <sup>st</sup> week		3 <sup>rd</sup> week		6 <sup>th</sup> week		12 <sup>th</sup> week	
	N	%	N	%	N	%	N	%	N	%
Present	-	-	-	-	04	10.00	04	10.00	04	10.00
Absent	40	100.00	40	100.00	36	90.00	36	90.00	36	90.00
Total	40	100.00	40	100.00	40	100.00	40	100.00	40	100.00

$\chi^2=0.99; P=0.91$  (Not significant)

**Table 2: Implant stability**

	1 <sup>st</sup> day		1 <sup>st</sup> week		3 <sup>rd</sup> week		6 <sup>th</sup> week		12 <sup>th</sup> week	
	N	%	N	%	N	%	N	%	N	%
Present	40	100.00	40	100.00	40	100.00	36	90.00	36	90.00
Absent	-	-	-	-	-	-	04	10.00	04	10.00
Total	40	100.00	40	100.00	40	100.00	40	100.00	40	100.00

$\chi^2=3.13; P=0.54$  (Not significant)

at infected sites, and infection has become a relative contraindication for immediate implantation. With the aim to reduce the process of alveolar bone resorption and treatment time, the immediate placement of endosseous implants into extraction sockets has been propagated by some authors.<sup>[10,11]</sup> However, few clinical data is available on immediate implant placement in chronic periapical infected sites. Clinical reports have suggested that the history of periodontal or endodontic infections is a predictive marker for implant infection and failure.<sup>[12-15]</sup> Thus, some authors<sup>[16,17]</sup> contraindicate the placement of immediate implants in the presence of periodontal or periapical lesions.

On the other hand, Novaes Jr. and Novaes<sup>[18]</sup> stated that the placement of immediate implants in chronically infected sites may not be necessarily contraindicated if appropriate clinical procedures like antibiotic administration, meticulous cleaning, and alveolar debridement are performed before implant surgical procedure. Recently, Lindeboom *et al.*<sup>[19]</sup> carried out a prospective and randomized study of 50 patients aiming to evaluate the clinical success of immediate implants in periapical infected sites. The results showed a success rate of 92% for the immediate implants and 100% for the

delayed implants (placed 3 months post-extraction). The authors concluded that immediate placement of single tooth implants for replacement of teeth with periapical lesions is a predictable treatment and can be indicated.

In this clinical study, we have performed the placement of immediate implant in the infected sites with the designed protocol. Consideration of preoperative antibiotics for the placement of the implant, is a vital tool for the reduction of infection.<sup>[6]</sup> In the cases of acute infection apart from antibiotics we have also added dexamethasone, debridement along with PRP and Bio-oss. In some cases we have also added guided bone regeneration to facilitate the healing in infected socket. This procedure is similar to the treatment of plaque induced peri-implantitis where bone regeneration is expected after removal of plaque with placement of membrane. This study suggests a favorable outcome of immediately placed implants in infected socket, if the proper protocol is followed.

The supervision of an experienced maxillofacial surgeon is utmost important (who can advice regarding the pathology and outcome). Our experience suggests that success is proportional to the adherence with the protocol, but a long-term study with bigger sample size is warranted for authentication of this protocol and procedure.

## CONCLUSION

Immediate implants became a viable option to maintain the periodontal architecture because of their anatomic compatibility with the dental socket and the possibility of eliminating local contamination. Evidence suggests implants can be placed into sites with periapical and periodontal infections. The sites must be thoroughly debrided prior to placement. This study considered the possibility that implants could in fact be inserted into thoroughly debrided, infected extraction sockets under an appropriate antibiotic regime. All implants placed in this study, except four, were successfully osteointegrated. Marginal bone loss was reduced with time but this was non-significant. It can therefore be concluded that when utilizing the protocol outlined, implants can be placed into extraction sockets previously associated with subacute or chronic infections of periodontal and endodontic origin.

## REFERENCES

1. Waasdorp JA, Evian CI, Mandracchia M. Immediate placement of implants into infected sites: A systematic review of the literature. *J Periodontol* 2010;81:801-8.
2. Crespi R, Capparè P, Gherlone E. Fresh-socket implants in periapical infected sites in humans. *J Periodontol* 2010;81:378-83.
3. Hee HT, Majd ME, Holt RT, Pienkowski D. Better treatment of vertebral osteomyelitis using posterior stabilization and titanium mesh cages. *J Spinal Disord Tech* 2002;15:149-156.

4. Liljenqvist U, Lerner T, Bullmann V, Hackenbrg L, Halm H, Winkelmann W. Titanium cages in the surgical treatment of severe vertebral osteomyelitis. *Eur Spine* 2003;12:606-612.
5. Kan JY, Shiotsu G, Rungcharassaeng K, Lozada, JL. Maintaining and attenuating periodontal tissues for aesthetic implant placement. *J Oral Implantol* 2000;26:35-41.
6. Schropp L, Kostopoulos L, Wenzel A. Bone healing following immediate versus delayed placement of titanium implants into extraction sockets: A prospective clinical study. *Int J Oral Maxillofac Implants* 2003;18:189-199.
7. Werbitz MJ, Goldberg PV. The immediate implant: Bone preservation and bone regeneration. *Int J Periodontics Restorative Dent* 1992;12:206-217.
8. Bartee BK. Extraction site reconstruction for alveolar ridge preservation. Part 1: Rationale and materials selection. *J Oral Implantol* 2001;27:187-93.
9. Yang J, Lee HM, Vernino A. Ridge preservation of dentition with severe periodontitis. *Compend Contin Educ Dent* 2000;21:579-83.
10. Lazzara RJ. Immediate implant placement into extraction sites: Surgical and restorative advantages. *Int J Periodontics Restorative Dent* 1989;9:332-43.
11. Ohnell LO, Hirsch JM, Ericsson I, Branemark PI. Single-tooth rehabilitation using osseointegration. A modified surgical and prosthodontic approach. *Quintessence Int* 1988;19:871-6.
12. Ayangco L, Sheridan PJ. Development and treatment of retrograde peri-implantitis involving a site with a history of failed endodontic and apicoectomy procedures: A series of reports. *Int J Oral Maxillofac Implants* 2001;16:412-7.
13. Oh TJ, Yoon J, Wang HL. Management of the implant periapical lesion: A case report. *Implant Dent* 2003;12:41-6.
14. Karoussis IK, Salvi GE, Heitz-Mayfield LJ, Brägger U, Hämmerle CH, Lang NP. Long-term implant prognosis in patients with and without a history of chronic periodontitis: A 10-year prospective cohort study of the ITI Dental Implant System. *Clin Oral Implants Res* 2003;14:329-39.
15. Polizzi G, Grunder U, Goené R, Hatano N, Henry P, Jackson WJ, *et al.* Immediate and delayed implant placement into extraction sockets: A 5-year report. *Clin Implant Dent Relat Res* 2000;2:93-9.
16. Becker W, Becker BE. Guided tissue regeneration for implants placed into extraction sockets and for implant dehiscences: Surgical techniques and case report. *Int J Periodontics Restorative Dent* 1990;10:376-91.
17. Barzilay I. Immediate implants: Their current status. *Int J Prosthodont* 1993;6:169-75.
18. Novaes AB Jr, Vidigal GM Jr, Novaes AB, Grisi MF, Polloni S, Rosa A. Immediate implants placed into infected sites: A histomorphometric study in dogs. *Int J Oral Maxillofac Implants* 1998;13:422-7.
19. Lindeboom JA, Tjiook Y, Kroon FH. Immediate placement of implants in periapical infected sites: A prospective randomized study in 50 patients. *Oral Surg Oral Med Oral Pathol Oral Radiol Endod* 2006;101:705-10.

**How to cite this article:** Pal US, Singh N, Singh RK, Mohammad S, Malkunje LR, Loan PA. Evaluation of stability of immediately placed implants in infected sockets. *Eur J Gen Dent* 2013;2:46-9.

**Source of Support:** Nil, **Conflict of Interest:** None declared.

### “Quick Response Code” link for full text articles

The journal issue has a unique new feature for reaching to the journal’s website without typing a single letter. Each article on its first page has a “Quick Response Code”. Using any mobile or other hand-held device with camera and GPRS/other internet source, one can reach to the full text of that particular article on the journal’s website. Start a QR-code reading software (see list of free applications from <http://tinyurl.com/yzlh2tc>) and point the camera to the QR-code printed in the journal. It will automatically take you to the HTML full text of that article. One can also use a desktop or laptop with web camera for similar functionality. See <http://tinyurl.com/2bw7fn3> or <http://tinyurl.com/3ysr3me> for the free applications.