

# Biological restorations: Option of reincarnation for severely mutilated teeth

Kulvinder Kaur Wadhvani, Mukesh Hasija, Babita Meena<sup>1</sup>, Deepti Wadhwa<sup>2</sup>, Rakesh Yadav

Department of Conservative Dentistry and Endodontics, King George's Medical University, Chowk, Lucknow, Uttar Pradesh, <sup>1</sup>Conservative Dentistry and Endodontics, Jamia Milia Islamia, New Delhi, <sup>2</sup>Periodontics, Dr. Z. A. Dental College, AMU, Aligarh, Uttar Pradesh, India

Address for correspondence:

Dr. Mukesh Hasija,  
Department of Conservative Dentistry  
and Endodontics, King George's  
Medical University, Chowk, Lucknow,  
Uttar Pradesh, India.  
E-mail: mukesh8shasija@gmail.com

## ABSTRACT

**Objective:** Esthetic and functional rehabilitation of severely mutilated fractured central incisors teeth using homogenous biological fragment bonding. **Materials and Methods:** Freshly extracted maxillary central incisors were treated endodontically and post spaces were prepared. Intra-radicular biological post core were fabricated from the sectioned roots of extracted canines. Cementation of biological post core in prepared space was done after clinical and radiological confirmation. Subsequent esthetic rehabilitation was done using adaptation of biological crown which was prepared from morphologically similar extracted maxillary central incisor. **Results:** The association between biological crowns and post core offers excellent esthetic, functional, and psychosocial results, which justifies the use of this technique to achieve the morphofunctional recovery of extensively damaged teeth. **Conclusion:** The biological restorations are an alternative technique for reconstruction of extensively damaged teeth that provides highly functional and esthetic outcomes.

## Key words

Biological post, central incisors, esthetic

## INTRODUCTION

Dentistry has undergone a significant evolution since its beginnings. Many technological advances have taken place since the first extracting theories. Today, the tendency is to keep any tooth, even if only a small piece remains. Owing to difficulty in obtaining good retention, there were few attempts to reattach fractured fragments of the teeth. Chosack and Eildeman<sup>[1]</sup> published the first case report on reattachment of a fractured incisor fragment in 1964 in which complicated tooth fracture was managed by endodontic treatment, followed by a cast post and core.

Anterior tooth fracture, as a result of traumatic injuries, occurs frequently with high prevalence of 8.1 in 1000.<sup>[2]</sup> Anterior tooth trauma often results in functional, esthetics, psychological problems and reducing patient's

quality of life. In the past, fractured teeth were restored using acrylic resin or complex ceramic restorations associated with metals. These restorations did not promote adequate long-term esthetics, and also required a significant tooth reduction during preparation.

A satisfactory restoration can be achieved using several techniques, and esthetic materials such as resin and porcelain. Although great scientific and technological advances regarding the restorative and adhesive material in recent time had made the restoration of mutilated teeth a great success,<sup>[3]</sup> but to date there is no material that has been proved to be as effective as natural structure considering mechanical and biological properties.<sup>[2-4]</sup> Recently, with the advancement in the materials and bonding techniques, this new method of retaining fractured natural tooth segment is gaining popularity.<sup>[5,6]</sup>

Biological post core, crown, and veneers restoration can be comparative and is a cheaper solution in restoring anterior teeth to achieve best esthetic restoration. Biological restorations made from natural extracted teeth appears to be very promising with regard to esthetics<sup>[7]</sup> and low cost. However, biomechanical properties of these biological restorations are yet to be determined for the long term clinical use. Biological restoration are perfect in term of esthetic, bonding to tooth structure with the

### Access this article online

#### Quick Response Code:



Website:  
www.ejgd.org

DOI:  
10.4103/2278-9626.106820

use of resin cements, having modulus of elasticity<sup>[8]</sup> same as that of tooth to be restored.

To achieve successful functional rehabilitation of severely mutilated teeth with conventional post core, retention, and stability are prime factors. This can be achieved using biological post and core made from natural, extracted teeth radicular dentin. As these biological post cores are composed of dentinal structure taken from freshly extracted teeth thus have similar anisotropic structure as that of tooth to be restored. Presence of similar structure might enable them to absorb and dissipate stress.<sup>[9]</sup>

Biological restorative system has advantage of shorter treatment time without involvement of laboratory procedures, low-treatment cost, preservation of healthy tooth structure, less chances of galvanic corrosion, good adherence to canal surface, and best esthetics.<sup>[10]</sup>

The present *in vitro* report describe the effort aimed at esthetic and functional rehabilitation of severely mutilated central incisors teeth using homogenous biological fragment obtained from extracted natural teeth.

## MATERIALS AND METHODS

Freshly extracted maxillary central incisor with no associated fractures or cracks was selected as experimental samples. Sample was placed in 3% aqueous buffers solution of formaldehydes. Thereafter, sample were cleaned and stored in distilled water.<sup>[11]</sup> Sample was then mounted on resin blocks [Figure 1]. Coronal portions of sample teeth were cut-off using ceramic disk at level of proximal cemento-enamel junction (CEJ). A chamfer, finishing line, 1-mm in depth and width was prepared at CEJ level around the entire circumference of tooth.

### Endodontic preparation and post space preparation

Access opening of selected sample was done under water air spray, using airoter handpiece. Root canal preparation included instrumentation of the working length with intermittent irrigation with sodium hypochlorite and normal saline and enlargement up to F3 protaper. Obturation of canals was performed with F3 protaper gutta percha cones and AH-26 root canal sealer. The post space was prepared with a Gate Glidden drills no. 3 to depth of 14 mm from chamfer line, leaving 4 to 6 mm gutta percha in apical third [Figure 2].

### Fabrication of biological post core

Freshly extracted human canines, without fractures or cracks, were selected to construct the biological posts core. Using diamond disk, the crown portion were separated from root portion followed by removal of apical third portion of root. Thereafter, roots were sectioned mesiodistally [Figure 3] along the long axis of the tooth.

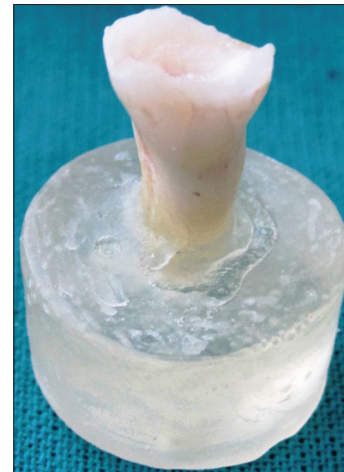

Figure 1: Fractured extracted central incisor

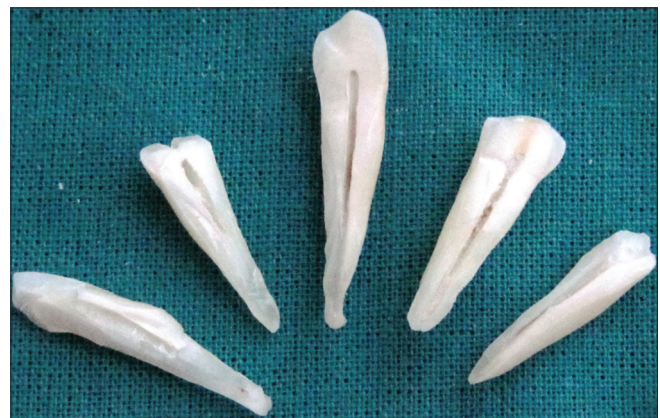

Figure 2: Mesio-distal sections of extracted teeth for biological post and core preparation



Figure 3: Endodontic preparation and post space preparation

Using diamond abrasive points, each part of the root was cut in such a way to form biological post core. Prepared dentine post core was checked time to time to get a snug fit of prepared post space while making same oriented shape, thickness, and length of dentine post. The coronal

portions were prepared to a height of 3 mm (coronal to proximal CEJ) and width of 3 mm. All measurements were made using a caliper gauges.

### Adaptation and cementation of biological posts and core to root canal

After confirming the satisfactory adaptation of posts to the prepared canal through clinical and radiographic analysis [Figure 4], the cementation was done.<sup>[12]</sup> The post and the canal wall were conditioned with 37% phosphoric acid for 15 s, adhesive was applied, and polymerized. The dual cure resin cement was applied to inner portion of canal space with lentulo-spiral, and on the surface of the biological post part, which were then inserted into the prepared canal space under constant pressure until the cement polymerize completely.<sup>[13]</sup>

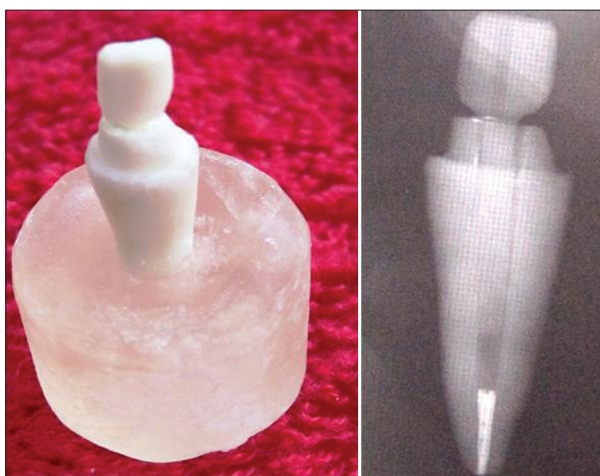


Figure 4: Cemented biological post core

To standardize the size and length of the posts, the recommendations from the literature were followed. The post length used was three-quarter of the root length of each specimen and the post size used was smaller or as close possible to one-third of the root diameter.

### Fabrication of crown portion

The crown preparation was done with a chamfered cervical finish line on sample teeth restored with biological post core. The teeth that were preselected to make biological crown were autoclaved at 121°C for 15 min. The coronal portions of sterilized teeth were cut off, using ceramic disk at level of proximal CEJ. Biological crown portions were prepared by hollowing both internally as well as on the cervical portion of extracted sterilized crown; leaving approximately 1 mm dentine with the enamel, using various round and chamfered diamond points under intense cooling [Figure 5].

### Cementation of biological crown

The shaped biological crown was then tried for fit on the prepared sample teeth restored with biological post core and readjusted for a snug fit. The coronal portion of fitted biological core and inner portion of prepared biological crown were conditioned with 37% phosphoric acid for 15 s and washed thoroughly. Both, biological core and crown were dried and adhesive system was applied. The crowns were filled with the self-curing resin cement, positioned, and maintained under digital pressure until polymerization was completed [Figure 5].<sup>[14]</sup> Excess extruded cement was removed. Finishing and polishing was done to give a final esthetic result. Adaptation of crown and post was finally checked clinically and radiographically.

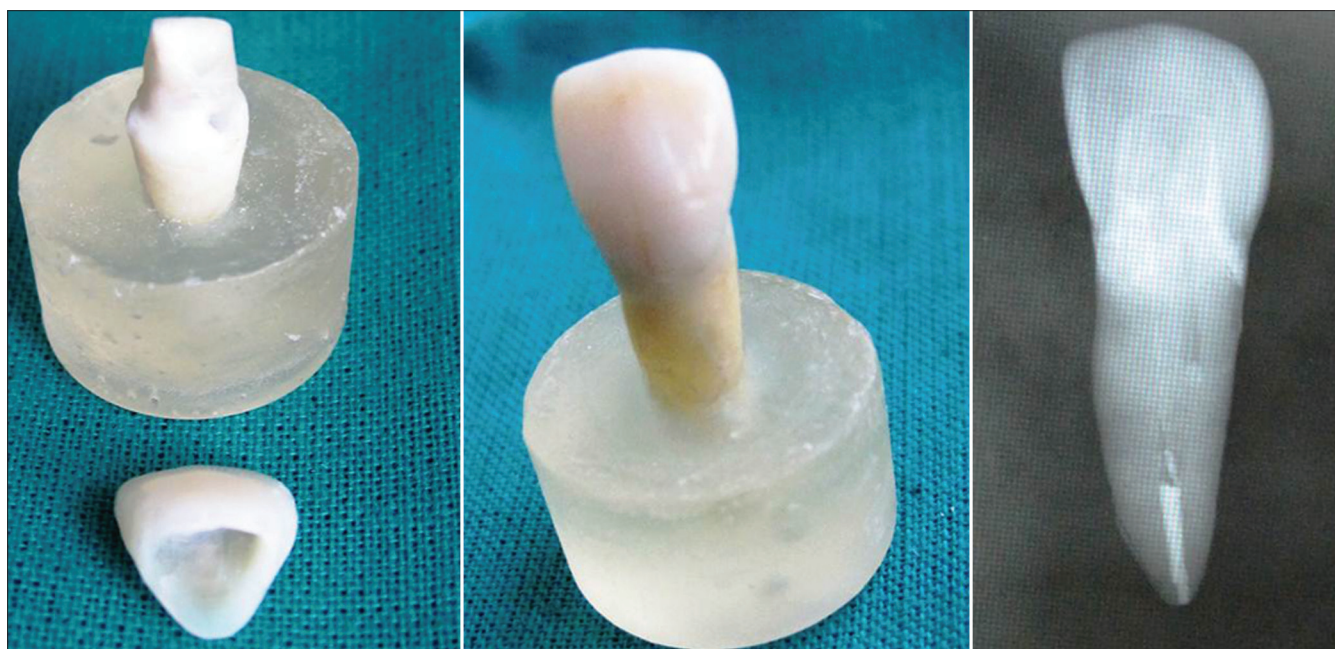


Figure 5: Biological crown adjusted and cemented

## RESULTS

*In vivo* clinical performance of biological post and crown restorations was comparable with respect to shade match, marginal discoloration, marginal integrity, surface finish and retention. The cost effectiveness of biological restorations was certainly a positive attribute. The association between biological crowns and post core offers excellent esthetic, functional, and psychosocial results, which justifies the use of this technique to achieve the morphofunctional recovery of extensively damaged teeth.

## DISCUSSION

Fragment reattachment using natural teeth is a technique known as “biological restoration”. A biological restoration meets the esthetic and structural standards of natural teeth. Biological restoration using natural post core, which fit snugly into prepared post space with core can provide natural esthetic treatment option.<sup>[15]</sup>

There are two methods for restoring the tooth with biological restoration. First, is autogenous biological restoration<sup>[5,6]</sup> when fractured fragment is available and is in satisfactory condition. The other one is using donated extracted teeth.<sup>[16]</sup> The combination of dental fragment, adhesive, restorative material provide a good functional and esthetic results, thus gives an excellent alternative treatment in restoring severely mutilated teeth.

Restoration of severely mutilated anterior teeth is a challenging job and over the years many clinicians have tried various procedures to restore them. In cases of severe loss of tooth structure, intra-canal posts become mandatory. Recent developments in restorative materials, placement techniques, and adhesive protocols facilitate these restorations. However, these procedures turn out to be expensive and technique sensitive, and also require expertise of operator. Therefore, a biological restoration seems to be a successful cost-effective alternative approach for treating such cases.

The selected samples can be procured from the Tooth Tissue Bank,<sup>[7]</sup> where teeth were stored and sterilized after thorough scaling and removal of soft tissue, periodontal remnants, and pulpal issue from the root-canals. Teeth were kept at 4°C in Hank’s balanced salt solution with donor identification and various tooth parameters like dimensions, color, shape, and age.

The method of using biological crown and post core restoration for mutilated teeth had shown promising results. Furthermore, it proved to be a cost-effective alternative, making it possible to recycle precious biological tissue which has been discarded as bio-waste. However, the patient acceptance of a biological restoration is an important issue and donor selection

from siblings could be a more acceptable alternative. Literature suggested that research into new materials should focus on those systems with an elastic modulus close to dentin and strength equal to or higher than dentin. The biological post core and crown made of dentinal structure is most suitable.<sup>[9]</sup>

The intra-radicular retention can be obtained using posts made from several materials; such as glass fiber, carbon fiber, metal, and ceramic.<sup>[7,17]</sup> However, no commercially available pre-manufactured post meets all ideal biological and mechanical properties. The use of biological post made from natural-extracted teeth represents a feasible option for strengthening of root canal, and presents potential advantages. Biological restoration seems not to promote dentine stress; preserve the internal dentine wall of root canal; biocompatibility and adapts to conduct configuration; favoring greater tooth strength and retention as compared to pre-manufacturing posts. It presents resilience comparable to original tooth, and offers an excellent adhesion to tooth structure and composite resin at low cost.

The use of natural exacted teeth for restoration does presents limitations like patient acceptance, difficulty in retrieval, availability of teeth with similar structure with similar tooth color. Furthermore, adaptation of the post to the root canal may be less accurate.<sup>[18,19]</sup> Fabrication of dentinal post may require a technically sound system to get an exact fit post, crack free dentinal structure, shade guide system for color matching, and tooth bank for availability. Furthermore, longevity of root post core crown system used to restore an endodontically treated tooth is affected by many factors like design, length, diameter of root, ferrule effect cementation, and quality and quantity of remaining tooth structure.

Hence, future research should focus on how the length, size, and design of the biological post, the cementing technique, and the post insertion parameters influence the biomechanics of restored teeth. The crossed influence between these parameters should be studied and analyzed to ensure a more robust restoration.

## CONCLUSION

Within the limitations, it seems that biological post core and crown offer excellent esthetic, functional advantages to achieve the morphofunctional restoration of extensively damaged teeth.

## REFERENCES

1. Chosack A, Eildeman E. Rehabilitation of fractured incisor using the patient’s natural crown. Case report. *J Dent Child* 1964;31:19-21.
2. Andreasen JO, Ravn JJ. Epidemiology of traumatic dental injuries to primary and permanent teeth in a Danish population sample. *Int J Oral Surg* 1972;1:235-9.

3. Galindo VA, Nogueira JS, Yamasaki E, Kós Miranda D. Biological posts and natural crowns bonding – Alternatives for anterior primary teeth restoration. *J bras odontoped odontol bebe* 2000;16:513-20.
4. Kaizer OB, Bonfante G, Pereira Filho LD. Utilization of biological posts to reconstruct weakened roots. *RGO-Rev Gaúcha Odontol* 2008; 56:7-13.
5. Yilmaz Y, Zehir C, Eyuboglu O, Belduz N. Evaluation of success in the reattachment of coronal fractures. *Dent Traumatol* 2008;24:151-8.
6. Demarco FF, de Moura FR, Tarquinio SB, Lima FG. Reattachment using a fragment from an extracted tooth to treat complicated coronal fracture. *Dent Traumatol* 2008;24:257-61.
7. Imparato JC, Bonecker MJ, Duarte DA, Guedes Pinto AC. Restorations in anterior primary teeth: An alternative technique through gluing of natural crowns. *J bras odontoped odontol bebe* 1998;1:63-72.
8. Asmussen E, Peutzfeldt A, Heitmann T. Stiffness, elastic limit, and strength of newer types of endodontic posts. *J Dent* 1999;27:275-8.
9. Andreasen FM, Norén JG, Andreasen JO, Engelhardtson S, Lindh-Strömberg U. Long-term survival of fragment bonding in the treatment of fractured crowns: A multicenter clinical study. *Quintessence Int* 1995;26:669-81.
10. Grewal N, Reeshu S. Biological restorations: An alternative esthetic treatment for restoration of severely mutilated primary anterior teeth. *Int J Clin Pediatr Dent* 2008;1:42-7.
11. Habelitz S, Marshall GW Jr, Balooch M, Marshall SJ. Nanoindentation and storage of teeth. *J Biomech* 2002;35:995-8.
12. Alvares I, Sensi LG, Araujo EM Jr, Araujo E. Silicone index: An alternative approach for tooth fragment reattachment. *J Esthet Restor Dent* 2007;19:240-5.
13. Hall DA. Restoration of a shattered tooth. *J Am Dent Assoc* 1998;129:105-6.
14. Perdigão J, Lopes M. Dentin bonding–state of the art 1999. *Compend Contin Educ Dent* 1999;20:1151-62.
15. Corrêa-Faria P, Alcântara CE, Caldas-Diniz MV, Botelho AM, Tavano KT. "Biological restoration": Root canal and coronal reconstruction. *J Esthet Restor Dent* 2010;22:168-77.
16. Busato AL, Antunes M. Heterogeneous bonding in anterior fractured teeth. *RGO-Rev Gaúcha Odontol* 1984;32:137-40.
17. Candido MS, Pozzobon RT, Porto Neto ST. Esthetic resolution through heterogeneous bonding root-coronal, laminate and recontourn. *J Bras Odontol Clin* 1999;15:29-33.
18. Reis A, Loguercio AD, Kraul A, Matson E. Reattachment of fractured teeth: A review of literature regarding techniques and materials. *Oper Dent* 2004;29:226-33.
19. Baratieri LN, Ritter AV, Monteiro Júnior S, de Mello Filho JC. Tooth fragment reattachment: An alternative for restoration of fractured anterior teeth. *Pract Periodontics Aesthet Dent* 1998;10:115-25.

**How to cite this article:** Wadhvani KK, Hasija M, Meena B, Wadhwa D, Yadav R. Biological restorations: Option of reincarnation for severely mutilated teeth. *Eur J Gen Dent* 2013;2:62-6.

**Source of Support:** Nil, **Conflict of Interest:** None declared.