

## Oral psoriasis: A diagnostic dilemma

Saif Khan, Sufian Zaheer<sup>1</sup>, N. D. Gupta

Departments of Periodontology and <sup>1</sup>Pathology, Dr. Z. A. Dental College and Hospital, Faculty of Medicine, Aligarh Muslim University, Aligarh, Uttar Pradesh, India

Address for correspondence:

Dr. Saif Khan,  
Department of Periodontology,  
Dr. Z. A. Dental College and Hospital,  
Aligarh Muslim University,  
Aligarh, Uttar Pradesh, India.  
E-mail: saifgood@gmail.com

### ABSTRACT

Psoriasis is a chronic, genetically linked, scaly, and inflammatory disease of the skin. Oral manifestations of psoriasis are rare and are often difficult to diagnose. A 35-year-old female presented with gum bleeding, chronic irritation, intolerance to salt and spicy food, and frequent occurrence of painful mouth ulcers with a fissured tongue. Examination of the oral cavity showed desquamations on the buccal mucosa with pedunculated and exophytic growths and also slight gingival enlargements in the anterior segment. The exophytic growths along with gingival enlargement were excised and sent for histopathological examination, which revealed them to be psoriasis. Oral psoriasis is a rare entity and might be confused with other oral mucous membrane dermatoses; hence, it should be considered under differential diagnosis of oral mucous membrane disorders and confirmed histopathologically.

### Key words

Geographic tongue, oral dermatoses, oral psoriasis, scrotal tongue

### INTRODUCTION

Psoriasis is a chronic, genetic, scaly, and inflammatory disorder of the skin manifesting with remissions and exacerbations.<sup>[1]</sup> The term psoriasis is derived from the Greek word '*psora*' meaning itch. Willan first described this disease accurately.<sup>[2]</sup> It is usually seen in the second and third decades of life. The disease does not have any sexual or social predilection.<sup>[3]</sup> The most common type is psoriasis vulgaris, in which well-delineated pappulosquamous plaques are observed. The plaques are red or salmon pink in color and covered by white or gray scales. These lesions are generally distributed symmetrically, involving most commonly the extensor aspects of elbows and knees, scalp, lumbosacral region, and umbilicus. The lesions are characterized by the Koebner phenomenon in which new lesions develop at the site of trauma or pressure.<sup>[4]</sup> Although psoriasis is a common chronic skin disorder, oral lesions are rare.<sup>[5]</sup> Here we report a known case of psoriasis presenting with oral symptoms.

### CASE REPORT

A 35-year-old female patient reported with complaints of gum bleeding, chronic irritation, intolerance to salt and spicy food, and frequent occurrence of painful mouth ulcers. She complained of dry and crusted lips, which healed with the formation of silvery crusting. The patient also complained of chronic irritation and itching all over her body for the last 3-4 years and dry and rough skin along with silvery scales, which bled on rubbing. The patient was undergoing treatment for her skin lesions by a dermatologist and was referred to us for her oral complaints.

On examination, dry and rough pappulosquamous scales were seen all over her face. The lips were dry and crusted and there was evident angular cheilitis present on both the sides [Figure 1].

Intra-orally, pedunculated and exophytic growths were present: One in the right lower labial mucosa and the other on the right buccal mucosa just posterior to the right commissure. The buccal mucosa showed desquamations and blanching; the linea alba on both the sides was very much pronounced, showing signs of keratosis along with slight gingival enlargements seen both in the lower and upper anterior quadrants [Figure 2]. The tongue was extensively involved with longitudinal and transverse fissures, similar to a fissured or scrotal tongue [Figure 3]. Apart from the oral and facial regions, dry silvery scale was also found on her shins, which was bilaterally symmetrically distributed [Figure 4].

#### Access this article online

##### Quick Response Code:

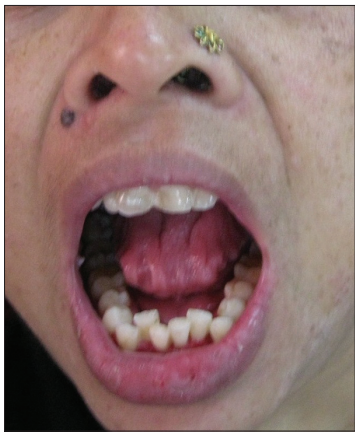


Website:  
www.ejgd.org

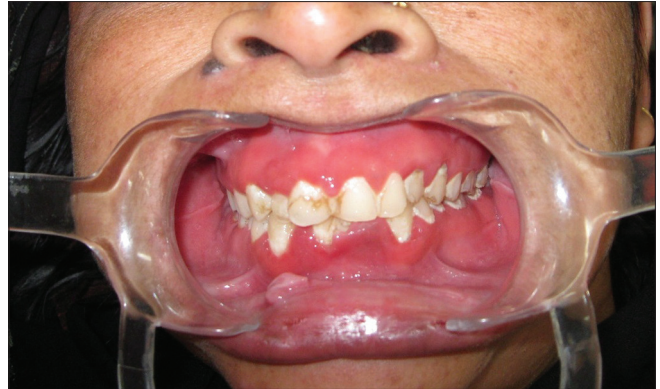DOI:  
10.4103/2278-9626.106822

Excisional biopsy of gingival enlargement was carried out from the lower anterior segment along with exophytic pedunculated growth that was present in the right lower labial mucosa and it was sent for histopathological

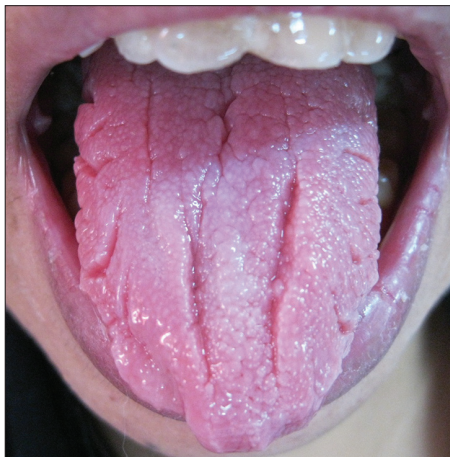examination. Histopathological report of both the lesions revealed parakeratosis, along with flattened small aggregates of neutrophils in the stratum corneum with spongiform pustule, consisting of intraepidermal collection of neutrophils situated in stratum malpighii. There was paucity of granular cell layer [Figures 5 and 6].



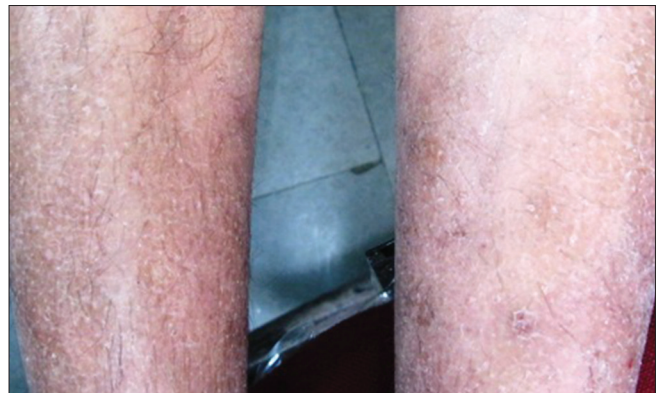**Figure 1:** Pappulosquamous scales present all over the face and also dry crusted lips with bilateral angular cheilitis



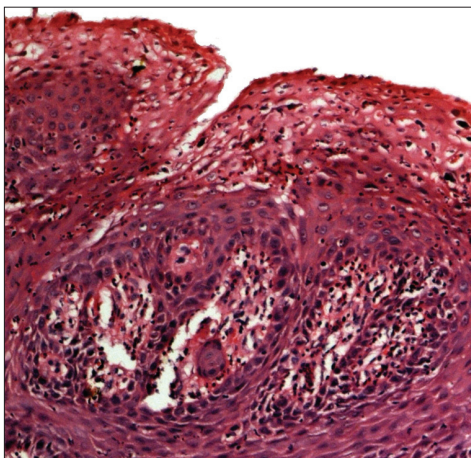
**Figure 2:** Pedunculated exophytic growth present on the right lower labial mucosa and generalized desquamations and blanching bilaterally on the buccal mucosa. Also note slight gingival enlargements in the upper and lower anterior quadrants



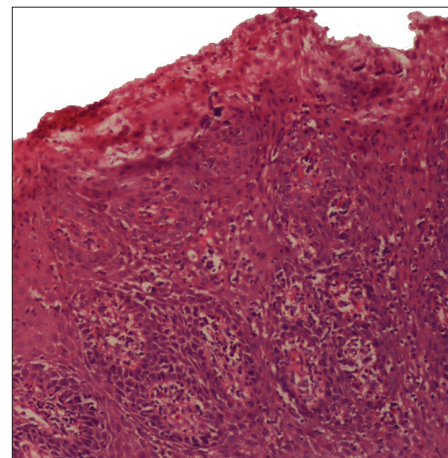
**Figure 3:** Fissured tongue in the patient with longitudinal and horizontal fissures



**Figure 4:** Dry silvery scales bilaterally on both shins, suggestive of psoriasis



**Figure 5:** The microphotograph shows characteristic parakeratosis, along with flattened, small aggregates and individually lying neutrophils in the stratum corneum (H and E, ×40)



**Figure 6:** Spongiform pustule, consisting of intraepidermal collection of neutrophils situated in stratum malpighii, along with parakeratosis. There is paucity of granular cell layer (H and E, ×40)

## DISCUSSION

The occurrence of oral mucosal changes in patients with psoriasis is a debatable issue; some authors are in accordance with the concept of oral lesions as a manifestation of psoriasis based on histopathological findings and others believe that oral lesions need to follow the same clinical course so as to accept them as the same entity.<sup>[6]</sup> Oral manifestation of psoriasis is rare despite psoriasis being a common skin disease. There are less than 100 published reports of oral psoriasis in the literature.<sup>[5]</sup> The first oral manifestation of psoriasis was documented by Oppenheim and Thimm<sup>[7]</sup> in 1903. Usher,<sup>[8]</sup> in 1933, found oral lesions only in two of his 100 cases of psoriasis he examined. The first case had a scrotal tongue. The second case had an extensive involvement of the buccal mucosa from commissure of the lip anteriorly to the anterior faucial pillar posteriorly by a coarse, interlacing network of grayish-white striae interspersed with unaffected mucous membrane; histologically, however, neither of the two cases presented typical features of psoriasis.<sup>[8]</sup> It was observed by DeGregori *et al.*<sup>[9]</sup> that until 1971 only 15 cases of oral psoriasis had been documented, of which three had gingival involvement.<sup>[10]</sup> The first prospective study was carried out by Hietanen *et al.*<sup>[11]</sup> in 1984. The study examined 200 patients of cutaneous psoriasis, of which 20 patients had oral involvement; they were further biopsied but typical psoriatic lesions were found only in four cases. The existence of specific lesions in oral psoriasis has been both asserted and questioned in various studies,<sup>[12-14]</sup> thus making it difficult for an oral physician to diagnose a case of oral psoriasis.

### Oral manifestations in Psoriasis

Oral psoriasis has been seen to manifest in broadly four types of lesions: (1) well-defined yellowish-white lesions, round to oval in shape, which are independent of cutaneous psoriasis; (2) white, lacy, circinate, elevated lesions on the mucosa and tongue that are congruent with skin lesions; (3) erythema or redness of the entire oral mucosa associated with acute exacerbation of psoriasis; (4) geographic tongue, seen more frequently in patients with cutaneous psoriasis than in controls.<sup>[5]</sup>

It has been seen that oral psoriasis usually develops in patients presenting acute cutaneous psoriatic lesions rather than in their chronic counterparts.<sup>[5,15]</sup> Gingival involvement in psoriasis has been observed by various authors.<sup>[10,16]</sup> In addition, involvement of both upper and lower lips, hard and soft palate, buccal mucosa, floor of the mouth, and edentulous maxillary ridge have been observed.<sup>[17-20]</sup>

Oral psoriasis can involve any part of the oral mucosa and clinical features are somewhat understated.

### Lips

Psoriasis of the vermilion of the lips is rare and is usually associated with more typical plaque psoriasis elsewhere.<sup>[21]</sup> It presents as scaly areas that may extend across the vermilion border.<sup>[22]</sup> Keratotic lesions have also been described.<sup>[23]</sup> Involvement of the vermilion border can also occur without the involvement of oral cavity.<sup>[22,24]</sup> In addition, occurrence of angular cheilitis has been shown to occur in psoriatic patients;<sup>[25]</sup> however, a larger study refutes this claim.<sup>[13]</sup> Sometimes psoriasis of the vermilion border of the lip occurs due to the Koebner phenomenon of the protruded upper teeth.<sup>[26]</sup> In the present case too, there was bilateral angular cheilitis along with dry crusted lips, which proves it to be a psoriatic lesion [Figure 1].

### Tongue

Tongue changes in psoriasis can manifest in two major types. The first type incorporates mucosal abnormalities with histopathology similar to psoriasis; these mucosal lesions follow a similar clinical course as that of cutaneous psoriasis. These oral lesions are usually asymptomatic and hence usually go unnoticed. The second type is very common and comprises a range of non-specific lesions such as geographic tongue (GT) and fissured tongue (FT).<sup>[14]</sup> The prevalence of GT and FT is higher in patients with psoriasis compared with controls.<sup>[6,15,25]</sup>

GT is found on the dorsum surface of the tongue with characteristic centrifugally spreading loss of filiform papilla, leading to the formation of erythematous zones or patches. The advancing margin is slightly raised, serpentine in shape, and whitish yellow in color. It occurs in 1-5% of the general population,<sup>[27]</sup> with a slight female predilection.<sup>[28]</sup> FT is characterized by an anteroposteriorly oriented fissure with branching fissures and is believed to be an inherited trait.<sup>[29]</sup> It occurs in 2-5% of the general population and the incidence increases with age.<sup>[27,30]</sup> There is a frequent occurrence of GT with FT and nearly 50% of patients with GT also have FT; moreover, there is a transformation from GT to FT.<sup>[28,29]</sup> In a recent study, it has been observed that ectopic GT is seen in 5.4% of patients with psoriasis compared to 1% of control patients; GT was seen in 10.3% of patients with psoriasis and 2.5% of control patients.<sup>[12]</sup> Hernandez-Perez F *et al.*<sup>[6]</sup> found that FT and GT are more prevalent in patients having psoriasis than that of control subjects.<sup>[6]</sup> Daneshpazhooh *et al.*<sup>[14]</sup> showed that FT and GT are seen in 33% and 14% of patients, respectively, with cutaneous psoriasis.<sup>[14]</sup> Similarly, these findings were similar to those of Hietanen *et al.*<sup>[9]</sup> and Pogrel *et al.*<sup>[15]</sup> These findings were explained by Ulmansky *et al.*,<sup>[31]</sup> who proposed that GT is a transitory manifestation of psoriasis, whereas FT is a late and permanent expression. In our case also, FT comprising longitudinal and transverse fissures can be seen, which add to the lesion of being a manifestation of psoriasis [Figure 3].

### Buccal mucosa

Lesions of buccal mucosa present as annular, serpiginous overgrowths or as polycyclic papules and plaques, which are more commonly observed during the acute stage of the disease.<sup>[32]</sup> Whitish and erythematous patches have been observed on buccal mucosa in 3.5% of 547 patients observed by Kaur *et al.*<sup>[12]</sup> It is similar to GT but occurs on the buccal mucosa and the reported frequency ranges from 0% to 19% of psoriasis patients.<sup>[15]</sup> The exophytic and annular lesion on the right labial mucosa can also be appreciated in the present case [Figure 2].

### Palate

Oral psoriasis manifests as both white and red lesions in the form of serpiginous and concentric arcs on the palate.<sup>[33]</sup> The white palatal lesions are generally semitransparent plaque rather than silvery white scales seen typically in psoriasis, whereas red lesions present like erythematous patches with or without ulceration, similar to ectopic GT.<sup>[34]</sup>

### Gingiva

Involvement of gingiva is very rare. It manifests as erythema of the gingival margin with white reticular plaques extending from the erythema. In addition, periodontitis with sharply defined erythematous gingival plaques have been observed in oral psoriasis.<sup>[31,35]</sup>

### Temporomandibular joint

Temporomandibular joint (TMJ) arthritis is sometimes seen in psoriatic patients<sup>[36]</sup> and it improves as the psoriatic lesion heals.<sup>[37]</sup> The diagnosis of psoriatic arthritis is made by the absence of rheumatoid factor because the radiographic finding of rheumatoid arthritis is not very specific.<sup>[38]</sup>

### Histopathological features

Psoriasis has three basic histological features: Epithelial hyperplasia; dilated or increased blood vessels in the dermis; and an increase in inflammatory infiltrate comprising mainly leukocytes, which are present in the dermis compared with normal tissue. Epithelial changes include loss or paucity of the granular cell layer, parakeratosis, elongation of rete pegs, and the presence of micro pustules of kogoj and micro abscess of munro.<sup>[4]</sup> However, in oral psoriasis, the epithelium is parakeratotic and the rete ridges are long and show clubbing or thickening in the lower portion. Connective tissue papillae are elongated and in many areas the epithelium over the papillae is very thin and dilated or engorged capillaries are often seen at the tips of the connective tissue papillae. The uppermost epithelial layers are also infiltrated with polymorph nuclear neutrophils. No clear-cut monomicro-abscesses are usually encountered although in some areas dense accumulations of polymorph nuclear neutrophils are seen. Few mitotic figures are observed in the basal epithelium. The inflammatory cell infiltrate in

the lamina propria is mainly composed of mononuclear cells where the degree of inflammation usually varied from mild to moderate.<sup>[9]</sup> Epithelial turnover rate is increased to 4 days for the skin and 5-8 days for normal oral mucosa compared with 28 days for normal skin and mucosa.<sup>[39]</sup> Immunohistochemical studies have shown that markers of keratinocyte differentiation are changed in the psoriatic epithelium, with an increase in the expression of keratins K6, K16, and K17, and a decrease in K1/K10. In addition, proteins such as involucrin, filaggrin, and transglutaminase involved in the formation of the cell envelope during cornification are prematurely expressed. Although psoriatic lesions are not premalignant, dystrophic changes may occur after treatment with arsenicals or radiation.<sup>[2]</sup>

### Differential diagnosis

The basic criteria in the diagnosis of oral psoriasis comprise simultaneous occurrence of skin and oral mucosal lesions that are confirmed histopathologically, positive family history of cutaneous psoriasis and also positive Human Leukocyte Antigen (HLA) typing antigen such as B13, B17, B37, Cw04, and Cw06.<sup>[40]</sup> The differential diagnosis of oral psoriasis includes lichen planus, candidiasis, leukoplakia, pemphigoid, pemphigus, eczema, lupus erythematosus, neurodermatitis, syphilis, idiopathic gingivostomatitis, Reiter's syndrome, stomatitis medicamentosa, palatal hyperplasia, and squamous cell carcinoma.<sup>[2]</sup> In patients where cutaneous manifestation of psoriasis is absent, immunopathological assays are helpful in excluding from other oral dermatoses; however, sometimes there still exists a doubt regarding its diagnosis, making oral psoriasis an enigma or more specifically a diagnostic dilemma.<sup>[5]</sup>

### CONCLUSION

Oral psoriasis is a very rare entity and can be confused with other oral mucous membrane dermatoses. The prerequisite for diagnosing oral psoriasis is the presence of cutaneous lesions along with oral lesions that are diagnosed histopathologically following a biopsy of the lesion. Recent years have seen tremendous advances in the understanding of the pathogenesis of psoriasis due to newer genetic and immunological techniques. It has been proved that psoriasis is a chronic, immunologically mediated inflammatory disease that can act as a model for understanding other diseases of this genre. These basic scientific observations have galvanized the development of target-based biological treatments for the management of psoriasis; however, there are lacunae in the basic understanding of psoriasis specifically related to phenotypes and natural history of disease.<sup>[5]</sup> From the evidence available to date, it is still unclear whether oral psoriasis is a distinct entity or whether, indeed, it exists, making it a diagnostician's dilemma.

## REFERENCES

1. Krueger GG, Duvic M. Epidemiology of psoriasis: Clinical issues. *J Invest Dermatol* 1994;102:14S-18S.
2. Zhu JF, Kaminski MJ, Pulitzer DR, Hu J, Thomas HF. Psoriasis: Pathophysiology and oral manifestations. *Oral Dis* 1996;2:135-44.
3. Shafer WG, Hine MK, Levy BM. Diseases of the skin. A text book of oral pathology. Philadelphia: WB Saunders; 1983. p. 814-16.
4. Griffiths CE, Barker JN. Pathogenesis and clinical features of psoriasis. *Lancet* 2007;370:263-5.
5. Yesudian PD, Chalmers RJ, Warren RB, Griffiths CE. In search of oral psoriasis. *Arch Dermatol Res* 2012;304:1-5.
6. Hernández-Pérez F, Jaimes-Aveldañez A, Urquiza-Ruvalcaba Mde L, Diaz-Barcelot M, Irigoyen-Camacho ME, Vega-Memije ME, et al. Prevalence of oral lesions in patients with psoriasis. *Med Oral Patol Oral Cir Bucal* 2008;13:E703-8.
7. Oppenheim M. Psoriasis mucosae oris. *Monatsschr Prakt Dermatol* 1903;37:481.
8. Usher B. Psoriasis of the mucous membranes. A report of two cases with a review of the literature. *Arch Dermat Syph* 1933;28:488-96.
9. DeGregori G, Pippen R, Davies E. Psoriasis of the gingiva and the tongue: Report of a case. *J Periodontol* 1971;42:97-100.
10. Elliott JR, Bowers GM, Corio RL. The clinical problem of oral psoriasis. *Ear Nose Throat J* 1985;64:223-7.
11. Hietanen J, Salo OP, Kanerva L, Juvakoski T. Study of the oral mucosa in 200 consecutive patients with psoriasis. *Scand J Dent Res* 1984;92:50-4.
12. Kaur I, Handa S, Kumar B. Oral lesions in psoriasis. *Int J Dermatol* 1997;36:78-9.
13. Costa SC, Hirota SK, Takahashi MD, Andrade H Jr, Migliari DA. Oral lesions in 166 patients with cutaneous psoriasis: A controlled study. *Med Oral Patol Oral Cir Bucal* 2009;14:e371-5.
14. Daneshpazhooch M, Moslehi H, Akhyani M, Etesami M. Tongue lesions in psoriasis: A controlled study. *BMC Dermatol* 2004;4:16.
15. Pogrel MA, Cram D. Intraoral findings in patients with psoriasis with a special reference to ectopic geographic tongue (erythema circinata). *Oral Surg Oral Med Oral Pathol* 1988;66:184-9.
16. Nisengard RJ, Neiders M. Desquamative lesions of the gingiva. *J Periodontol* 1981;52:500-10.
17. Pisanty S, Ship II. Oral psoriasis. *Oral Surg Oral Med Oral Pathol* 1970;30:351-355.
18. Levin H. Psoriasis of the palate. *Oral Surg* 1954;7:280.
19. Brayshaw H, Orban B. Psoriasis gingivae. *J Periodontol* 1953;24:156.
20. Wooten JW, Tarsitano JJ, LaVere AM. Oral psoriasiform lesions: A possible prosthodontic complication. *J Prosthet Dent* 1970;24:145-7.
21. Tosti A, Misciali C, Cameli N, Vincenzi C. Guess what! Psoriasis of the lips. *Eur J Dermatol* 2001;11:589-90.
22. Rahman MA, Fikree M. Perioral psoriasis. *J Eur Acad Dermatol Venereol* 2000;14:521-2.
23. Yamamoto T, Nishioka K. Oral psoriasis in a patient with hepatitis C virus. *Eur J Dermatol* 2002;12:75-6.
24. Gül U, Kiliç A, Gönül M, Soyul S, Bilgili S, Han O. Psoriasis of the lips: An unusual localization. *Int J Dermatol* 2006;45:1381-2.
25. Buchner A, Begleiter A. Oral lesions in psoriatic patients. *Oral Surg Oral Med Oral Pathol* 1976;41:327-32.
26. Brenner S, Lipitz R, Ilie B, Krakowski A. Psoriasis of the lips: The unusual Köbner phenomenon caused by protruding upper teeth. *Dermatologica* 1982;164:413-6.
27. Halperin V, Kolas S, Jefferis KR, Huddleston SO, Robinson HB. The occurrence of Fordyce spots, benign migratory glossitis, median rhomboid glossitis, and fissured tongue in 2,478 dental patients. *Oral Surg* 1953;6:1072-7.
28. Hume WJ. Geographic stomatitis: A critical review. *J Dent* 1975;3:25-43.
29. Eidelman E, Chosack A, Cohen T. Scrotal tongue and geographic tongue: Polygenic and associated traits. *Oral Surg* 1976;42:591-6.
30. McCarthy FP. A clinical and pathologic study of oral disease. *J Am Med Assoc* 1941;116:16-21.
31. Ulmanský M, Michelle R, Azaz B. Oral psoriasis: Report of six new cases. *J Oral Pathol Med* 1995;24:42-5.
32. Bruce AJ, Rogers RS. Oral psoriasis. *Dermatol Clin* 2003;21:99-104.
33. Richardson LJ, Kratochvil FJ, Zieper MB. Unusual palatal presentation of oral psoriasis. *J Can Dent Assoc* 2000;66:80-2.
34. Eastman JR, Goldblatt LI. Psoriasis. Palatal manifestations and physiologic considerations. *J Periodontol* 1983;54:736-9.
35. Yamada J, Amar S, Petrungaro P. Psoriasis-associated periodontitis: A case report. *J Periodontol* 1992;63:854-7.
36. Lundberg M, Ericson S. Changes in the temporomandibular joint in psoriasis arthropathica. *Acta Derm Venereol* 1967;47:354-8.
37. Perlman S. Psoriatic arthritis: Natural history and prognosis. In: Berber L, Espinoza L, editors. *Psoriatic Arthritis*. New York: Grune and Stratton; 1985. p. 83-93.
38. Iacopino AM, Wathen WF. Craniomandibular disorders in the geriatric patient. *J Orofac Pain* 1993;7:38-53.
39. Van Scott EJ. Kinetics of hyperplasia in psoriasis. *Arch Dermatol* 1963;88:67.
40. Migliari DA, Penha SS, Marques MM, Matthews RW. Considerations on the diagnosis of oral psoriasis: A case report. *Med Oral* 2004;9:300-3.

**How to cite this article:** Khan S, Zaheer S, Gupta ND. Oral psoriasis: A diagnostic dilemma. *Eur J Gen Dent* 2013;2:67-71.

**Source of Support:** Nil, **Conflict of Interest:** None declared.