

# Orthodontic treatment in an endodontically treated maxillary incisors

Orlando Motohiro Tanaka, Jorge César Borges Leão Filho, Robert Willer Farinazzo Vitral<sup>1</sup>, José A. Bósio<sup>2</sup>

Graduate Dentistry Program in Orthodontics, Pontifícia Universidade Católica do Paraná, Curitiba,

<sup>1</sup>Graduate Program in Orthodontics, Juiz de Fora Federal University, Brazil, <sup>2</sup>Orthodontics, Marquette University School of Dentistry, Milwaukee, WI, USA

Address for correspondence:

Dr. Orlando Motohiro Tanaka,  
Graduate Dentistry Program,  
Orthodontics, Pontifícia Universidade  
Católica do Paraná School of  
Health and Biociences Bolsista da  
Capes – Proc. No BEX 1632/11 - 6 R.  
Imaculada Conceição, 1155,  
CEP: 80215 - 901 – Curitiba, Pr, Brazil.  
E-mail: tanakaom@gmail.com

## ABSTRACT

The purpose of this study was to analyze the effect of orthodontic movement on non-vital teeth, illustrated with a clinical case. A review of the literature shows it is controversial as to whether or not orthodontic forces can be initiated and sustained without the resorptive process occurring. Induced resorption during tooth movement depends on multiple factors, which require the close attention of the dentist to ensure an accurate diagnosis and correct mechanotherapy with respect to the periodontium. The orthodontic treatment described here was performed on a woman 36 years of age with endodontically treated teeth. This case demonstrated that the biomechanics follow biological principles and thus prevent deleterious effects on the components of the periodontium and the bone and maintains the integrity of the root length.

## Key words

Biomechanics, resorption, root canal therapy

## INTRODUCTION

Apical root resorption is an undesirable, though frequent, effect of orthodontic treatment, which results in loss of mineralized tissues such as dentin, cementum, and alveolar bone. It may be associated with pathological or physiological process.<sup>[1]</sup>

Root resorption resulting from orthodontic treatment is usually associated with inflammatory process in the periodontal ligament, resulting in shortening of the tooth apex.<sup>[2-4]</sup>

Some factors associated with root resorption include individual predisposition,<sup>[5]</sup> age<sup>[6]</sup> and gender,<sup>[7]</sup> root anatomy,<sup>[8]</sup> root morphology, bone morphology, movement of endodontically treated teeth,<sup>[9,10]</sup>

previously traumatized teeth,<sup>[11]</sup> deleterious habits, root development stage,<sup>[12,13]</sup> the type of orthodontic appliances used,<sup>[14,15]</sup> the type of teeth moved,<sup>[16]</sup> and the magnitude and duration of the treatment forces applied.<sup>[7,17]</sup> Systemic factors including hypothyroidism, hypophosphatemia, nutrition, and heredity can be also associated.<sup>[18]</sup>

Overall, orthodontics coexists peacefully with induced resorption during forced tooth movement. However, the magnitude of resorption is unpredictable and depends on multiple factors, such as careful clinical evaluation, correct diagnosis, appropriate biology of periodontium mechanotherapy, and periapical X-ray control.<sup>[6]</sup>

The risks of endodontically treated teeth movement involve not only root resorption, but also ankylosis and fractures due to extensive restoration and possible intracanal posts. However, orthodontists should be able to include the endodontically treated teeth in their treatment plans and mechanotherapy.<sup>[19]</sup>

The purpose of this article is to describe an orthodontic treatment for a patient with many endodontic treatments and large teeth reconstruction.

Access this article online	
Quick Response Code:	Website: www.ejgd.org
	DOI: 10.4103/2278-9626.106823

## CASE REPORT

A 36-year-old woman with no significant medical history reported a chief complaint of overlapping maxillary left central and lateral incisors and extensive dental reconstruction. Clinical examination revealed no evident skeletal disharmony, Angle Class II division 2 relationship with a normal overbite and overjet, crowded anterior teeth in both jaws, maxillary midline deviation toward the right side, and absence of maxillary first premolar [Figure 1a and c]. The maxillary right lateral incisor, maxillary right central incisor, and maxillary left central incisor were discolored [Figure 1b].

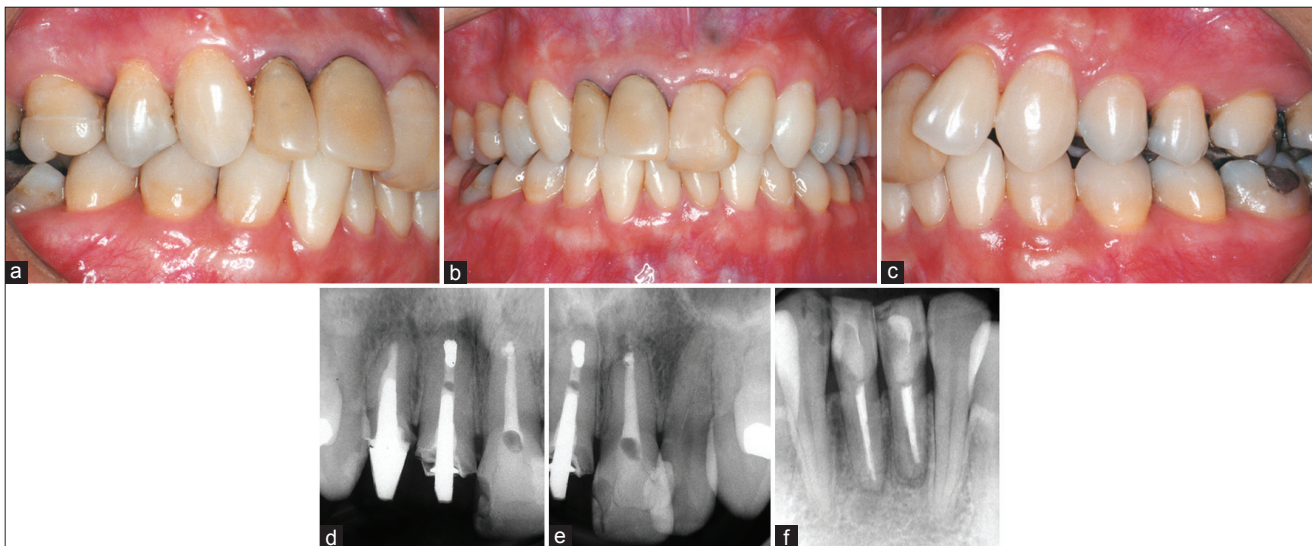
The panoramic radiograph showed all third molars missing, as was the maxillary right first premolar [Figure 2a]. Extensive restorations were performed to incisors, molars, and premolars. Maxillary right first molar, lateral incisor [Figure 1d and e], both central incisors, and mandibular central incisors had been endodontically treated. The maxillary right lateral incisor and central incisors were held in place with a large metallic intracanal post. The patient was referred to an endodontist due to the presence of a radiolucent image in the mandibular left central incisor [Figure 1f].

## Management

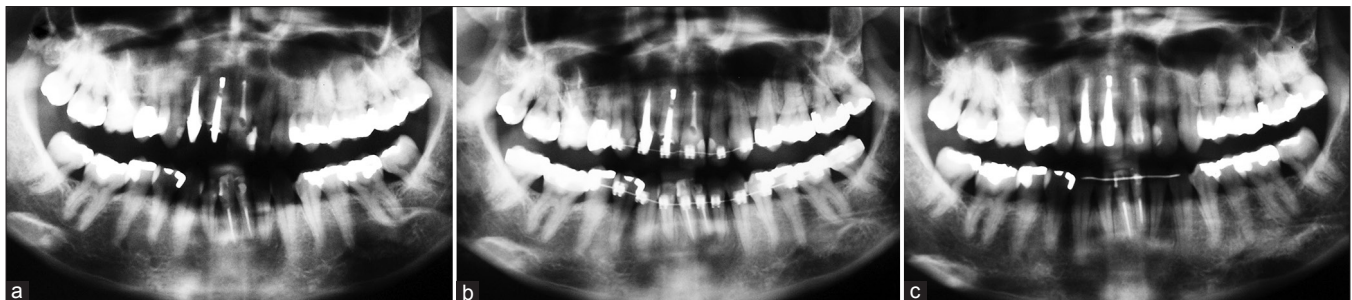The treatment plan involved the extraction of the upper left first premolar [Figure 3c], alignment, leveling, and intercuspation between the upper and lower teeth properly positioned at the maxilla. Radiographic evaluation was applied throughout the treatment due to root resorption and fracture possibilities of the endodontically and extensively restored treated teeth [Figures 2b and 3d-f]. An interdisciplinary approach was used with this patient. A 0.022-in standard, nontorqued, nonangulated, fixed orthodontic appliance, and round archwire were used for alignment and leveling, followed by rectangular archwires for completion and detail [Figure 3a and b]. Individual teeth were moved with an elastic power chain. Retention involved a removable wraparound maxillary Hawley-type retainer and a 0.028-in mandibular lingual retainer bonded only to the canines. The total treatment time was 34 months. Teeth were significantly moved to the left side to correct the maxillary midline deviation and to close the extraction site [Figures 2c and 4a-c].

## DISCUSSION

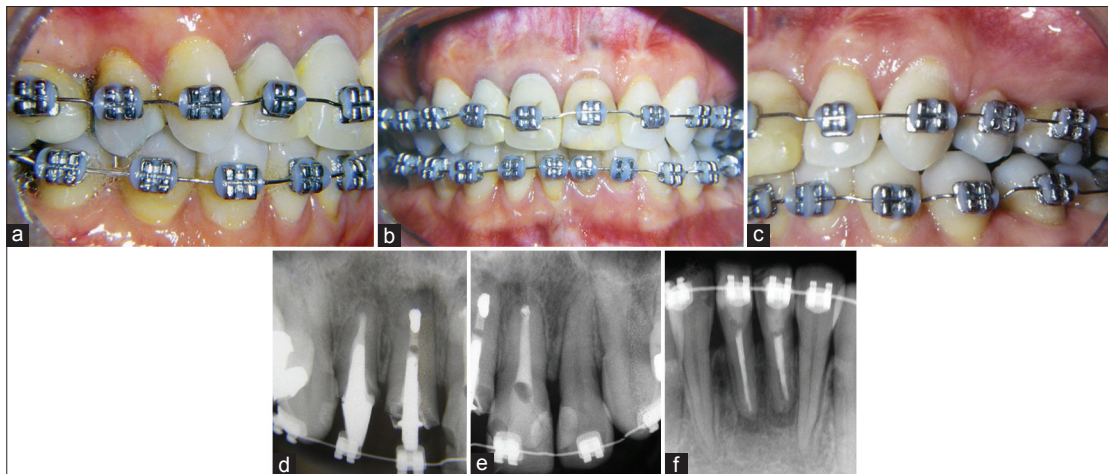
The orthodontic movement of teeth without pulp is



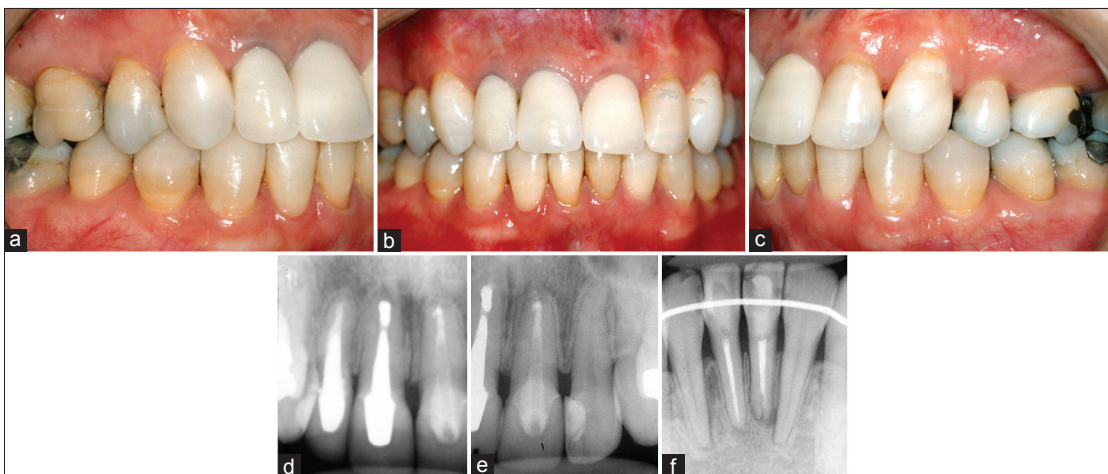
**Figure 1:** Pretreatment. (a) Color alteration in maxillary central and lateral incisors and in mandibular central incisors. (d-f) Both maxillary central incisors, maxillary right lateral incisor, and both mandibular central incisors with root canal therapy



**Figure 2:** Panoramic radiographs. (a) Pre-orthodontic. (b) Teeth movement 11 months into treatment. (c) Final radiograph after 34 months of orthodontic treatment



**Figure 3:** Progress: Radiographs taken eleven months after the beginning of orthodontic treatment. (a) Minor teeth movement on the right side, but (b) extensive movement in all endodontically treated teeth to align and correct the deviated midline. (c) The space resulting from the extraction of the maxillary left premolar was closed (d-f)



**Figure 4:** Final records. (a, c) Canines in good occlusion. (b) The maxillary right central and lateral incisors were rehabilitated with porcelain veneer. (d-f) the length of the roots was maintained

possible.<sup>[20,21]</sup> Teeth involved in endodontic therapy move as much as the vital teeth, but there are some questions associated with this movement.<sup>[22]</sup> Some authors believe that teeth that have undergone root canal therapy are more susceptible to root resorption,<sup>[19]</sup> whereas other authors found no significant difference.<sup>[23-25]</sup> Wickwire *et al.*<sup>[19]</sup> examined the effect of pulpectomy on tooth movement and showed that teeth without pulp are subject to a greater degree of resorption when compared to teeth with vitality. On the other hand, Bender *et al.*<sup>[26]</sup> observed greater resorption for vital teeth compared with endodontically treated teeth. Similarly, the endodontically treated teeth reabsorbed less frequently and with less severity than homologous teeth with vitality; however, there was no statistically significant difference between the degrees of root resorption.<sup>[1,3,18,27]</sup>

Mattison *et al.*<sup>[3]</sup> and Esteves *et al.*<sup>[28]</sup> found no statistically significant difference in the amounts of root resorption between endodontically treated teeth and homologous teeth with vitality when teeth were submitted to orthodontic

treatment. This evidence substantiates the present clinical case where the maxillary and mandibular incisors did not show any degree of root resorption during or after treatment. In addition, it is worth noting that there are significant associations between longer treatment durations and higher degrees of external root resorption.<sup>[15]</sup> Moreover, the use of heavy forces and prolonged treatment are directly related to increases in bone resorption associated with orthodontic treatment.<sup>[2,18,29,30]</sup> Although the treatment duration was 34 months, no major root or bone resorption was observed during the treatment of this adult patient.

When a tooth is subjected to an endodontic treatment, it becomes more fragile than a vital tooth due to structural defects generated during the canal instrumentation.<sup>[31]</sup> A tooth's resistance to fracture decreases significantly after endodontic treatment due to the mutilation of important parts of the dental structure. Another contributing factor to reduced resistance to tooth fracture is the decrease in dentin moisture due to the loss of blood supply, resulting

in a change in the resilience of the tooth. According to Garcia,<sup>[32]</sup> metal posts induce stress concentrated at the apex, which can lead to root fracture because a metal has greater modulus than the dentin. The patient was aware about the fracture risks due to the endodontic treatment and the large metallic intracanal post in the maxillary incisors. In addition, endodontic retreatment may be required if fracture occurs, and depending on the location of the fracture extraction could be necessary. However, the entire orthodontic treatment was carried out without any negative incident.

Another relevant detail to endodontically treated teeth is ankylosis. According to Biederman,<sup>[33]</sup> ankylosis is caused by a disturbance in the local metabolism of the periodontal ligament, resulting in the fusion of the alveolar bone with the cement. Ankylosis can be caused by disturbance of the alveolar bone and/or the periodontal ligament, originated in the orthodontic movement. Although the patient was apprised about this risk, there was no occurrence of ankylosis.

## CONCLUSION

Despite poor prognosis, risks of root resorption, fractures, and ankylosis, this case report demonstrated that orthodontic treatment can be performed with excellent results on patients with extensive endodontically compromised teeth.

## REFERENCES

- Kreia TB, Tanaka O, Lara F, Souza ES, Maruo H, Westphalen VP. Evaluation resorption after orthodontic treatment in endodontically treated teeth. *J Dent Sci* 2005;20:50.
- Brezniak N, Wasserstein A. Root resorption after orthodontic treatment: Part 1. Literature review. *Am J Orthod Dentofacial Orthop* 1993;103:62-6.
- Mattison GD, Delivanis HP, Delivanis PD, Johns PI. Orthodontic root resorption of vital and endodontically treated teeth. *J Endod* 1984;10:354-8.
- Travess H, Roberts-Harry D, Sandy J. Orthodontics. Part 6: Risks in orthodontic treatment. *Br Dent J* 2004;196:71-7.
- Artun J, Van't Hullenaar R, Doppel D, Kuijpers-Jagtman AM. Identification of orthodontic patients at risk of severe apical root resorption. *Am J Orthod Dentofacial Orthop* 2009;135:448-55.
- Lupi JE, Handelman CS, Sadowsky C. Prevalence and severity of apical root resorption and alveolar bone loss in orthodontically treated adults. *Am J Orthod Dentofacial Orthop* 1996;109:28-37.
- Hendrix I, Carels C, Kuijpers-Jagtman AM, Van't Hof M. A radiographic study of posterior apical root resorption in orthodontic patients. *Am J Orthod Dentofacial Orthop* 1994;105:345-9.
- Levander E, Malmgren O. Evaluation of the risk of root resorption during orthodontic treatment: A study of upper incisors. *Eur J Orthod* 1988;10:30-8.
- Mirabella AD, Artun J. Risk factors for apical root resorption of maxillary anterior teeth in adult orthodontic patients. *Am J Orthod Dentofacial Orthop* 1995;108:48-55.
- Spurrier SW, Hall SH, Joondeph DR, Shapiro PA, Riedel RA. A comparison of apical root resorption during orthodontic treatment in endodontically treated and vital teeth. *Am J Orthod Dentofacial Orthop* 1990;97:130-4.
- Malmgren O, Goldson L, Hill C, Orwin A, Petrini L, Lundberg M. Root resorption after orthodontic treatment of traumatized teeth. *Am J Orthod* 1982;82:487-91.
- da Silva Filho OG, Mendes Ode F, Ozawa TO, Ferrari Junior FM, Correa TM. Behavior of partially formed roots of teeth submitted to orthodontic movement. *J Clin Pediatr Dent* 2004;28:147-54.
- Odenrick L, Brattström V. The effect of nailbiting on root resorption during orthodontic treatment. *Eur J Orthod* 1983;5:185-8.
- Janson GR, De Luca Canto G, Martins DR, Henriques JF, De Freitas MR. A radiographic comparison of apical root resorption after orthodontic treatment with 3 different fixed appliance techniques. *Am J Orthod Dentofacial Orthop* 2000;118:262-73.
- McNab S, Battistutta D, Taverne A, Symons AL. External apical root resorption following orthodontic treatment. *Angle Orthod* 2000;70:227-32.
- Dermaut LR, De Munck A. Apical root resorption of upper incisors caused by intrusive tooth movement: A radiographic study. *Am J Orthod Dentofacial Orthop* 1986;90:321-6.
- Brin I, Tulloch JF, Koroluk L, Phillips C. External apical root resorption in Class II malocclusion: A retrospective review of 1-versus 2-phase treatment. *Am J Orthod Dentofacial Orthop* 2003;124:151-6.
- Brezniak N, Wasserstein A. Root resorption after orthodontic treatment: Part 2. Literature review. *Am J Orthod Dentofacial Orthop* 1993;103:138-46.
- Wickwire NA, Mc Neil MH, Norton LA, Duell RC. The effects of tooth movement upon endodontically treated teeth. *Angle Orthod* 1974;44:235-42.
- Drysdale C, Gibbs SL, Ford TR. Orthodontic management of root-filled teeth. *Br J Orthod* 1996;23:255-60.
- Komorowski R. Orthodontic forced eruption and endodontic treatment. *Ont Dent* 1997;74:20-1.
- Mattison GD, Gholston LR, Boyd P. Orthodontic external root resorption – Endodontic considerations. *J Endod* 1983;9:253-6.
- Huettner RI, Shore B, Young RW. The movability of vital and devitalized teeth in the Macacus rhesus monkey. *Am J Orthod* 1955;41:594.
- Mah R, Holland GR, Pehowich E. Periapical changes after orthodontic movement of root-filled ferret canines. *J Endod* 1996;22:298-303.
- Odenrick L, Brattström V. Nailbiting: Frequency and association with root resorption during orthodontic treatment. *Br J Orthod* 1985;12:78-81.
- Bender IB, Byers MR, Mori K. Periapical replacement resorption of permanent, vital, endodontically treated incisors after orthodontic movement: Report of two cases. *J Endod* 1997;23:768-73.
- Remington DN, Joondeph DR, Artun J, Riedel RA, Chapko MK. Long-term evaluation of root resorption occurring during orthodontic treatment. *Am J Orthod Dentofacial Orthop* 1989;96:43-6.
- Esteves T, Ramos AL, Pereira CM, Hidalgo MM. Orthodontic root resorption of endodontically treated teeth. *J Endod* 2007;33:119-22.
- Newman WG. Possible etiologic factors in external root resorption. *Am J Orthod* 1975;67:522-39.
- Segal GR, Schiffman PH, Tuncay OC. Meta analysis of the treatment-related factors of external apical root resorption. *Orthod Craniofac Res* 2004;7:71-8.
- Magne P, Knezevic A. Influence of overlay restorative materials and load cusps on the fatigue resistance of endodontically treated molars. *Quintessence Int* 2009;40:729-37.
- Garcia FC, D'alpino PH, Pereira JC, Mondelli RF. Restoration of an endodontically treated tooth with fiber-reinforced resin. *Rev Ibero-Am Odontol Estet Dent* 2003;2:315.
- Biederman W. The incidence and etiology of tooth ankylosis. *Am J Orthod* 1956;42:921.

**How to cite this article:** Tanaka OM, Filho JB, Vitral RF, Bósio JA. Orthodontic treatment in an endodontically treated maxillary incisors. *Eur J Gen Dent* 2013;2:72-5.

**Source of Support:** Nil, **Conflict of Interest:** None declared.