

Assessment of mandibular ramus thickness in Afro-Brazilian subjects using computed tomography

Paula Bonfim Almeida Costa, Marcos Alan Vieira Bittencourt,
Iêda Margarida Crusoé Rocha Rebello*

Departments of Orthodontics and ¹Radiology, School of Dentistry, Federal University of Bahia,
Salvador, Bahia, Brazil

Address for correspondence:

Prof. Paula Bonfim Almeida Costa,
Department of Orthodontics, School of
Dentistry, Federal University of Bahia,
Av Araujo Pinho, 62, 7 Andar, Canela,
40110-150, Salvador, Bahia, Brazil.
E-mail: paula_bonf@hotmail.com

ABSTRACT

Purpose: The purpose of this study was to investigate whether the skeletal pattern in the anteroposterior and vertical directions influences mandibular ramus thickness in Afro-Brazilian subjects, using computed tomography (CT). **Materials and Methods:** CT images of 45 individuals of Afro-Brazilian, from both genders, aged ranges between 19 and 46 years, were used. Determination of the skeletal pattern in the anteroposterior direction was based on the association of the ANB and WITS values, and in the vertical direction, through the GoGn-SN angle. Measurement of the mandibular ramus was performed just above the lingula in the coronal plane after three-dimensional reconstruction of the image and multiplanar analysis. **Results:** Twenty-seven of the 45 images were from individuals with Class I skeletal pattern, 13 Class II and 5 Class III, with means of 7.19 mm, 7.15 mm and 7.3 mm, respectively ($P = 0.95$). In the vertical direction, 4 individuals exhibited reduced vertical skeletal pattern, 28 normal pattern and 13 increased pattern, with means of 7.01 mm, 7.15 mm and 7.33 mm, respectively ($P = 0.77$). **Conclusion:** No statistically significant difference was found in mandibular ramus thickness in the different skeletal patterns, both in the anteroposterior and vertical directions.

Key words

African Continental Ancestry Group, mandible, osteotomy, sagittal split ramus, tomography, X-ray

INTRODUCTION

The modern era of orthognathic surgery was ushered in by the introduction, in 1957, of sagittal split ramus osteotomy (SSRO) by Trauner and Obwegeser.^[1] In 1961, this technique was modified by Dal Pont^[2] with the purpose of finding more reliable bone structures and reducing the risk of undesirable fractures. Subsequently, other authors such as Hunsuck,^[3] Epker,^[4] and Wolford *et al.*,^[5] suggested further changes, but the procedure performed today is similar to that described by Dal Pont,^[2] with minor modifications.

This technique is most often used in the correction of mandibular deformities since it divides the mandibular

ramus from the posterior portion of the body of the mandible sagittally. It can therefore be used for cases of retrognathia, mandibular prognathism and asymmetry.^[6-9] The approach is intraoral. A bone superimposition technique not only provides adequate healing, but also increases postoperative stability, allowing stabilization by means of rigid fixation with plates and screws. As a result, operative time is reduced and the need for maxillomandibular fixation eliminated.^[6,7]

However, despite many advantages, there is a significant risk of injury to the inferior alveolar nerve^[8] and mandibular fractures, especially during the medial horizontal cut.^[6-11] A decreased mediolateral mandibular ramus thickness, among other factors, predisposes to these surgical complications.^[12-14]

In their study Noletto *et al.*,^[9] Ma and Lu,^[10] Muto *et al.*,^[15] and Ribeiro *et al.*^[16] they found that the mandibular ramus of prognathous individuals is thinner and, according to Hallikainen *et al.*,^[17] neurosensorial changes are most often found in the correction of mandibular prognathism than in the correction of retrognathia because a thinner mandible predisposes to inferior alveolar nerve injuries.

Access this article online

Quick Response Code:



Website:
www.ejgd.org

DOI:
10.4103/2278-9626.134842

Since, it is a very popular technique, it is essential to carry out careful morphometric studies of the anatomical structures related to the bilateral sagittal split osteotomy of the mandibular ramus, especially regarding the medial horizontal cut, which can result in complications during surgery.

Kim *et al.*^[12] claimed that there are variations in the metric characteristics of the mandible between the different races. Since a large portion of the Brazilian population consists of individuals of African descent, and considering that there are no reports about the thickness of the mandibular ramus of these individuals, this study aimed to evaluate whether there are differences in mandibular ramus thickness in Afro-Brazilian subjects with different skeletal patterns in the anteroposterior and vertical directions.

METHODOLOGY

We used 45 computed tomography (CT) images belonging to the Department of Radiology, School of Dentistry, Federal University of Bahia, of 17 male and 28 female Afro-Brazilian subjects, who had at least one premolar and one molar in each quadrant and all the upper and lower incisors.

Racial profiling was performed using the classification adopted by the Brazilian Institute of Geography and Statistics (IBGE) (São Paulo/SP/FSP, 2000).

The images were acquired using a high resolution helical CT device (Helical CT Synergy, General Electric [GE] Company, Milwaukee, Wisconsin, USA). All patients underwent the examination in the supine position with the median sagittal plane perpendicular to the horizontal plane and Frankfort plane parallel to the opening of the gantry to ensure a constant orientation of the axial images. Light beams aided in the correct positioning of these planes. Contrast was not used in any patient. Axial cross-sections were performed with 1 mm thickness and 1 mm increment, as well as coronal reconstructions with 1mm thick cross-sections.

The images were analyzed in a GE advantage workstation in a private clinic in Salvador, Bahia State, Brazil, by a single previously calibrated examiner.

Skeletal pattern in the anteroposterior direction was determined using CT scout view images by combining ANB [Figure 1] and WITS [Figure 2] values. Individuals with ANB values between 0° and 4.5° were assigned a Class I skeletal pattern; greater than 4.5°, Class II, and lower than 0°, Class III. Female individuals whose WITS values ranged between -2 mm and 2 mm were considered to have Class I skeletal pattern, larger than 2 mm, Class II, and smaller than 2 mm, Class III. Male individuals whose WITS values ranged between -3 mm

and 1 mm were considered Class I skeletal pattern, larger than 1 mm, Class II, and smaller than -3 mm, Class III.^[18]

According to Jacobson,^[19] WITS measurements are linear and do not constitute a cephalometric analysis *per se* that is, they are only an auxiliary diagnostic tool, useful in checking the extent of the maxillary anteroposterior relationship and in determining the accuracy of the ANB angle.

Vertical pattern was evaluated using the GoGn-SN angle^[20] [Figure 3], measured on scout view images. Individuals with an angle smaller than or equal to 26° were considered to have a decreased vertical pattern; between 27 and 37, normal, and greater than or equal to 38, increased vertical pattern.

To measure mandibular ramus thickness, we initially performed a three-dimensional reconstruction of the image and a cursor was positioned just above the

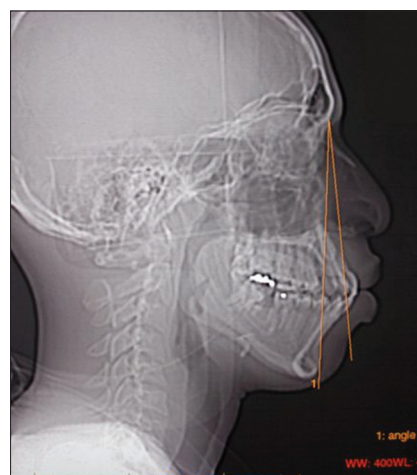


Figure 1: Measurement of the ANB angle on a scout view image to determine the skeletal pattern in the anteroposterior direction

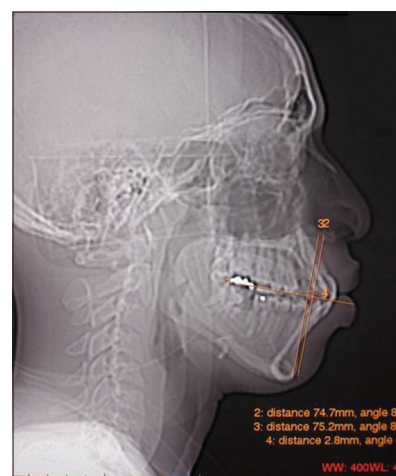

Figure 2: Measurement of WITS on a scout view image to determine the skeletal pattern in the anteroposterior direction

lingula [Figure 4a], generating images in axial [Figure 4b], sagittal [Figure 4c] and coronal [Figure 4d] cross-sections. Thus, the choice of an appropriate site to assess mandibular ramus thickness was made on a multiplanar basis, and in the coronal plane [Figure 4d] the horizontal linear thickness of the mandibular ramus was measured. This procedure was performed on the right and left sides, and the mean values between the two sides were subsequently calculated.

To examine any associations between mandibular

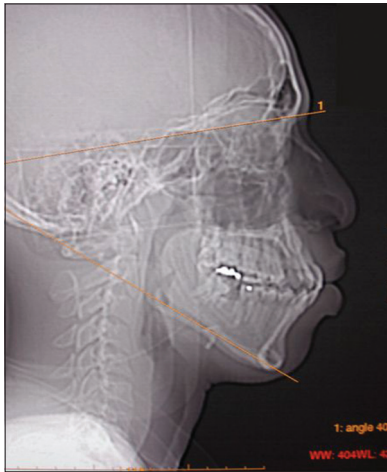

Figure 3: Measurement of the GoGn-SN angle on a scout view image to determine the skeletal pattern in the vertical direction

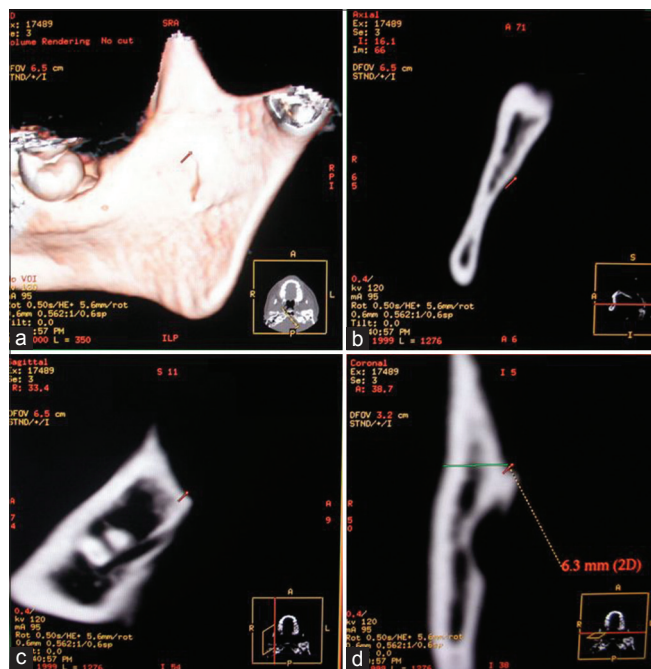


Figure 4: Multiplanar reconstruction with third dimension to measure mandibular ramus thickness. (a) Three-dimensional reconstruction of the mandibular ramus with a cursor positioned just above the lingula, (b) Axial cross-section of cursor position, (c) Sagittal cross-section of the same site, (d) Coronal cross-section of the same site, and measurement of mandibular ramus thickness

ramus thickness and skeletal pattern in the anteroposterior (Class I, II, or III) and vertical (decreased, normal or increased) directions, we used ANOVA. And to check whether a correlation existed between mandibular ramus thickness and the GoGn-SN angle, we used the Pearson correlation test. Associations with $P < 0.05$ were considered as statistically significant.

RESULTS

We used 45 CT images of individuals aged between 19 and 46 years (mean of 31 years). Twenty-seven of these patients had skeletal pattern Class I, 13 had Class II and 5, Class III. In the vertical direction, 28 individuals had a normal pattern, 13, increased and 4, decreased pattern.

Mandibular thickness variation in subjects with different skeletal patterns in the anteroposterior direction can be seen in Table 1. Table 2 shows the same variation in subjects with different skeletal patterns in the vertical direction. An analysis of these values reveals that mandibular ramus thickness does not exhibit any statistically significant difference in subjects with different skeletal patterns, neither in the anteroposterior [Table 1] nor in the vertical [Table 2] direction.

Likewise, as shown in Figure 1, no correlation was found between mandibular ramus thickness and the GoGn-SN angle ($r = -0.048$, $P = 0.75$) [Figure 5].

DISCUSSION

Orthognathic surgery places the maxillomandibular complex in a more balanced, functional and stable position and is therefore recommended for patients with dentomaxillofacial deformities whose magnitude exceeds

Table 1: Mean and SD of mandibular ramus thickness for individuals with Class I, Class II and Class III (n=45) skeletal patterns in the anteroposterior direction

Skeletal pattern in the anteroposterior direction	n	Mean (mm)	SD	P value
Class I	27	7.19	0.91	0.95
Class II	13	7.15	0.96	
Class III	5	7.30	0.82	

SD – Standard deviation

Table 2: Mean and SD of mandibular ramus thickness for individuals with decreased, normal and increased skeletal patterns (n=45) in the vertical direction

Skeletal pattern in the vertical direction	n	Mean (mm)	SD	P value
Decreased	4	7.01	0.53	0.77
Normal	28	7.15	0.90	
Increased	13	7.33	1.01	

SD – Standard deviation

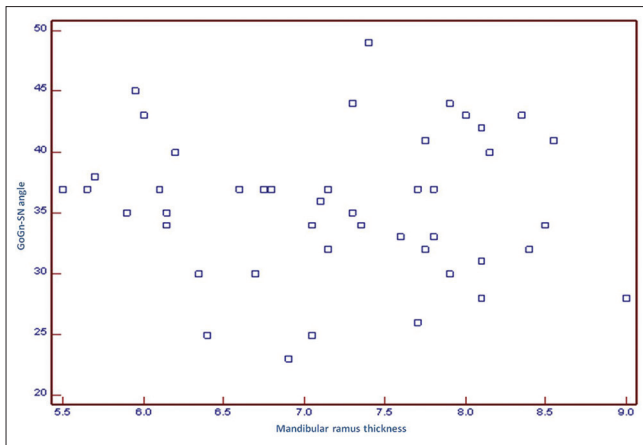


Figure 5: Correlation between mandibular ramus thickness and the GoGn-SN angle

the capabilities of orthodontic treatment alone.^[6,21] It provides individuals with not only facial esthetics and dental harmony, but also with improved psychosocial well-being and better quality of life.^[6,22] Assessment of the ideal moment for surgical intervention should be conducted jointly by orthodontist and surgeon. However, surgery is generally indicated after pubertal growth spurt. In this study, subject ages ranged from 19 to 46 years. Such selection aimed at minimizing the effects of growth on the results, while also taking into account that it is in this period that patients more often undergo orthognathic surgery.

Assessment of maxillomandibular deformities is commonly performed with the aid of cephalometry, which, by providing correlations between the diverse craniofacial structures, greatly contributes to planning. As described above, to determine the skeletal pattern in the anteroposterior direction of the individuals who participated in this sample, we combined the ANB angle with WITS measurements because this is the most reliable method, involving less variation. WITS analysis was used as a diagnostic aid because it does not undergo distortion as a result of variations in craniofacial features.^[18]

In this sample, there were a lower percentage of subjects with Class III skeletal pattern. This may be due to a lower incidence of mandibular prognathism in our population, whereas among Asians, especially among Koreans, this condition is very prevalent,^[12] which may explain the greater interest shown by individuals of this ethnic group in studies on the morphology of the mandible and features that influence SSRO.

The presence of a narrow mandibular ramus is a factor that predisposes to complications during surgical procedure.^[9,12-14] In this study, in order to evaluate mandibular ramus thickness, we initially performed a three-dimensional reconstruction of the image,

positioned a cursor just above the lingula and obtained a multiplanar view of the image. Thus, we were able to perform the measurements in the coronal plane with absolute certainty that we would actually be evaluating thickness at the desired site.

Formerly, it was advocated that the medial horizontal cut of sagittal osteotomy should be performed just below the mandibular notch, extending to the posterior edge of the ramus, as suggested by Trauner and Obwegeser^[1] in 1957. However, other studies^[2,4] have shown that this cut should be made just above the lingula and should not extend to the posterior edge to avoid complications during surgery. This recommendation is in line with the anatomical findings of Smith *et al.*^[7] and Kim *et al.*,^[12] who report that there is a decrease in the amount of cancellous bone in the mandibular ramus, as one moves from inferior to superior, and from anterior to posterior. Based on the clinical experience and anatomical studies, Smith *et al.*,^[7] Kim *et al.*^[12] and Tom *et al.*^[23] showed that by positioning the medial osteotomy near the lingula one can reach the region below the fusion of the medial and lateral cortices, whereas the presence of cancellous bone between the two cortices allows a cleavage plane that facilitates separation at the planned site. Therefore, based on several anatomical studies, the vast majority of surgeons currently perform the horizontal sagittal osteotomy cut just above the lingula. It is for this reason that, for the purpose of this study, this was the site of choice to perform the measurement in order to check whether mandibular ramus thickness varies in different skeletal patterns, in the anteroposterior and vertical direction, in Afro-Brazilian subjects.

Kim *et al.*^[12] claim, based on anthropological surveys, that the metric features of the mandible vary between races, and reported that the mandibular ramus of Koreans is the widest among Asians, albeit smaller than that of Caucasians.

There are no reports in the literature about the thickness of the mandibular ramus in Afro-Brazilian individuals. This study was similar to that conducted by Noletto *et al.*^[9] Muto *et al.*^[15] and Ribeiro *et al.*,^[16] but they did not report which ethnicity was being evaluated. Noletto *et al.*^[9] observed a statistically significant difference between the thickness of the mandibular ramus in individuals with prognathism and retrognathia, and found a smaller thickness in the former, with a mean of 8.17 mm, than in the latter with a mean of 8.88 mm. Ribeiro *et al.*^[16] also observed a statistically significant difference between the thickness of the mandibular ramus in individuals with prognathism and retrognathia, and found a mean of 7.8 mm and 8.84 mm, respectively. According to these authors, were they to eliminate two individuals from the prognathous group, who had very high means, the mean would fall from 7.8 mm to 7.45 mm, approaching the value found by Muto *et al.*,^[15] who in

addition to reduced thickness of the mandibular ramus in prognathous individuals, also found greater variety in the conformation of cancellous bone. The mean thickness of the mandibular ramus in the middle third of prognathous individuals studied by Muto *et al.*^[15] was 7.28 mm, while orthognathic individuals exhibited a mean of 7.91 mm. In the anterior third of the mandibular ramus, the mean was 7.36 mm for prognathous and 8.71 mm for orthognathic individuals. Ribeiro *et al.*^[16] compared the means found in the anterior third by Muto *et al.*^[15] with their own results, obtained just above the lingula, but a comparison with the values found in the middle third would have been more consistent. This study also evaluated mandibular ramus thickness just above the lingula, but found no statistically significant difference in mandibular ramus thickness in the different skeletal patterns, with a mean of 7.19 mm for Class I, 7.15 mm for Class II, and 7.3 mm for Class III. This suggests that the mandibular ramus thickness of Class III individuals of Afro-Brazilian subjects is no different from the mandibular ramus thickness of Afro-Brazilian Classes I or II, contrary to what was found in other studies that evaluated patients without defining ethnicity.

Tsunori *et al.*^[24] correlated the thickness of the body of the mandible with facial pattern and found a significant and complex relationship since short-faced individuals exhibit greater thickness compared with medium or long-faced individuals. There are no studies in the literature that relate mandibular ramus to facial pattern. This study aimed to investigate the relationship between ramus thickness and vertically decreased, normal and increased skeletal patterns, whose means were found to be 7 mm, 7.1 mm and 7.3 mm, respectively. Moreover, we found no statistically significant difference in mandibular ramus thickness between the various vertical skeletal patterns.

Through imaging, we can assess surgical risks and prevent potential complications. However, according to Ylikontiola *et al.*^[14] and Yu and Wong^[25] it is not possible to determine the location of the mandibular canal by panoramic radiography. The study conducted by these authors reveals that CT examination is superior because conventional radiographs feature lower accuracy, image distortion, overlapping structures and depict only two-dimension, making it impossible to assess depth,^[26] which can only be analyzed through three-dimensional images. CT is essential to determine mandible morphology. Muto *et al.*^[15] and Hallikainen *et al.*^[17] recommend the use of CT routinely before SSRO to evaluate the distribution of bone marrow and the precise location of the mandibular canal. Moreover, Noleto *et al.*^[9] and Ylikontiola *et al.*^[14] point out that the use of CT is essential, especially in cases of patients with narrow mandibular rami.

CONCLUSION

Mandibular ramus thickness showed no statistically significant difference in subjects with different skeletal patterns, neither in the anteroposterior nor in the vertical direction, demonstrating that individuals with different facial patterns may exhibit mandibular rami that share similar characteristics.

REFERENCES

1. Trauner R, Obwegeser H. The surgical correction of mandibular prognathism and retrognathia with consideration of genioplasty. I. Surgical procedures to correct mandibular prognathism and reshaping of the chin. *Oral Surg Oral Med Oral Pathol* 1957;10:677-89.
2. Dal Pont G. Retromolar osteotomy for the correction of prognathism. *J Oral Surg Anesth Hosp Dent Serv* 1961;19:42-7.
3. Hunsuck EE. A modified intraoral sagittal splitting technic for correction of mandibular prognathism. *J Oral Surg* 1968;26:250-3.
4. Epker BN. Modifications in the sagittal osteotomy of the mandible. *J Oral Surg* 1977;35:157-9.
5. Wolford LM, Bennett MA, Rafferty CG. Modification of the mandibular ramus sagittal split osteotomy. *Oral Surg Oral Med Oral Pathol* 1987;64:146-55.
6. Almeida JC Jr, Cavalcante JR. Osteotomia sagital do ramo mandibular e osteotomia total de maxila: Uma revisão da literatura. *Pesqui Bras Odontopediatria Clin Integr* 2004;4:249-58.
7. Smith BR, Rajchel JL, Waite DE, Read L. Mandibular ramus anatomy as it relates to the medial osteotomy of the sagittal split ramus osteotomy. *J Oral Maxillofac Surg* 1991;49:112-6.
8. Yamauchi K, Takahashi T, Kaneuji T, Nogami S, Yamamoto N, Miyamoto I, *et al.* Risk factors for neurosensory disturbance after bilateral sagittal split osteotomy based on position of mandibular canal and morphology of mandibular angle. *J Oral Maxillofac Surg* 2012;70:401-6.
9. Noleto JW, Marchiori E, Da Silveira HM. Evaluation of mandibular ramus morphology using computed tomography in patients with mandibular prognathism and retrognathia: Relevance to the sagittal split ramus osteotomy. *J Oral Maxillofac Surg* 2010;68:1788-94.
10. Ma J, Lu L. Computed tomography morphology of the mandibular ramus at the lingual plane in patients with mandibular hyperplasia. *Int J Oral Maxillofac Surg* 2009;38:823-6.
11. Wyatt WM. Sagittal ramus split osteotomy: Literature review and suggested modification of technique. *Br J Oral Maxillofac Surg* 1997;35:137-41.
12. Kim HJ, Lee HY, Chung IH, Cha IH, Yi CK. Mandibular anatomy related to sagittal split ramus osteotomy in Koreans. *Yonsei Med J* 1997;38:19-25.
13. Nishioka GJ, Aragon SB. Modified sagittal split technique for patients with a high lingula. *J Oral Maxillofac Surg* 1989;47:426-7.
14. Ylikontiola L, Moberg K, Huumonen S, Soikkonen K, Oikarinen K. Comparison of three radiographic methods used to locate the mandibular canal in the buccolingual direction before bilateral sagittal split osteotomy. *Oral Surg Oral Med Oral Pathol Oral Radiol Endod* 2002;93:736-42.
15. Muto T, Shigeo K, Yamamoto K, Kawakami J. Computed tomography morphology of the mandibular ramus in prognathism: Effect on the medial osteotomy of the sagittal split ramus osteotomy. *J Oral Maxillofac Surg* 2003;61:89-93.
16. Ribeiro DP, Gandelmann IH, Medeiros PJ. Comparison of mandibular rami width in patients with prognathism and retrognathia. *J Oral Maxillofac Surg* 2006;64:1506-9.
17. Hallikainen D, Iizuka T, Lindqvist C. Cross-sectional tomography

- in evaluation of patients undergoing sagittal split osteotomy. *J Oral Maxillofac Surg* 1992;50:1269-73.
18. Jacobson A. The "Wits" appraisal of jaw disharmony. *Am J Orthod* 1975;67:125-38.
 19. Jacobson A. Update on the Wits appraisal. *Angle Orthod* 1988;58:205-19.
 20. Steiner CC. Cephalometric for you and me. *Am J Orthod* 1953;39:729.
 21. Boeck EM, Kuramae M, Lunardi N, Santos-Pinto Ad, Mazzonetto R. Cephalometric evaluation of surgical mandibular advancement. *Braz Oral Res* 2010;24:189-96.
 22. Venugoplan SR, Nanda V, Turkistani K, Desai S, Allareddy V. Discharge patterns of orthognathic surgeries in the United States. *J Oral Maxillofac Surg* 2012;70:e77-86.
 23. Tom WK, Martone CH, Mintz SM. A study of mandibular ramus anatomy and its significance to sagittal split osteotomy. *Int J Oral Maxillofac Surg* 1997;26:176-8.
 24. Tsunori M, Mashita M, Kasai K. Relationship between facial types and tooth and bone characteristics of the mandible obtained by CT scanning. *Angle Orthod* 1998;68:557-62.
 25. Yu IH, Wong YK. Evaluation of mandibular anatomy related to sagittal split ramus osteotomy using 3-dimensional computed tomography scan images. *Int J Oral Maxillofac Surg* 2008;37:521-8.
 26. Alder ME, Deahl ST, Matteson SR. Clinical usefulness of two-dimensional reformatted and three-dimensionally rendered computerized tomographic images: Literature review and a survey of surgeons' opinions. *J Oral Maxillofac Surg* 1995;53:375-86.

How to cite this article: Costa PA, Bittencourt MV, Rocha Rebelo IC. Assessment of mandibular ramus thickness in Afro-Brazilian subjects using computed tomography. *Eur J Gen Dent* 2014;3:140-5.

Source of Support: Nil, **Conflict of Interest:** None declared.

Staying in touch with the journal

1) Table of Contents (TOC) email alert

Receive an email alert containing the TOC when a new complete issue of the journal is made available online. To register for TOC alerts go to www.ejgd.org/signup.asp.

2) RSS feeds

Really Simple Syndication (RSS) helps you to get alerts on new publication right on your desktop without going to the journal's website. You need a software (e.g. RSSReader, Feed Demon, FeedReader, My Yahoo!, NewsGator and NewzCrawler) to get advantage of this tool. RSS feeds can also be read through FireFox or Microsoft Outlook 2007. Once any of these small (and mostly free) software is installed, add www.ejgd.org/rssfeed.asp as one of the feeds.