

# Oehler's type III dens invaginatus: A case report with 1-year follow-up

Liza George, Ajit G. Mohan, Justin Mathew<sup>a</sup>

Departments of Conservative Dentistry and Endodontics and <sup>b</sup>Oral and Maxillofacial Surgery, Annoor Dental College, Muvattupuzha, Kerala, India

Address for correspondence:

Dr. Liza George,  
Department of Conservative Dentistry  
and Endodontics, Annoor Dental  
College, Muvattupuzha, Kerala, India.  
E-mail: abyiliz@hotmail.com

## ABSTRACT

Dens invaginatus is a rare anomaly that occurs due to deepening of enamel organ into the root, either fully or partially during tooth development. The purpose of this paper is to present a case of Oehler's type III dens invaginatus on a maxillary left lateral incisor with a large periapical lesion. Combined endodontic therapy and surgery showed good healing when the patient was evaluated clinically and radiographically after 1-year. This case report highlights the importance of proper debridement of the main canal of a case of dens invaginatus because of its complex anatomy.

## Key words

Dens invaginatus, maxillary lateral incisor, invagination, periapical lesion

## INTRODUCTION

Dens invaginatus or dens in dente occurs as a result of deepening or invagination of the dental papilla prior to calcification of the dental tissues.<sup>[1]</sup> The maxillary lateral incisor is the most commonly affected teeth with a prevalence of 0.25-5.1%.<sup>[2]</sup> According to Oehlers, dens invaginatus can be classified into three categories depending on the depth of enamel invagination inside the tooth.<sup>[3]</sup> Type I is reported to be the most common (79%) followed by type II (15%) and type III (5%).<sup>[4]</sup> This case report presents a case of type III dens invaginatus involving maxillary lateral incisor where conventional endodontic treatment was initially attempted followed by periapical surgery.

## CASE REPORT

A 35-year-old male patient came to the dental office for routine check-up. On examination, tooth number 22 showed discoloration and a swelling was seen on the left side of the palate in the apical area of tooth numbers

21, 22, and 23. The swelling was firm and there was no associated sinus opening. The pulp sensibility test was done with electric pulp tester and tooth number 22 gave a negative response [Figure 1]. Intraoral periapical radiograph showed type III dens invaginatus involving the tooth number 22 and a large radiolucency extending from tooth number 21 on the mesial side to tooth number 23 on the distal side [Figure 2].

Considering the extent of the lesion, root canal treatment was started in all the three teeth under rubber dam isolation after administering local anesthesia using 2% lidocaine plus 1:1,000,000 epinephrine. Access opening was first initiated on tooth number 22 and a wide mesiodistal oval shaped cavity was made using no-2 round bur. With the aid of the LN bur (Dentsply Maillefer, Tulsa, OK, USA) and DG-16 endodontic explorer (Hu-Friedy, Chicago, IL, USA) two orifices were detected and their patency was ascertained using No-10 K file (Dentsply, Maillefer). No communication was observed between the main canal and invagination. The orifices were enlarged at the coronal and middle third using Gates-Glidden drills numbers 1 and 2 [Figure 3]. The canals were irrigated with 5.25% sodium hypochlorite, 17% ethylene diamine tetra acetic acid and finally rinsed with 0.9% saline. The working length of main canal and invagination was determined using apex locator (Root ZX, J Morita, Japan) and confirmed with radiograph. Both were enlarged using step back technique up to No-40 K file (Dentsply, Maillefer). The canals were dried with sterile paper points (Dentsply, Maillefer) and calcium hydroxide (Calcicur; VOCO, Cuxhaven, Germany) was

Access this article online	
Quick Response Code:	Website: www.ejgd.org
	DOI: 10.4103/2278-9626.134846

placed as the intracanal medicament. The access cavity was sealed temporarily with Cavit (3M ESPE AG, Seefeld, Germany). Simultaneously access opening was done on tooth numbers 21 and 23, working length established, cleaned and shaped, the intracanal medicament placed and the access cavity was sealed.

The patient was recalled after 1-month and on examination the swelling persisted on the palatal aspect and the tooth number 22 was tender on percussion. The patient was posted for periapical surgery. Prior to surgery the three teeth were obturated with Gutta-percha (Dentsply, Maillefer, Ballaigues, Switzerland) using lateral condensation technique with AH Plus sealer (Dentsply, Maillefer). The access cavity was sealed with Glass ionomer cement (Fuji IX; GC Corp., Tokyo, Japan) and later confirmed with radiograph [Figure 4].

A buccal full-thickness trapezoidal mucoperiosteal flap was elevated to expose the area of periapical lesion. Already existing pathological cortical bone window was expanded until underlying pathology was adequately exposed. Cystic enucleation was carried out under direct vision and the cyst was removed in-toto. Root

resection was not done to maintain maximum cemental covering on the root surface and to maintain the original root length to help tooth stability. Gutta-percha at the exposed root surface was burnished. The bony cavity was irrigated with saline followed by closure of the site after hemostasis. Postoperative period was uneventful. The cystic sac was submitted for histopathological examination and the lesion was diagnosed as radicular cyst. Patient was reviewed at intervals of 3 months, 6 months, and 1-year and the radiograph showed good healing [Figure 5].

## DISCUSSION

Dens invaginatus is commonly overlooked because of absence of any significant clinical signs of anomaly. However, the tooth is more susceptible to caries, periapical pathology and periodontal inflammation due to enamel defects in the invaginated area.<sup>[5]</sup> Early intervention of the pit with acid etch restoration will prevent pulpal involvement.<sup>[6]</sup>

Types I and II dens invaginatus do not present treatment problems. It is only necessary to remove the

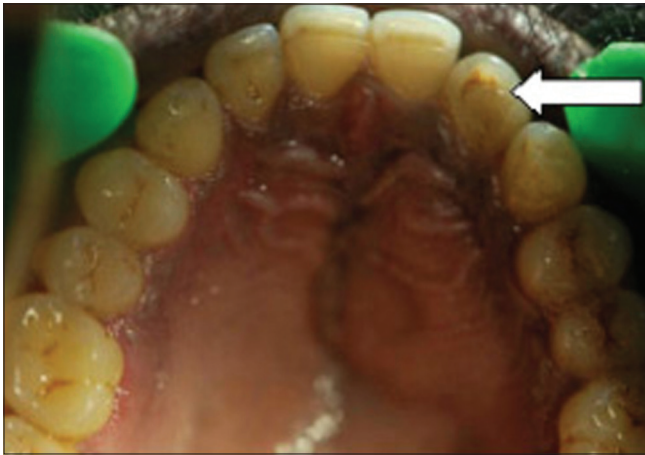

Figure 1: Maxillary lateral incisor with dens invaginatus

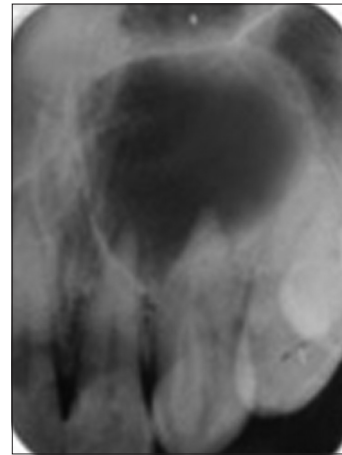


Figure 2: Radiograph showing dens invaginatus in tooth 22 with periapical lesion

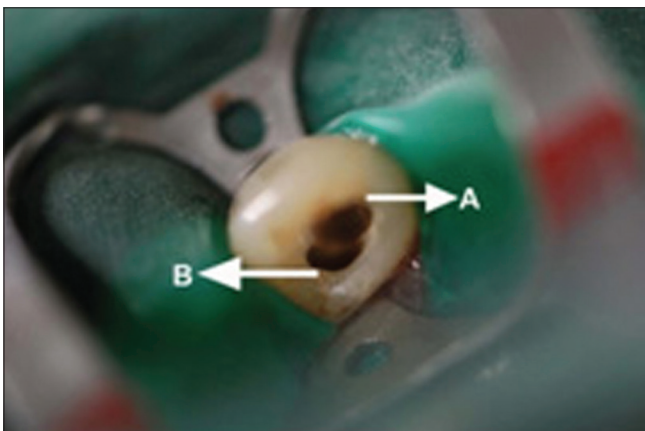


Figure 3: A - Main canal. B - Invagination

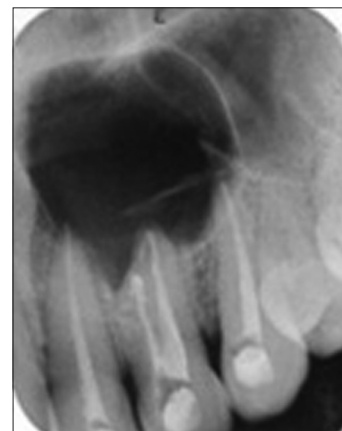

Figure 4: Postobturation radiograph

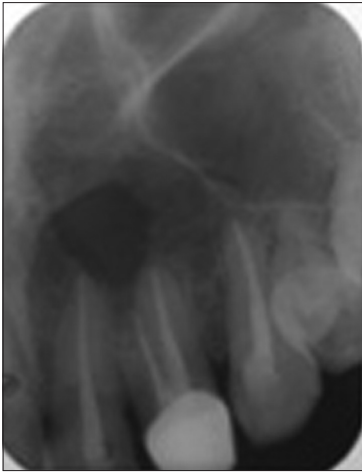

Figure 5: Radiograph after 1-year showing healing

invagination, create a tooth with a single canal, and do conventional endodontic treatment.<sup>[7]</sup> For cases of type III, invagination presents communication with the oral cavity.<sup>[8]</sup> Some authors have described nonsurgical treatments;<sup>[9]</sup> and there are also periodontal surgery case reports.<sup>[10]</sup> Extraction is indicated in case of teeth with poor prognosis.<sup>[11]</sup> This was a case of type III dens invaginatus, having two orifices, the main canal and the invagination, both exits separately at the apex. The apical exit of the invagination is the pseudo foramen and that of the main canal is the apical foramen.

Conservative treatment of any lesion is preferred over surgery as most periapical lesions are the inflammatory response to bacterial infection within the root canal. In nonsurgical management, root canal system is cleaned and disinfected; thereby periapical healing occurs. However in those cases in which causative factors are outside the root canal such as cyst, periapical surgery is indicated.

Calcium hydroxide intracanal medicament facilitates healing in nonvital teeth with periapical lesion. Herein, this case calcium hydroxide medication was attempted. Follow-up after 1 month revealed that the tooth was symptomatic and the swelling persisted. Hence, the treatment was changed to surgical intervention according to the clinical need.<sup>[12]</sup>

Invaginated teeth present technical difficulties due to its complex anatomy, the greatest of which was to locate the canals. The use of dental operating microscope, magnification loops and ultrasonic instruments is a

valuable adjunct for visualizing the canals, thereby enhancing the success of the treatment.

At the 6 months and 1-year postoperative recall examination, the tooth was asymptomatic and radiographically showed signs of healing.

## CONCLUSION

Type III dens invaginatus is a rare occurrence. Careful preoperative radiographic evaluation, a thorough knowledge of anatomical changes along and correct treatment procedure are necessary for success of the treatment.

## REFERENCES

1. Hülsmann M. Dens invaginatus: Aetiology, classification, prevalence, diagnosis, and treatment considerations. *Int Endod J* 1997;30:79-90.
2. Mupparapu M, Singer SR. A rare presentation of dens invaginatus in a mandibular lateral incisor occurring concurrently with bilateral maxillary dens invaginatus: Case report and review of literature. *Aust Dent J* 2004;49:90-3.
3. Oehlers FA. Dens invaginatus (dilated composite odontome). I. Variations of the invagination process and associated anterior crown forms. *Oral Surg Oral Med Oral Pathol* 1957;10:1204-18.
4. Ridell K, Mejäre I, Matsson L. Dens invaginatus: A retrospective study of prophylactic invagination treatment. *Int J Paediatr Dent* 2001;11:92-7.
5. Kramer IR. The pathology of pulp death in non-carious maxillary incisors with minor palatal invaginations. *Proc R Soc Med* 1953;46:503-5.
6. Tewari S, Govilla CP, Dobhal AK. Dens invaginatus and its management. *Endod* 1990;2:15-8.
7. Steffen H, Splieth C. Conventional treatment of dens invaginatus in maxillary lateral incisor with sinus tract: One year follow-up. *J Endod* 2005;31:130-3.
8. Kristoffersen Ø, Nag OH, Fristad I. Dens invaginatus and treatment options based on a classification system: Report of a type II invagination. *Int Endod J* 2008;41:702-9.
9. Er K, Kustarci A, Ozan U, Tasdemir T. Nonsurgical endodontic treatment of dens invaginatus in a mandibular premolar with large periradicular lesion: A case report. *J Endod* 2007;33:322-4.
10. Sauveur G, Roth F, Sobel M, Boucher Y. Surgical treatment of a periradicular lesion on an invaginated maxillary lateral incisor (dens in dente). *Int Endod J* 1997;30:145-9.
11. Kallianpur S, Sudheendra U, Kasetty S, Joshi P. Dens invaginatus (type III B). *J Oral Maxillofac Pathol* 2012;16:262-5.
12. Nair PN. New perspectives on radicular cysts: Do they heal? *Int Endod J* 1998;31:155-60.

**How to cite this article:** George L, Mohan AG, Mathew J. Oeler's type III dens invaginatus: A case report with 1-year follow-up. *Eur J Gen Dent* 2014;3:155-7.

**Source of Support:** Nil, **Conflict of Interest:** None declared.