

Combined treatment of a lateral incisor with palato-radicular groove: 1 year follow-up

Gülen Kamak, Sümeyra Akman

Departments of Periodontology, School of Dentistry, University of Kırıkkale, Kırıkkale,
 1Erzurum Dental Hospital, Erzurum, Turkey

Address for correspondence:

Mrs. Gülen Kamak,
 Department of Periodontology, School
 of Dentistry, University of Kırıkkale,
 Kırıkkale, Turkey.
 E-mail: dtglen@gmail.com

ABSTRACT

Periodontic – endodontic lesion with a palato-radicular groove as a contributing factor for periodontitis is the most important diagnostic and therapeutic challenges faced by periodontists and the maxillary lateral incisors are the most frequently affected teeth. These developmental grooves promotes the accumulation of plaque and calculus, which destroys the sulcular epithelium and later deeper parts of the periodontium, finally resulting in the formation of a severe localized periodontal lesion since proper cleaning of that site is difficult, if not impossible, for the patient. There are different types of treatment such as scaling and root planning, odontoplasty, amalgam restoration, and extraction of the tooth to treat palatogingival groove and associated periodontal bone defects. In this case, a successful management of an endodontic-periodontal combined lesion by combined treatment and guided tissue regeneration was presented.

Key words

Combined endodontic periodontal lesion, combined treatment, guided tissue regeneration, maxillary incisors, palato-radicular groove, periodontitis

INTRODUCTION

Palato-radicular groove (PRG) is a developmental anomaly in tooth morphology and it's characterized by a depression or concavity.^[1] This malformation can be named in different ways such as; distolingual groove, radicular lingual groove or palatogingival groove. These developmental grooves promotes the accumulation of plaque and calculus which destroys the sulcular epithelium and later deeper parts of the periodontium, finally resulting in the formation of a severe localized periodontal lesion since proper cleaning of that site is difficult, if not impossible, for the patient. This malformation often presents diagnostic and treatment planning challenges due to the combined endodontic-periodontal lesion. PRGs represent an infolding of the enamel organ and the epithelial sheath of Hertwig.^[2] However, some authors have also suggested a genetic susceptibility of this groove.^[1]

The combination of endodontic therapy and periodontal regenerative procedure is a successful choice for the treatment of endodontic-periodontal combined lesions.^[3] For reaching successful treatment outcome; case selection and the appropriate treatment modalities are necessary. Various degrees of periodontal regeneration with guided tissue regeneration (GTR) which was first described in 1980s have been demonstrated in both human and animal studies^[4] GTR therapy has also been implemented as a concomitant treatment during the management of the endodontic-periodontal lesions.^[5]

Here, we report a case in which endodontic therapy followed by periodontal flap surgery combined with odontoplasty was performed.

CASE REPORT

A 34-year-old male came to our clinic with the complaint of intermittent discharge of pus in relation to palatal aspect of tooth 12 and halitosis for the past 3 months. On clinical examination, there was a draining periodontal pocket on the palatal aspect of tooth 12. There was no history of trauma and the medical history was noncontributory. The tooth had no significant mobility. Medical history was noncontributory and the underlying periodontal condition was unremarkable at the labial aspect of the

Access this article online

Quick Response Code:



Website:
www.ejgd.org

DOI:
 10.4103/2278-9626.134852

tooth [Figure 1]. In general, the oral hygiene was fair. The vitality of tooth 12 was tested with an electronic pulp tester (Parkell Electronics Division, New York, USA) and a negative response confirmed the diagnosis of a nonvital pulp. At the clinical examination, it was detected that deep periodontal pockets were localized at the distopalatal (6 mm), midpalatal (9 mm) and mesiopalatal (10 mm) aspect of the tooth and concomitantly, at the distopalatal aspect a palatogingival groove which extended into the gingival sulcus was present. There was no periodontal pocket at the labial aspect of the tooth. The surrounding gingiva was reddish, soft and edematous. Periodontal pocket revealed a communication with the periapical area, confirming chronic suppurative apical periodontitis with pulp necrosis of tooth 12. An intraoral periapical radiograph revealed a large periapical lesion with a bony defect extending beyond the apical third of the root [Figure 2]. The bony lesion appeared to be a combined endodontic-periodontal problem. Our treatment plan consisted of nonsurgical root canal therapy followed by surgical management of periodontal defect.

Initial periodontal treatment consisting of oral hygiene instructions and localized scaling and root planning on right maxillary lateral incisor was completed and then endodontic therapy – root canal treatment was made. Although clinical symptoms subsided a few days later, the deep pocket was still present and hence a periodontal surgery was done to eradicate the underlying problem.

A full thickness mucoperiosteal flap with releasing incisions was reflected on palatal surface. After reflecting a full thickness mucoperiosteal flap there was a bony defect surrounding the mesiopalatal surface. Granulation tissue was removed from the bony defect and it was seen that the PRG was terminated in the middle portion of the tooth. Further root planning was performed and

fort the elimination of PRG, odontoplasty was carried out [Figure 3].

After the root conditioning with tetracycline hydrochloride for 3 min, irrigation with normal saline was performed. Then the bony defect was filled with synthetic bone graft (Osseograft®, Advanced Biotech products (P) Ltd., Chennai, India– Joint Venture with Encoll Corp., USA) supported by using a bioabsorbable collagen membrane (Healiguide®, Advanced Biotech Products Ltd.) [Figure 4]. Interrupted sutures were performed to readapt the flap. Then the patient was given postoperative instructions, which included administering doxycycline 100 mg (two capsules immediately, then one capsule every day for 14 days) and rinsing with 0.12% solution of chlorhexidine twice a day for 5 weeks. The patient was recalled after 10 days for suture removal.

RESULTS

Open flap debridement combined with odontoplasty and bone grafting with bioabsorbable collagen membrane successfully treated periodontic-endodontic lesion with a deep PRG. Healing of the tissues was uneventful. The patient was recalled at 1 month, 3 months, 6 months, and 12 months interval. The periodontal tissues appeared healthy and neither inflammatory signs nor symptoms were observed [Figure 5]. At 1 and 3 months reduction of inflammatory signs of surrounding gingiva was observed. In radiographic examination, it was seen that graft material wasn't mineralized completely [Figure 6]. Probing depths were not measured as it was early for probing the depth of periodontal pocket treated with regenerative procedure. At 6 months and 12 months interval probing depth of 2, 3, and 4 mm was recorded, which shows gains in clinical attachment levels at the distopalatal, midpalatal, and mesiopalatal aspects of the tooth,

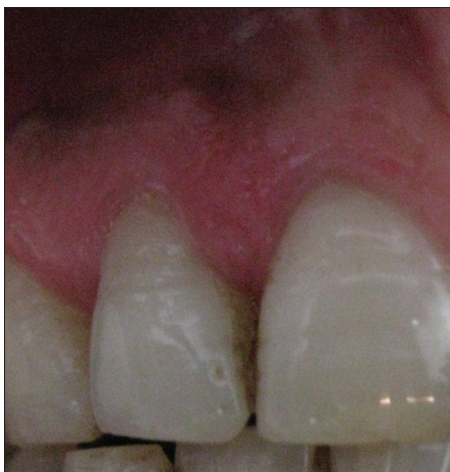

Figure 1: Periodontal condition was unremarkable at the labial aspect of the tooth

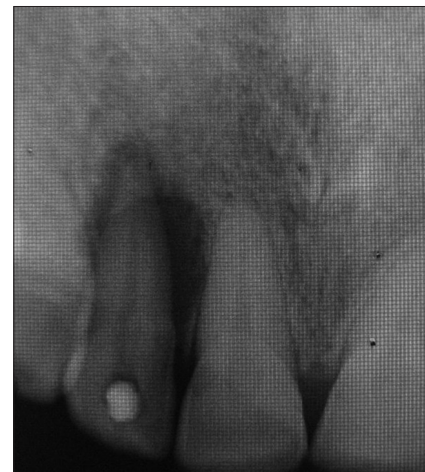

Figure 2: Intraoral periapical radiograph revealed a large periapical lesion with a bony defect extending beyond the apical third of the root

respectively. Radiographic examination revealed an increase in trabecular bone density and a reduction of periapical infection. At the last of 12 month, there was

no inflammation at the labial and palatal aspects of the tooth [Figure 7] and no bone resorption was detected on radiographic examination [Figure 8].

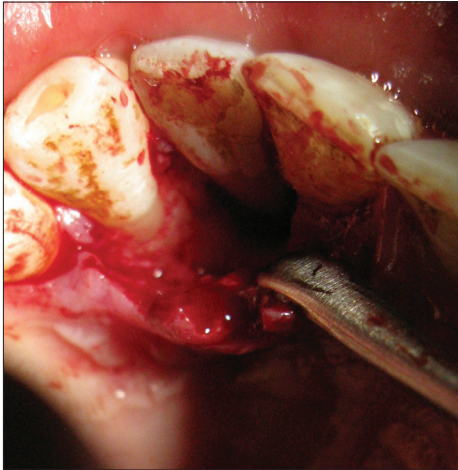


Figure 3: Root planning was performed and odontoplasty was carried out for the elimination of the PRG

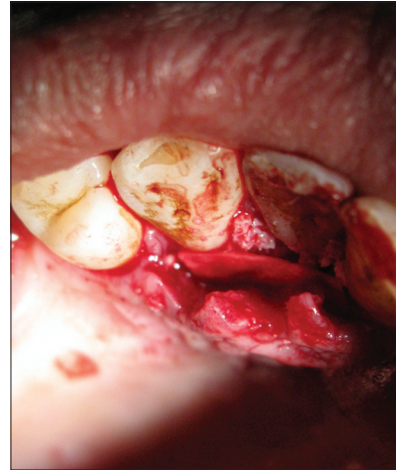


Figure 4: The defect was filled with synthetic bone graft supported by using a bioabsorbable collagen membrane

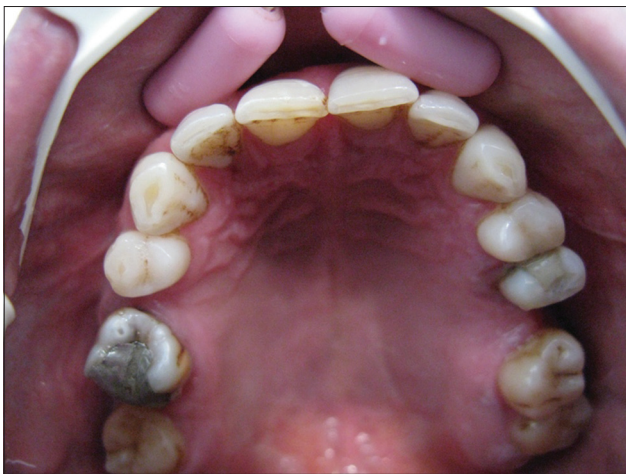

Figure 5: Periodontal tissues appeared healthy and no inflammatory signs were observed at 3 months

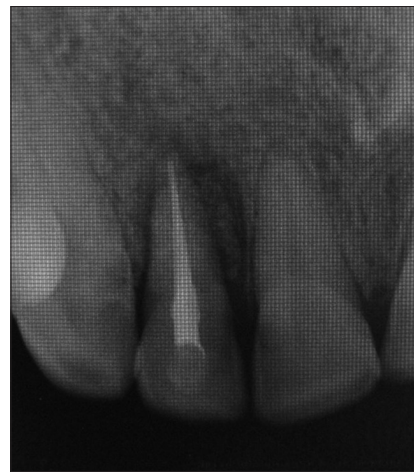

Figure 6: In radiographic examination, it was seen that graft material wasn't mineralized completely at 3 months

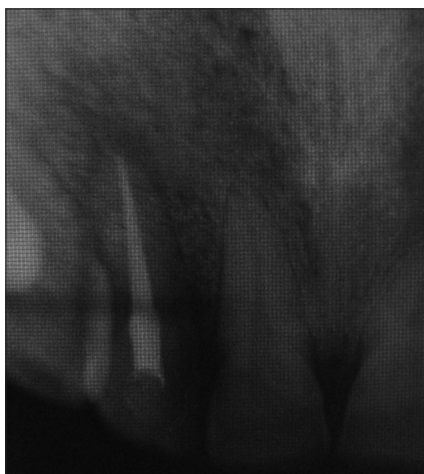


Figure 7: No bone resorption was detected on radiographic examination at 12 months

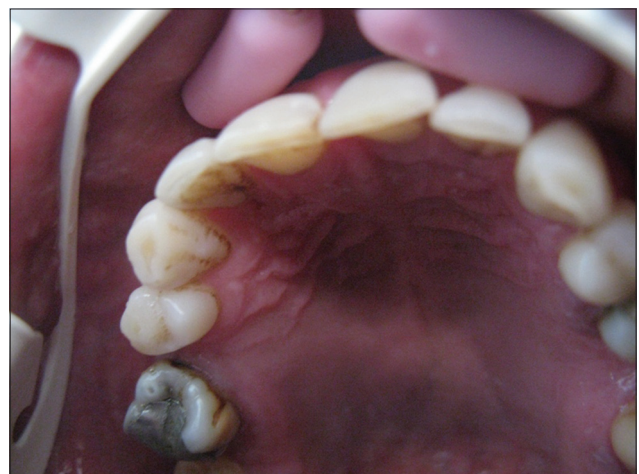

Figure 8: There was no inflammation at the labial and palatal aspects of the tooth at 12 months

DISCUSSION

Palato-radicular groove is a common tooth anomaly which is first described in 1958, as a radicular invagination of an upper lateral incisor in a Chinese female.^[6] The reported prevalence of PRG varies from 2.3% to 5.6%, and the maxillary lateral incisors are the most frequently affected teeth.^[7] PRGs occurs suitable areas for plaque accumulation, often associated with localized periodontitis and a pulpal necrosis. Depending on these grooves, focal loss of periodontal attachment could result in a hopeless prognosis for tooth retention. However, the groove can lead to combined endodontic periodontic lesions that are among the most important diagnostic and therapeutic challenges faced by periodontist. The best way for the successful treatment of PRG is to eliminate the groove for the eradication of inflammatory irritants completely. There are different types of treatment like scaling and root planing, odontoplasty, amalgam restoration, and extraction of the tooth to treat palatogingival groove and associated periodontal bone defects.^[3] However, the regeneration of the lost periodontal tissues may not be available with these treatment choices. The most suitable approach should be aimed to not only eliminate the radicular portion of the groove but regenerate the periodontal attachment and bone loss as well.

In this present case, the GTR technique was used which consist of using synthetic graft material and bioabsorbable collagen membrane. In a case series study, PRGs treated using GTR with significant were resulted with reduction in probing depth (5.0 ± 0.8 mm) and gain in attachment level (5.3 ± 0.9 mm).^[4] A case was reported that tooth #7 was successfully treated by radiculoplasty, bone graft and placement of a nonabsorbable membrane.^[8]

In the present case, for the regenerative procedure, the defect was filled with demineralized, freeze-dried bone graft and covered with resorbable membrane as there was less possibility of containing the blood coagulum during the healing period.^[9] Apart from the fact that there is no need for a second surgical intervention for removal of the membrane, it's reported that bioabsorbable membranes present improved soft-tissue healing.^[5] Due to these advantages we used a resorbable collagen membrane

that have the ability to prevent the apical migration of epithelium along the root surface during periodontal wound healing.^[10] A bone graft was used to fill the defect under the membrane to reduce the dead space for tissue ingrowths, it also prevents the overlying membrane from possible collapse.^[5] After a successful endodontic treatment and initial periodontal therapy; bone graft and bioabsorbable membrane for GTR to treat this bony defect resulted in a significant improvement in the clinical parameters, with bone filling the defect after 12 months.

REFERENCES

1. Ennes JP, Lara VS. Comparative morphological analysis of the root developmental groove with the palato-gingival groove. *Oral Dis* 2004;10:378-82.
2. Goon WW, Carpenter WM, Brace NM, Ahlfeld RJ. Complex facial radicular groove in a maxillary lateral incisor. *J Endod* 1991;17:244-8.
3. Anderegg CR, Metzler DG. Treatment of the palato-gingival groove with guided tissue regeneration. Report of 10 cases. *J Periodontol* 1993;64:72-4.
4. Nyman S, Gottlow J, Karring T, Lindhe J. The regenerative potential of the periodontal ligament. An experimental study in the monkey. *J Clin Periodontol* 1982;9:257-65.
5. Lekovic V, Camargo PM, Klokkevold PR, Weinlaender M, Kenney EB, Dimitrijevic B, *et al.* Preservation of alveolar bone in extraction sockets using bioabsorbable membranes. *J Periodontol* 1998;69:1044-9.
6. Lee KW, Lee EC, Poon KY. Palato-gingival grooves in maxillary incisors. A possible predisposing factor to localised periodontal disease. *Br Dent J* 1968;124:14-8.
7. Archana PM, Salman AA, Panishankar KH, Kumar TS, Saraswathi PK. Palato radicular groove. *SRM Univ J Dent Sci* 2011;2:139-45.
8. Jeng JH, Lu HK, Hou LT. Treatment of an osseous lesion associated with a severe palato-radicular groove: A case report. *J Periodontol* 1992;63:708-12.
9. Gadagi JS, Elavarasu S, Ananda D, Murugan T. Successful treatment of osseous lesion associated with palatoradicular groove using local drug delivery and guided tissue regeneration: A report of two cases. *J Pharm Bioallied Sci* 2012;4:S157-60.
10. Polimeni G, Xiropaidis AV, Wikesjö UM. Biology and principles of periodontal wound healing/regeneration. *Periodontol* 2000 2006;41:30-47.

How to cite this article: Kamak G, Akman S. Combined treatment of a lateral incisor with palato-radicular groove: 1 year follow-up. *Eur J Gen Dent* 2014;3:163-6.

Source of Support: Nil, **Conflict of Interest:** None declared.