

An appraisal of congenital maxillary double lip with a case report

Preeti Sethi Bakshi, Naveen Jindal¹, Alka Kaushik², Swati Leekha³

Department of Periodontics, ¹Yamuna Institute of Dental Sciences and Research, Yamuna Nagar, ²Oral Surgeon, Government Dental College, Rohtak, ³Department of Oral and Maxillofacial Pathology, SDDHDC, Barwala, Haryana, India

Address for correspondence:

Dr. Preeti Sethi Bakshi,
Department of Oral and Maxillofacial
Pathology, Yamuna Institute of
Dental Sciences and Research,
Yamuna Nagar, Haryana, India.
E-mail: preetisethibakshi@gmail.com

ABSTRACT

Double lip is a rare anomaly that may be congenital or acquired and affects upper lip more commonly than the lower lip. This deformity consists of an accessory fold of redundant mucous membrane inside the vermilion border. It affects esthetics and may also interfere with speech and mastication. Simple surgical excision produces good functional and cosmetic results. We describe a case of congenital maxillary double lip along with a brief review of the literature and discuss the differential diagnosis. This anomaly is of more relevance in dentistry as a general dental practitioner is usually the first professional to recognize and establish the diagnosis.

Key words

Ascher's syndrome, double lip, maxillary

INTRODUCTION

Double lip is a rare anomaly characterized by accessory fold of redundant mucous membrane, which is situated proximal to vermilion border and becomes more prominent on smiling. It may be congenital or acquired. This condition affects upper lip more frequently than the lower lip and has no racial predilection.^[1-4] There appears to be male gender predilection of 7:1 for this anomaly.^[5] It may occur in isolation or as part of Ascher's syndrome.^[2,6,7] Treatment is accomplished surgically and is usually indicated for cosmetic and esthetic reasons or for functional impairment if it interferes with speech and mastication. Recurrences after surgery are extremely rare.^[6]

CASE REPORT

A 32-year-old male reported to the outpatient department with the chief complaint of large and unsightly upper lip because of which patient felt embarrassed to smile and wanted to get it corrected. Although the anomaly was present since birth, he got conscious about this at the age of 18-20 years. There was no previous history

of trauma, infection or surgery on lip. His family and medical history were noncontributory.

Clinical examination revealed extra fold of tissue bilaterally with midline constriction band on the inner aspect of upper lip. The anomaly was clearly visible when patient kept the lips apart [Figure 1] and became more prominent, while smiling [Figure 2]. The overlying mucosal tissue appeared intact and smooth with no palpable masses or surface changes. This general blood picture was within normal limits. There were no associated congenital abnormalities such as blepharochalasis and thyroid enlargement as seen in Ascher's syndrome. A provisional diagnosis of congenital bilateral maxillary double lip was made, and surgical excision was planned under local anesthesia. Bilateral infraorbital blocks were administered. The accessory labial tissue was marked and excised by transverse elliptical incision from one commissure to another. The primary closure of the wound was carried out using 4-0 silk suture and a light pressure dressing were placed over upper lip for initial 24 h. The patient was reviewed after 1-week for suture removal [Figure 3] and after 3 months. No postoperative problem was there, and highly satisfactory aesthetic results achieved [Figures 4 and 5].

Histopathology of the specimen showed normal labial mucosa with acanthosis. The connective tissue revealed minor mucosal glands and bands of skeletal muscles [Figure 6].

Patient was followed-up for 2 years, and no surgical complications or recurrences were observed.

Access this article online

Quick Response Code:



Website:
www.ejgd.org

DOI:
10.4103/2278-9626.141670

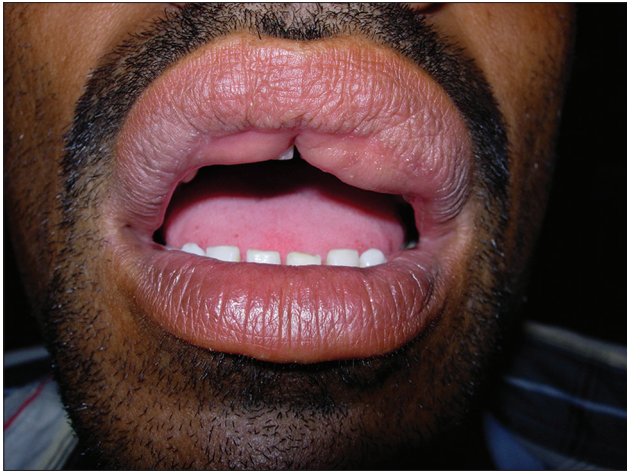

Figure 1: Clinical photograph of maxillary double lip

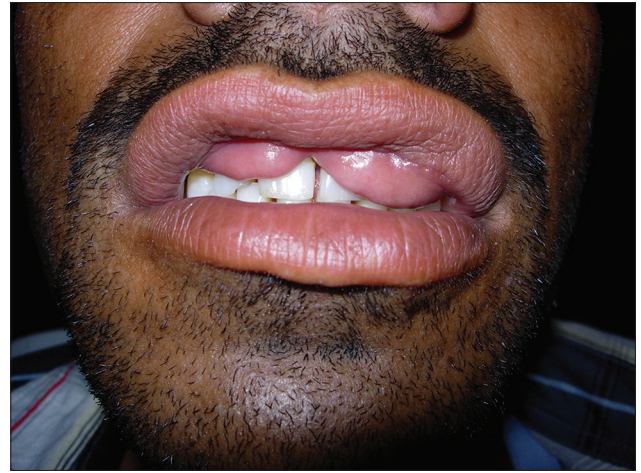

Figure 2: Anomaly became more prominent on smiling

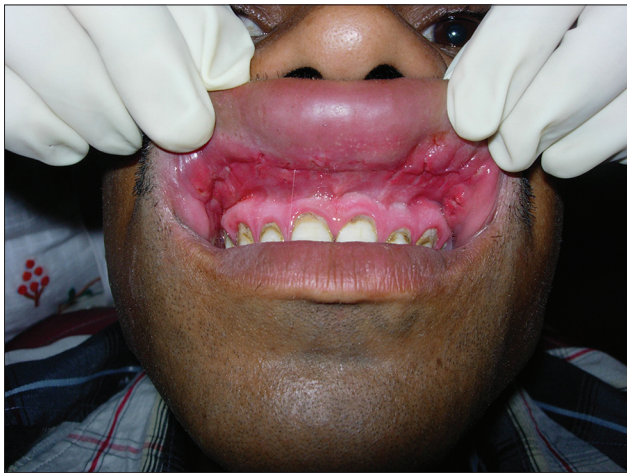

Figure 3: 1-week postoperative clinical photograph

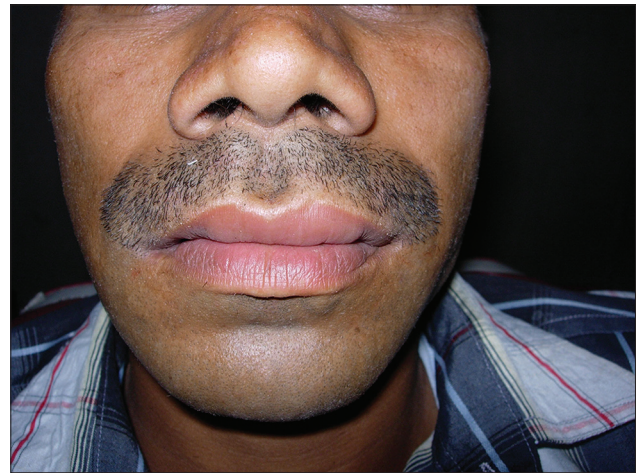

Figure 4: Postoperative photograph showing marked aesthetic improvement

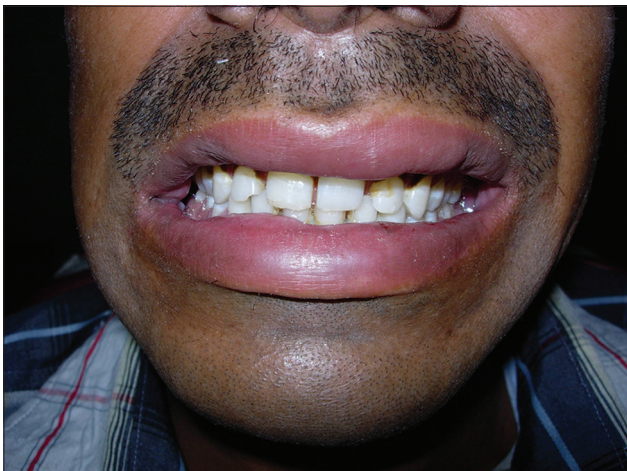

Figure 5: No anomaly visible even on smiling after surgery

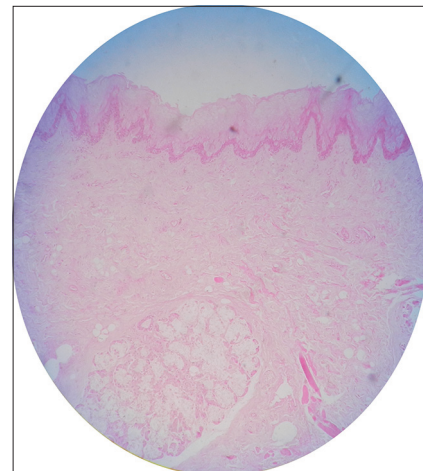


Figure 6: Histopathology showing acanthosis in epithelium, minor mucus glands and skeletal muscles in connective tissue

DISCUSSION

Double lip is one of the rarest form of lip anomalies.^[7] It is also referred to as macrocheilitis.^[4] It usually occurs as

a fold of hypertrophic tissue on the mucosal side of the lip. It occurs most often bilaterally on upper lip, but may be unilateral and can affect both upper and lower lip.^[8]

Males are affected more commonly with this anomaly in the ratio of 7:1.^[5] The condition can be congenital or acquired. The congenital form is more common and is a hypothesis to arise during second or 3rd month of gestation. It is during the development of the mucosa that the upper lip consists of two transverse zones that is, the outer zone, which is smooth and similar to the skin called par glabrosa and the inner zone, which is villosa and similar to the oral mucosa termed pars villosa.^[9] The persistence of horizontal sulcus between pars glabrosa and pars villosa leads to the formation of double lip.^[6,10]

The acquired form of double lip may be secondary to trauma and oral habits and may develop in association with Ascher's syndrome.^[8,11] The acquired form could be due to "sucking in" of the tissues between the teeth or maloccluding dentures^[12] or due to lip sucking habits.^[13] Ascher syndrome consists of the triad of blepharochalasis, nontoxic thyroid enlargement and double lip. Ascher first noticed the association of double lip and blepharochalasis with thyroid enlargement.^[8,9,14]

Double lip can also occur in association with other oral anomalies such as bifid uvula,^[9] hemangiomas,^[12] cleft palate^[14] and cheilitis glandularis.^[12,13,15]

Differential diagnosis of double lip includes hemangioma, lymphangioma, angiodema, cheilitis glandularis, cheilitis granulomatosa mucus retention cyst, mucocele, salivary gland tumors, plasma cell cheilitis and inflammatory fibrous hyperplasia.^[1,2,12,15,16] Congenital double lip can be differentiated from these conditions due to its "cupid bow" appearance or midline constriction.^[17] The treatment of congenital double lip is indicated for esthetic concern as in our case or when excess tissue interferes with mastication or speech or leads to habits as sucking or biting the redundant tissue.

The treatment includes several surgical techniques like W-plasty,^[17] electrosurgical excision^[18] and triangular excision.^[4] Transverse elliptical excision is used in most cases and gives good results.^[1,9,15] Bilateral infraorbital nerve blocks and mental nerve lock have been advocated by Dingman and Billman^[1] to decrease the chance of tissue distortion when administering local anesthesia. The surgery involves excision of excess mucosa and submucosa without involving underlying muscular layer. Although recurrence is rare, one case has been reported with recurrence.

CONCLUSION

Double lip is a rare oral anomaly, and general dental practitioner is often the first professional to detect and

establish the diagnosis of this uncommon condition.^[2] The dentist should rule out blepharochalasis and nontoxic thyroid enlargement which are seen in Ascher's syndrome that also includes the occurrence of double lip.^[11] Because of the progressive nature or suspected Ascher's syndrome the patient should be advised follow-up for a long time.^[19]

REFERENCES

1. Kenny KF, Hreha JP, Dent CD. Bilateral redundant mucosal tissue of the upper lip. *J Am Dent Assoc* 1990;120:193-4.
2. Martins WD, Westphalen FH, Sandrin R, Campagnoli E. Congenital maxillary double lip: Review of the literature and report of a case. *J Can Dent Assoc* 2004;70:466-8.
3. Morgan AF, Stewart FW, Stein IJ. Double lip. Report of a case. *Oral Surg Oral Med Oral Pathol* 1960;13:236-9.
4. Lamster IB. Mucosal reduction for correction of a maxillary double lip. Report of a case. *Oral Surg Oral Med Oral Pathol* 1983;55:457-8.
5. Palma MC, Taub DI. Recurrent double lip: Literature review and report of a case. *Oral Surg Oral Med Oral Pathol Oral Radiol Endod* 2009;107:e20-3.
6. Chidzonga MM, Mahomva L. Congenital double lower lip: Report of a case. *Int J Paediatr Dent* 2006;16:448-9.
7. Alkan A, Metin M. Maxillary double lip: Report of two cases. *J Oral Sci* 2001;43:69-72.
8. Barnett ML, Bosshardt LL, Morgan AF. Double lip and double lip with blepharochalasis (Ascher's syndrome). *Oral Surg Oral Med Oral Pathol* 1972;34:727-33.
9. Kara IG, Kara CO. Ascher syndrome. *Otolaryngol Head Neck Surg* 2001;124:236-7.
10. Hanemann JA, Oliveira DT, Gomes MF, dos Anjos MJ, Sant'ana E. Congenital double lip associated to hemangiomas: Report of a case. *Med Oral* 2004;9:156-8, 155.
11. Gorlin RJ, Pinolborg JJ, Lohen MM. *Syndromes of Head and Neck*. 2nd ed. New York: McGraw Hill; 1964. p.186-9.
12. Dhanpal R, Nalin Kumar S, Saraswati TR, Uma Devi M, Elizabeth Joshua, Veerabahu M, Ranganathan K. Maxillary double lip and cheilitis glandularis: An unusual occurrence. *J Oral Maxillofac Pathol* 2007;11:35-7.
13. Cohen DM, Green JG, Diekmann SL. Concurrent anomalies: Cheilitis glandularis and double lip. Report of a case. *Oral Surg Oral Med Oral Pathol* 1988;66:397-9.
14. Converse JM. *Reconstructive Plastic Surgery*. Vol. 3. Philadelphia: Saunders; 1977.p.1534-4.
15. Beena R, Rohit. Congenital double lip review of literature and a case report. *Int J Contemp Dent* 2012;3:46-8.
16. Eski M, Nisanci M, Aktas A, Sengezer M. Congenital double lip: Review of 5 cases. *Br J Oral Maxillofac Surg* 2007;45:68-70.
17. Guerrero-Santos J, Altamirano JT. The use of W-plasty for the correction of double lip deformity. *Plast Reconstr Surg* 1967;39:478-81.
18. Peterson A. Electrosurgical correction of maxillary double lip. *Dent Dig* 1972;78:182-8.
19. Daniels JS. Congenital double upper lip: A case report and review of the literature. *Saudi Dent J* 2010;22:101-6.

How to cite this article: Bakshi PS, Jindal N, Kaushik A, Leekha S. An appraisal of congenital maxillary double lip with a case report. *Eur J Gen Dent* 2014;3:199-201.

Source of Support: Nil, **Conflict of Interest:** None declared.