

Clinical dilemma: Misdiagnosed...

Sir,

After reading an interesting article published in your journal by Pereira *et al.*,^[1] we would like to share with you and readers of European Journal of General Dentistry, our experience of a 42-year-old male patient, who was clinically misdiagnosed with giant calculus. He gave history of road traffic accident, 12 years back causing trauma to the upper left posterior region resulting in loosening of teeth. He had consulted the local dentist for his mobile teeth 5 years back, which were extracted. Since then he had difficulty in eating food from the same area. He was a known case of pemphigus vulgaris and was under treatment. He gave a history of tobacco chewing in the raw form with lime, since 10 years. He had visited the dental college due to pain in left posterior region. The pain aggravates during verbal communication and mastication. His oral hygiene was poor, with generalized stains and multiple carious teeth. Intra-oral examination revealed edentulous left maxillary arch. An erythematous lesion of approximately 1.5 cm × 1 cm in diameter was appreciated in left buccal mucosa in relation to 27, 28 region [Figure 1a and b]. A brownish mass of varying shades with indentations of teeth mark was observed in relation to 21-27, having a porous appearance, which was hard in consistency [Figure 1a]. The mass was mobile and appeared to be attached on the anterior side with an orthodontic wire and posteriorly appeared to be attached to the alveolus. Orthopantomograph revealed a radiodense mass in relation to 21-27 [Figure 1c]. Clinically, it was diagnosed as giant calculus and the erythematous lesion was considered to be an inflamed area caused by the giant calculus. The bony hard mass was removed with surgical invention and was sent for histopathological evaluation [Figure 1d]. Microscopically, the Hematoxylin and Eosin stained sections showed necrotic osseous tissue with the absence of marrow components (blood vessels etc.) and empty lacunas with the absence of osteocytes and were suggestive of necrotic bone.

Literature search revealed brownish lesions which are hard in consistency in relation to tooth-bearing areas have been previously misdiagnosed, and or can mimic as neoplastic lesions.^[1-4] Giant dental calculus could be associated with systemic conditions like poorly controlled type 2 diabetes.^[2-4] On clino-pathological correlation considering history of road traffic accident, it was concluded that formation of this detached necrosed bone resulted due to the trauma, causing horizontal fracture of maxillary alveolus which has gradually over a period of 10 years sequestered out. To best of our knowledge, no such case has been reported in the English language literature. Such type of pathology requires histopathological support or otherwise can lead to misdiagnosis. There is diminutive awareness about

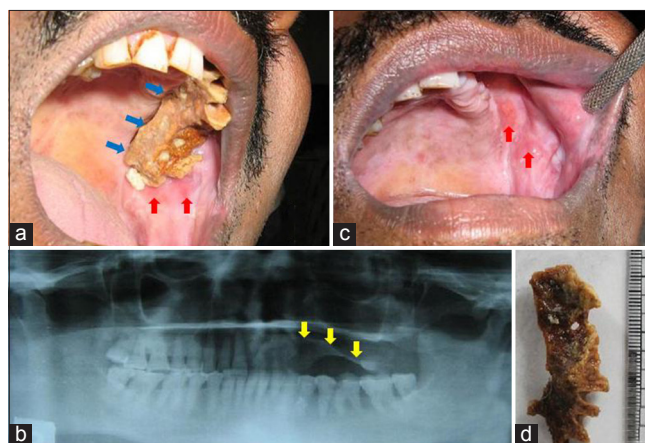


Figure 1: (a) preoperative clinical photograph; brownish mass with indentations (blue arrows) and erythematous lesions (red arrows), (b) postoperative clinical photograph; erythematous lesions (red arrows), (c) radiodense lesion in orthopantomograph (yellow arrows), (d) gross specimen with indentations

oral hygiene in people living in rural India, and there is a need to implement, establish, and monitor oral rural health programs.

Kunal Sah, Alka D. Kale¹, Seema Hallikerimath², Sunira Chandra²

Departments of Oral Pathology and Microbiology and ²Oral Medicine and Radiology, Saraswati Dental College and Hospital, Lucknow, Uttar Pradesh, ²Department of Oral Pathology and Microbiology, KLE VK Institute of Dental Sciences, KLE University, Belgaum, Karnataka, India

Address for correspondence:

Dr. Kunal Sah,
Department of Oral Pathology and Microbiology,
Saraswati Dental College and Hospital, 233,
Tiwari Ganj, Faizabad Road, Lucknow, Uttar Pradesh, India.
E-mail: steps_32kunal@hotmail.com

REFERENCES

1. Pereira T, Shetty S, Pereira S. Giant calculus. *Eur J Gen Dent* 2014;3:174.
2. Ortega KL, Luiz AC, Martins FM. Calculus or tumour? *Br Dent J* 2008;205:582.
3. Wegenast S, Laugharne DA. Giant calculus. *Br Dent J* 2013;214:93.
4. Woodmansey K, Severine A, Lembariti BS. Giant calculus: Review and report of a case. *Gen Dent* 2013;61:e14-6.

Access this article online

Quick Response Code:



Website:
www.ejgd.org

DOI:
10.4103/2278-9626.141673