

Fluoroscopic-guided lumbar puncture in severe kyphoscoliosis: An alternative option in a difficult scenario

Rohini Gondhule, Soumya Madhusudan, Kamath Sriganesh

Sir,

Occasionally physicians encounter difficulty in performing successful lumbar puncture (LP) especially in paediatric patients and in those with anatomical abnormalities. Use of image guidance facilitates this procedure with minimal patient discomfort and also avoids undue delay in treatment initiation from inability to arrive at a definitive diagnosis from cerebrospinal fluid (CSF) analysis.

An 11-year-old boy clinically diagnosed as McCune -Albright syndrome based on the presence of cafe-au-lait spot; hyper-pigmented patch extending from the abdomen to whole of the back [Figure 1] and polyostotic fibrous dysplasia; he had bony expansion of bilateral lower ends of the tibia, and dorso-lumbar kyphoscoliosis. He presented with behavioural abnormality and myoclonic jerks involving upper and lower limbs of 6 months duration. He had

measles at the age of 4 years. Diagnostic LP was planned to analyse the CSF and informed consent was obtained for the same. Several attempts in sitting and lateral decubitus position, both in midline and paramedian approach with local infiltration of 2% lignocaine, to obtain the CSF at bedside by neurology and anaesthesiology residents of graded seniority and a neurology consultant were unsuccessful. As the anaesthesia consultant was not experienced in ultrasound-guided regional anaesthesia procedures but experienced in fluoroscopy-guided pain intervention procedures, a fluoroscopic-guided LP was planned. LP was successfully performed with 2 cc of 2% lignocaine infiltration at L₅-S₁ level in the left lateral decubitus position with paramedian approach on second attempt using a 25G Quincke spinal needle without any sedation as patient co-operated in the presence of his father. In the earlier failed attempt, needle met resistance at the vertebral body as it was rotated due to the bony abnormality. Fluoroscopic guidance facilitated accurate localisation of spinous processes and assisted in assessing correct depth and direction of the needle placement in this patient [Figure 2]. Fluoroscopy was used only three times during the procedure to limit the exposure to radiation.

Fluoroscopy-guided LP is performed in anticipated difficult LP or following failed LP.^[1] Fluoroscopy provides a real-time view of the spine, which facilitates identification of the spinal anatomy and aids in manoeuvring and positioning of the spinal needle. This helps in reducing the complications associated

Department of Neuroanesthesia, National Institute of Mental Health and Neurosciences, Bangalore, Karnataka, India

Address for correspondence:

Dr. Kamath Sriganesh, Department of Neuroanaesthesia, National Institute of Mental Health and Neurosciences, Bangalore - 560 029, Karnataka, India. E-mail: drsri23@rediffmail.com

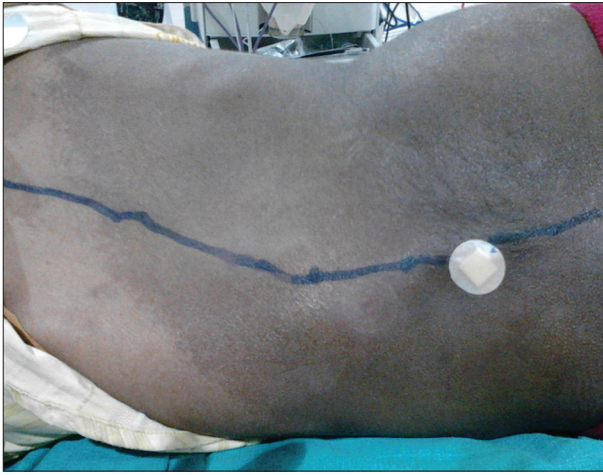


Figure 1: The “Coast of Maine” Cafe-au-lait spot and kyphoscoliosis

with the repeated blind LP attempts like patient discomfort and traumatic tap. A previous report by Eskey *et al.*, comparing fluoroscopic -guided LP in 723 patients with blind LP in 1489 patients, demonstrated significant reduction in the incidence of traumatic LP when fluoroscopy was used as compared with blind procedure (3.5% vs 10.1%, respectively).^[2] Traumatic LP also reduces the chance of a conclusive diagnosis, which is vital to initiate appropriate definitive therapy.^[3] The CSF analysis revealed elevated CSF IgG levels and elevation of anti-measles antibodies on ELISA in our patient. This along with electroencephalographic findings of sharp waves in the fronto-parietal regions with intermittent frontal slowing helped in making the final diagnosis of subacute sclerosing pan-encephalitis. Recent application of ultrasonography for performing LP and spinal anaesthesia has increased the success rates in difficult paediatric LP.^[4] Ultrasonography-guided LP may not, however, be always possible for anaesthesiologist because of non-availability or inexperience. Fluoroscopic-guided LP offers a viable alternative in such patients.

To conclude, this report emphasises the need for considering fluoroscopic-guided LP technique in anticipated difficult LP especially when severe bony abnormalities exist and a diagnosis based on LP derived CSF analysis is crucial to arrive at a diagnosis for effective treatment. This will avoid repeated blind attempts,

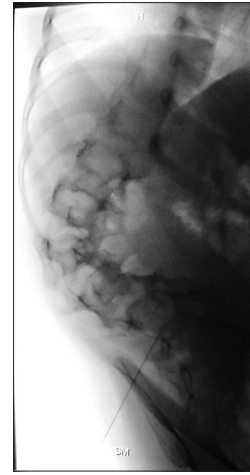


Figure 2: Lateral fluoroscopic view demonstrating kyphoscoliosis of dorso-lumbar spine and direction and depth of the spinal needle where cerebrospinal fluid was obtained for analysis

preventable patient discomfort and non-co-operation, increased risk of complications, delayed diagnosis and need for repeat LPs in event of traumatic tap.

REFERENCES

1. Fluoroscopic guided lumbar puncture. In: Jeffery DH, Michael D. *Fundamentals of Fluoroscopy*. Philadelphia: W.B. Saunders; 2001. p. 149-52.
2. Eskey CJ, Ogilvy CS. Fluoroscopy-guided lumbar puncture: Decreased frequency of traumatic tap and implications for the assessment of CT-negative acute subarachnoid hemorrhage. *Am J Neuroradiol* 2001;22:571-6.
3. Howard SC, Gajjar AJ, Cheng C, Kritchevsky SB, Somes GW, Harrison PL, *et al.* Risk factors for traumatic and blood lumbar puncture in children with acute lymphoblastic leukaemia. *JAMA* 2002;288:2001-7.
4. Warhadpande S, Martin D, Bhalla T, Rehman S, Rose M, Guinipero T, *et al.* Use of ultrasound to facilitate difficult lumbar puncture in the pediatric oncology population. *Int J Clin Exp Med* 2013;6:149-52.

Access this article online	
Quick Response Code:	Website: www.jnaccjournal.org
	DOI: 10.4103/2348-0548.124859