

# A Hybrid Approach to Right-sided Aortic Arch Aneurysm Using Bilateral Carotid to Subclavian Bypass with a Customized Fenestrated Thoracic Endovascular Aortic Repair Device

## Abstract

We present a hybrid approach to the management of an aortic aneurysm in a right-sided aortic arch with aberrant left subclavian artery and associated Kommerell's diverticulum. The aneurysm extended from the origin of the left common carotid artery to the mid-descending thoracic aorta. A bilateral carotid to subclavian artery bypass was performed followed by endovascular placement of a customized fenestrated thoracic endovascular aortic repair device (TEVAR, Cook Medical, Australia). Endovascular stents (Viabahn, Gore Medical, Arizona) were placed in the carotid arteries bilaterally and Amplatzer II plugs (AGA Medical Corporation) were used to occlude the subclavian arteries. Follow-up imaging at 1 month revealed no evidence of endoleak.

**Keywords:** Customized thoracic endovascular aortic repair, hybrid approach, right-sided aortic aneurysm

## Introduction

A right-sided aortic arch results from abnormal embryonic development. It is present in 0.04% to 0.1% of the population, and 50% are associated with an aberrant left subclavian artery (LSA).<sup>[1]</sup> In these cases, the origin of the aberrant LSA can have a misshapen bulbous configuration, known as a Kommerell's diverticulum (KD). The malformed nature makes it susceptible to aneurysm and dissection. Elective repair is preferred due to high postrupture mortality rate of >50%.<sup>[2,3]</sup> We report a hybrid case using preprocedural bypass followed by insertion of a customized fenestrated thoracic endovascular aortic repair (TEVAR) device for the management of both aortic arch and descending thoracic aorta aneurysm associated with a KD.

## Case Report

A 60-year-old male with a background of coronary artery disease, muscular dystrophy, and rheumatoid arthritis presented with dysphagia and shortness of breath on exertion. Computer tomographic angiography (CTA) revealed a right-sided aortic arch with aberrant LSA and an associated KD [Figure 1]. The KD was aneurysmal and increased in size from

6.2 cm to 6.7 cm over 12 months. The aneurysmal portion extended from the distal aspect of the origin of the left common carotid artery to the mid-descending thoracic aorta.

The patient underwent an elective hybrid procedure. First, a bilateral carotid to subclavian artery bypass was performed. The second (endovascular) stage was performed under general anesthesia with orotracheal intubation and required bilateral femoral, bilateral carotid, and right subclavian cutdowns. Bilateral femoral sheaths were placed and a 5-French pigtail catheter was inserted directly into the right subclavian artery (RSA) via the cutdown [Figure 2]. Access was also gained through the right femoral vein into the right ventricle to allow for rapid ventricular pacing.

The customized fenestrated thoracic device was produced in accordance with the patient's individual measurements (Cook Medical, Australia). It matched the unique size of the patient's aortic arch and contained two fenestrations, one for each common carotid artery. It was inserted via the right femoral artery into the ascending aorta. An aortogram was performed to confirm that the proximal end of the stent graft was not encroaching on the coronary

**Victoria A. Burrows,  
Siuchan Sookhoo**

Department of Radiology,  
St. Boniface Hospital, Winnipeg,  
Manitoba, Canada

### Address for correspondence:

Dr. Victoria A. Burrows,  
Department of Radiology,  
St. Boniface Hospital,  
Winnipeg, Manitoba, Canada.  
E-mail: vicky\_burrows85@  
hotmail.com

### Access this article online

Website: [www.arabjir.com](http://www.arabjir.com)

DOI: 10.4103/AJIR.AJIR\_21\_17

### Quick Response Code:



**How to cite this article:** Burrows VA, Sookhoo S. A hybrid approach to right-sided aortic arch aneurysm using bilateral carotid to subclavian bypass with a customized fenestrated thoracic endovascular aortic repair device. Arab J Intervent Radiol 2018;2:26-8.

This is an open access article distributed under the terms of the Creative Commons Attribution-NonCommercial-ShareAlike 3.0 License, which allows others to remix, tweak, and build upon the work non-commercially, as long as the author is credited and the new creations are licensed under the identical terms.

For reprints contact: [reprints@medknow.com](mailto:reprints@medknow.com)

arteries. Bilateral access via the common carotids was then gained using the Seldinger technique. 10-French sheaths were placed bilaterally. Guide catheters were inserted to the level of the aortic arch ostia. The position of the custom device was confirmed and deployed under fluoroscopic guidance with rapid ventricular pacing.

Viabahn delivery system catheters (Gore Medical, Arizona) were used to cannulate the branches of the customized stent graft via the carotid artery sheaths. A 9 mm × 10 cm Viabahn-covered stent graft was placed on the left and a 9 mm × 5 cm Viabahn-covered stent graft was placed on the right.

The distal thoracic component (TX2, Cook Medical, Denmark) was placed via the left femoral artery access and deployed under fluoroscopic guidance [Figure 3]. Amplatzer II plugs (AGA Medical Corporation) were used to occlude

the subclavian arteries bilaterally. An 8-mm Amplatzer II was used on the right and a 16-mm plug on the left [Figure 4].

Completion aortography revealed no endoleak. The sheaths were removed with no vascular injury. The femoral arteries and wounds were closed. The stent coverage extended from the sinotubular junction to the mid-descending thoracic aorta.

There were no immediate complications, and the patient was transferred to the Intensive Care Unit. On extubation, the patient was weak secondary to the muscular dystrophy but otherwise neurologically intact.

Follow-up CTA at 1 week and 1 month revealed no endoleak [Figure 5]. No further follow-up imaging was obtained as the patient, aged 61 years, passed away 9 months after the procedure.

### Discussion

Pathological studies suggest that the most common anatomical variant seen with a right-sided aortic arch is

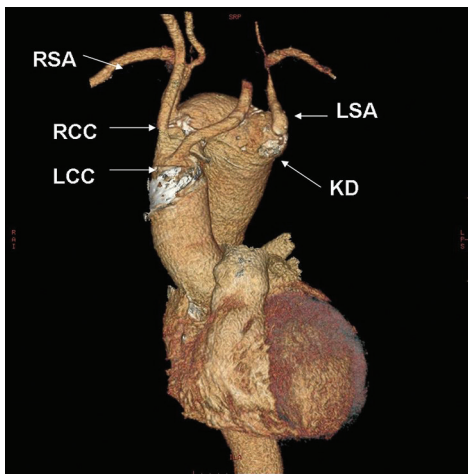


Figure 1: Preoperative three-dimensional reconstruction from computer tomography demonstrating the arterial branching pattern from proximal to distal as follows: Left common carotid, right common carotid, right subclavian artery, and aberrant left subclavian artery with associated Kommerell's diverticulum

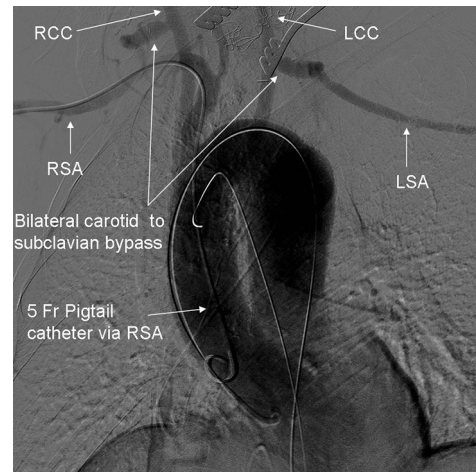


Figure 2: Angiography demonstrates bilateral carotid to subclavian bypass, pigtail catheter *in situ*, and endovascular preparation in the aortic arch for fenestrated thoracic endovascular aortic repair placement

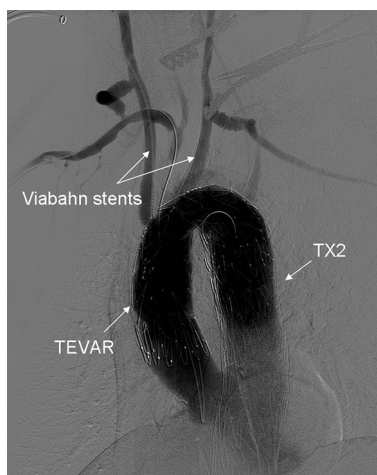


Figure 3: Angiography demonstrates the customized fenestrated thoracic endovascular aortic repair device within the aortic arch, the Viabahn stents in the carotid arteries bilaterally, and the TX2 thoracic stent component in the descending aorta

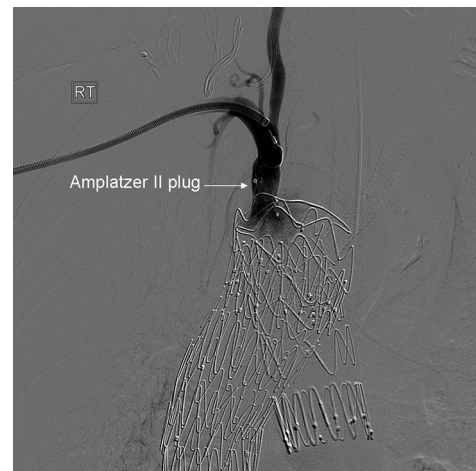
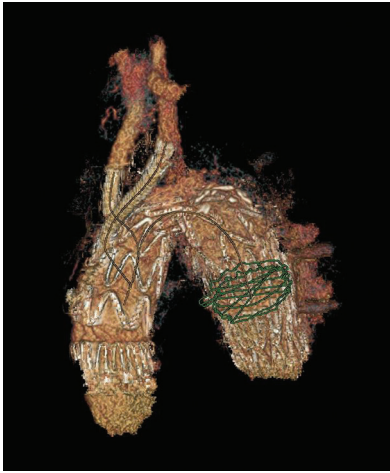


Figure 4: Angiography demonstrates placement of an Amplatzer II plug in the right subclavian artery



**Figure 5: Three-dimensional reconstruction from computer tomography performed postprocedure, demonstrating stent grafts *in situ*, occlusion of the native subclavian arteries bilaterally, and no evidence of endoleak**

mirror image anatomy, which is present in 85% of cases. The first branch is the left brachiocephalic artery followed by the right common carotid and the RSA. The remaining 15% of cases have an aberrant LSA.<sup>[4]</sup> However, in 2016, Barr *et al.* observed the reverse pattern. Of 99 cases, 89% had an aberrant LSA and 11% had mirror image anatomy. As this study focused on the management of pathology, it appears that an aberrant LSA increases the risk of aneurysm and dissection due to the presence of KD and its associated wall weakness. Twenty of the 99 cases underwent a hybrid procedure, and only eight of these had a bypass procedure of the arch vessels followed by a TEVAR.<sup>[5]</sup> There are little data available regarding the optimal time for intervention. Size criteria do not exist and rupture has occurred in an aneurysm as small as 2 cm.<sup>[6]</sup>

This case's aneurysm was extensive and had both arch and distal thoracic aorta involvement. Previously, an aneurysm with this degree of arch involvement would require surgical arch replacement via a median sternotomy or a thoracotomy with or without partial heart bypass.

The customized device used in this case was designed to allow full coverage of the aneurysmal portion of the aorta and provide fenestrations for access to the common carotids for additional stent placement. The advantage of

this technique was that the aneurysm could be treated with an endovascular approach, avoiding the need for open surgery while also maintaining patency of the arch vessels. This approach was particularly useful in this case as the patient was a poor surgical candidate due to comorbidities. However, there are limitations to such a device including high costs and the time required to manufacture. This technique cannot, therefore, be used in emergency situations. It should also be noted that the procedure required significant planning, and as it is high risk, it was carried out in a specialist center.

#### Declaration of patient consent

The authors certify that they have obtained all appropriate patient consent forms. In the form the patient(s) has/have given his/her/their consent for his/her/their images and other clinical information to be reported in the journal. The patients understand that their names and initials will not be published and due efforts will be made to conceal their identity, but anonymity cannot be guaranteed.

#### Financial support and sponsorship

Nil.

#### Conflicts of interest

There are no conflicts of interest.

#### References

1. Wu JY, Chen HY, Shu CC, Yu CJ. Kommerell diverticulum, right-sided aorta, and left aberrant subclavian artery in a patient with dysphagia. *J Thorac Cardiovasc Surg* 2010;139:e97-8.
2. Cruz Ciria S, Guillén Subirán ME, Zaragoza Guillén R, Hilario González J. Hybrid treatment of a symptomatic aneurysm of a Kommerell's diverticulum. *Radiologia* 2013;55:261-4.
3. Ferrero E, Ferri M, Viazzo A, Carbonatto P, Pecchio A, Casabona R, *et al.* Aneurysm of the aberrant right subclavian artery: Surgical and hybrid repair of two cases in a single center. *Ann Vasc Surg* 2011;25:839.e5-9.
4. Knight L, Edwards JE. Right aortic arch. Types and associated cardiac anomalies. *Circulation* 1974;50:1047-51.
5. Barr JG, Sepehrpour AH, Jarral OA, Tsipas P, Kokotsakis J, Kourliouros A, *et al.* A review of the surgical management of right-sided aortic arch aneurysms. *Interact Cardiovasc Thorac Surg* 2016;23:156-62.
6. Cinà CS, Althani H, Pasenau J, Abouzahr L. Kommerell's diverticulum and right-sided aortic arch: A cohort study and review of the literature. *J Vasc Surg* 2004;39:131-9.