

Uneventful Sleeve Gastrectomy Post Bariatric Arterial Embolization

Abstract

We present the case of a 42-year-old female patient who successfully and uneventfully underwent gastric sleeve surgery 3-years after left gastric artery embolization, for the treatment of obesity. This case highlights that left gastric artery embolization may not preclude future bariatric surgeries in this subset of patients who initially fail to lose weight after bariatric arterial embolization (BAE).

Keywords: *Bariatric arterial embolization, bariatric embolization, gastric artery embolization, left gastric artery, obesity, sleeve gastrectomy*

Introduction

Bariatric arterial embolization (BAE) is a minimally invasive, nonsurgical procedure that has been proposed to treat obesity and has yielded promising initial results.^[1,2] Some authors caution that BAE may preclude future sleeve gastrectomy or Roux-en-Y gastric bypass, as the left gastric artery (LGA) is the main artery supplying the remnant sleeve or gastric pouch section, respectively.^[3] The evidence to support or refute this concern remains not investigated in humans. We present a patient who successfully underwent sleeve gastrectomy 3 years after BAE.

Case Report

A 42-year-old obese female with a body mass index (BMI) of 30.5 kg/m² (weight 80 kg, height 162 cm) who failed to reduce her weight by dietary control and was unable to continue exercise because of right knee injury. As a preparation for BAE, the patient had unremarkable upper gastrointestinal (GI) endoscopy, computed tomography (CT) angiography of the abdomen, and general laboratory blood investigations, apart from high total cholesterol (6.4 mmol/L) and low-density lipoproteins cholesterol (4.4 mmol/L) levels. Two weeks before the procedure, she was started on esomeprazole 40 mg orally once daily. She also had dietary consultations for preprocedural evaluation and postprocedure dietary regimen.

This is an open access journal, and articles are distributed under the terms of the Creative Commons Attribution-NonCommercial-ShareAlike 4.0 License, which allows others to remix, tweak, and build upon the work non-commercially, as long as appropriate credit is given and the new creations are licensed under the identical terms.

For reprints contact: WKHLRPMedknow_reprints@wolterskluwer.com

A single dose of preprocedural prophylactic antibiotic (2 g cefazolin) was administered intravenously. The procedure was done under conscious sedation and access was obtained through the right common femoral artery. A celiac angiogram was performed using a 5-F Simmons-1 catheter (Boston Scientific, Marlborough, Massachusetts), which demonstrated normal arterial anatomy with the LGA arising off the celiac trunk. The LGA was further cannulated using a coaxial 3F Renegade Hi-Flo microcatheter (Boston Scientific, Marlborough, Massachusetts). Cone-beam CT was obtained to assess fundal vascularity [Figure 1]. Cocktail of verapamil 2.5 mg, heparin 3000 IU, and nitroglycerin 200 mcg was injected slowly into the LGA before embolization. Embolization of the LGA was achieved using 250–355 Contour polyvinyl alcohol particles (Boston Scientific, Marlborough, Massachusetts) until complete stasis [Figure 2]. No other arteries were embolized.

Intravenous administration of 10 mg metoclopramide was given at the end of the procedure to suppress nausea and vomiting in addition to intramuscular injections of 75 mg meperidine and 50 mg promethazine to control postprocedure pain. The patient was discharged home with the following medications: esomeprazole 40 mg once daily for 4 weeks as a gastroprotective agent, metoclopramide 10 mg orally every 6 h as needed for 2 weeks to suppress nausea or vomiting, and tramadol 50 mg every 8 h as needed for 1 week to control moderate pain.

How to cite this article: Ashour MA, Karsou AS, Bakhsh AA. Uneventful sleeve gastrectomy post bariatric arterial embolization. *Arab J Intervent Radiol* 2020;4:127-9.

**Majed A. Ashour¹,
Ahmed Saliman
Karsou¹,
Adel A. Bakhsh²**

¹King Faisal Specialist Hospital and Research Center, Jeddah, Saudi Arabia, ²Saliman Faqeeh Hospital, Jeddah, Saudi Arabia

Received: 02-06-2020

Revised: 09-06-2020

Accepted: 18-06-2020

Online Published: 21-07-2020

Address for correspondence:

Dr. Majed A. Ashour,
Department of Radiology,
Section of Vascular and
Interventional Radiology, King
Faisal Specialist Hospital
and Research Center, Jeddah,
Saudi Arabia.

E-mail: ashourma@hotmail.com

Access this article online

Website: www.arabjir.com

DOI: 10.4103/AJIR.AJIR_25_20

Quick Response Code:



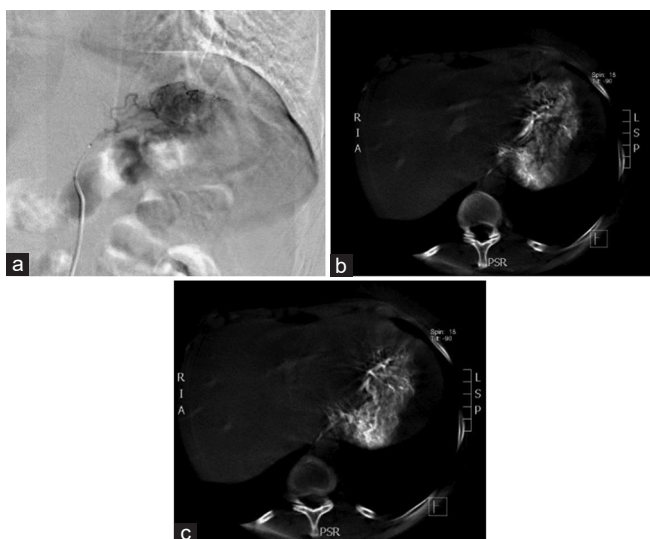


Figure 1: Pre-embolization left gastric artery angiogram (a) and axial cone-beam computed tomography (b and c)

Dietary instructions from the dietician were given as follows: a clear liquid diet the 1st week after the procedure followed by a full liquid diet the next week. Soft, pureed foods are added in the third postprocedural week with a gradual return to a solid diet by week 4.

The patient was followed up at 2 weeks, 1 month, 3 months, and 6 months in the IR and dietician clinics. The patient had complained of epigastric pain, nausea, and vomiting, which was moderate in severity for the 1st postprocedure week and gradually subsided over the 2nd week. These symptoms were well controlled by the prescribed medications. The patient reported subjective loss of appetite for about 1 month and was able to continue the strict diet regimen for a total of 2 months only. She lost 4.2 kg (5.2% weight loss) within a period of 3 months from the procedure reaching a BMI of 28.9 kg/m². The patient, however, did not lose more weight between 3 and 6 months as she was partially compliant with dietary instruction and could not also perform enough exercise because of the recurrent right knee pain.

The patient presented again to IR clinic after 3 years requesting a referral to bariatric surgery. Her weight was 85.1 kg, height 162 cm, and BMI 32.4 kg/m². She has had right knee arthroscopy for degenerated medial meniscus, underwent liposuction of the thighs, and was on antidepressant medications because of obesity. Before planning for the surgery, a CT angiogram was performed to reassess the gastric arteries, which revealed persistent LGA occlusion [Figure 3].

She underwent laparoscopic sleeve gastrectomy, in which transection of the stomach was performed using Echelon articulating stapler (Ethicon, Cincinnati, OH), starting from the antrum 2–3 cm proximal to the pylorus toward the fundus, aligning 36 Fr Gastric Calibration Tube against the

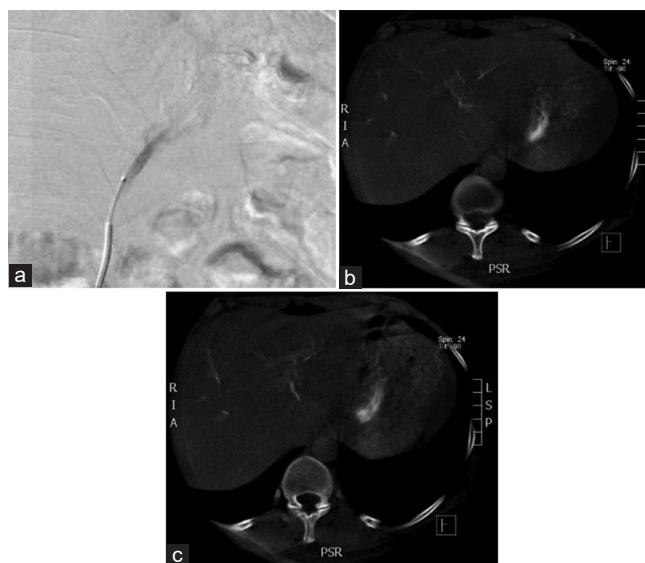


Figure 2: Post-embolization left gastric artery angiogram (a) and axial cone-beam computed tomography (b and c)

lesser curvature. Plication was performed for the proximal staple line as reinforcement using 2/0 Ethibond suture and followed by routine omentopexy along the sleeve to avoid torsion or twisting. The patient had an uneventful recovery and was discharged home after 1 day from surgery.

She had follow-up visits in the bariatric surgical clinic at 2 weeks, 1 month, 3 months, and 6 months after surgery. She lost 5.5 kg within the first 2 weeks with no symptoms suggestive of possible ischemia. The patient was following standard postsleeve gastrectomy dietary regimen with multivitamin supplements. The patient's total weight loss at 1, 3, and 6 months was 7.5, 10.5, and 14 kg, respectively (6-month BMI 27.1 kg/m²).

Discussion

LGA embolization has been performed since the early 1970s as a treatment for upper GI bleeding. Bariatric embolization is a well-tolerated procedure and promotes clinically relevant weight loss in adults with severe obesity.^[4] Despite promising preclinical and early clinical data,^[5] there are many unanswered questions that require investigation before BAE can be routinely offered to bariatric patients. One concern is the safety of bariatric surgery after BAE as embolization of the LGA might prevent further obesity surgery procedures, particularly sleeve gastrectomy. The gastroesophageal junction mainly depends on the LGA, and it would be less vascularized after division of the short gastric arteries which is routinely performed during sleeve gastrectomy. In the EMBARGO trial, sleeve gastrectomy was performed on animal models after LGA embolization.^[6] The authors suggested that embolization of the right and left gastroepiploic arteries could increase blood supply to the cardia region, which is usually at risk of leakage after sleeve gastrectomy. Although some authors have cautioned that BAE may preclude future bariatric surgery,^[3,7]

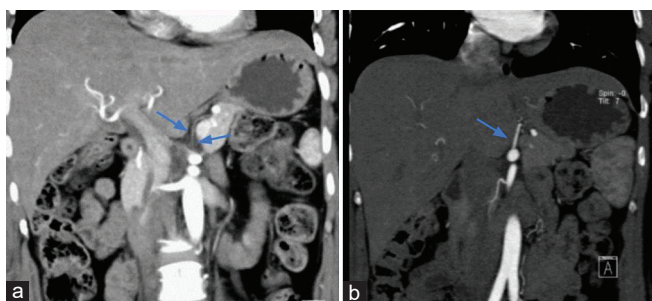


Figure 3: Computed tomography angiogram 3-year postbariatric arterial embolization demonstrates persistent occlusion of left gastric artery with no opacification (arrow) (a) compared to preembolization computed tomography angiography (arrow) (b)

this issue has yet to be investigated in humans. Due to this concern, recommendations have been made with regard to careful multidisciplinary patient selection and counseling of patients who may require future bariatric surgery.^[8]

There has only been one case in the literature that mentioned a patient having bariatric surgery after LGA embolization.^[9] However, this case has only been mentioned in the results section of the study with no clear details about the patient and the outcome of the surgery or the weight changes postoperatively. The presented patient had a successful gastric sleeve surgery 3 years after BAE procedure with no morbidity related to the prior LGA embolization. This suggests that BAE may not preclude future bariatric surgical options. Further evaluation is still required in larger prospective studies.

CONCLUSION

Left gastric artery embolization for obesity is safe and may not preclude future bariatric surgical options.

Financial support and sponsorship

Nil.

Conflicts of interest

There are no conflicts of interest.

References

1. Gunn AJ, Oklu R. A preliminary observation of weight loss following left gastric artery embolization in humans. *J Obes* 2014;2014:185349.
2. Kipshidze N, Archvadze A, Bertog S, Leon MB, Sievert H. Endovascular bariatrics: First in humans study of gastric artery embolization for weight loss. *JACC Cardiovasc Interv* 2015;8:1641-4.
3. Kordzadeh A, Lorenzi B, Hanif MA, Charalabopoulos A. Left gastric artery embolisation for the treatment of obesity: A systematic review. *Obes Surg* 2018;28:1797-802.
4. Weiss CR, Akinwande O, Paudel K, Cheskin LJ, Holly B, Hong K, *et al.* Clinical safety of bariatric arterial embolization: Preliminary results of the BEAT obesity trial. *Radiology* 2017;283:598-608.
5. Weiss CR, Abiola GO, Fischman AM, Cheskin LJ, Vairavamurthy J, Holly BP, *et al.* Bariatric Embolization of Arteries for the Treatment of Obesity (BEAT Obesity) Trial: Results at 1 Year. *Radiology* 2019;291:792-800.
6. Diana M, Pop R, Beaujeux R, Dallemagne B, Halvax P, Schlagowski I, *et al.* Embolization of arterial gastric supply in obesity (EMBARGO): An endovascular approach in the management of morbid obesity. Proof of the concept in the porcine model. *Obes Surg* 2015;25:550-8.
7. Fink JM, Martini V, Seifert G, Marjanovic G. Left gastric artery embolization for weight loss – A dead-end procedure. *Obes Surg* 2018;28:3623-4.
8. Arabi M, Abd El Tawab KA, Almoaiqe M, Chamsuddin A, Ashour M, Gunn AJ, *et al.* Bariatric arterial embolization: Position statement by the Pan Arab interventional radiology and the Saudi interventional radiology societies. *Arab J Interv Radiol* 2020;4:4.
9. Elens S, Roger T, Elens M, Rommens J, Sarafidis A, Capelluto E, *et al.* Gastric embolization as treatment for overweight patients; efficacy and safety. *Cardiovasc Intervent Radiol* 2019;42:513-9.