

Portal Vein Hemodialysis-Tunneled Catheter: A Case Report in a Pediatric Patient with Extensive Systemic Venous Thrombosis

Abstract

We report a case of an 11-year-old child with end-stage renal disease and extensive systemic venous thrombosis including the inferior and superior vena cava. Transhepatic portal vein hemodialysis tunneled catheter was inserted after exhausting all other possible venous access through internal jugular, subclavian, femoral, and hepatic veins.

Keywords: *Difficult hemodialysis access, hemodialysis in central venous occlusion, portal vein hemodialysis, uncommon venous access, vascular access in extensive thrombosis*

Introduction

Hemodialysis patients are at continuous risk of various vascular access loss. Therefore, alternative access sites such as the hepatic veins or inferior vena cava (IVC) through translumbar route have been widely accepted as a moderate to the long-term route of dialysis in patients who have exhausted neck and femoral access sites.^[1] Transhepatic tunneled catheter placement was first described by Po *et al.*^[2] in 1994 as a case report and has been accepted as a dialysis route, yet with considerable complications including infection and thrombosis.^[3] In very rare occasions, some patients develop extensive central venous thrombosis that even transhepatic and translumbar routes get exhausted.

Here, we report a case of portal vein hemodialysis catheter insertion as an alternative venous access.

Case Report

We report a case of an 11-year-old male patient, a known case of chronic kidney disease (CKD5d) due to chronic glomerulonephritis. The patient was started on regular hemodialysis since the age of 4 years, and had undergone 10 vascular operations for maintaining vascular accesses, arteriovenous fistulae and grafts in both upper limbs, as well as multiple nontunneled and tunneled dialysis catheter insertion in the internal jugular and

subclavian veins as well as both femoral veins [Figure 1]. Later, he developed chronic superior vena cava (SVC) and IVC thrombosis, and dialysis was resumed using an 8F nontunneled catheter through the right hepatic vein for nearly 2 months. However, the transhepatic catheter ultimately failed due to thrombosis of the intrahepatic IVC. Acute peritoneal dialysis (PD) was also tried several times but was not successful because of intra-abdominal adhesions of the previous PD. After multidisciplinary consultation with the pediatric nephrology team, portal vein hemodialysis catheter insertion was considered. Procedural risks and complications were explicitly explained to parents, and informed consent was signed.

The procedure was done under general anesthesia. A 15.5 F, 28-cm-long tunneled dialysis catheter (Titan HD™ Long Term Hemodialysis Catheter, Medcomp Medical Company, Harleysville, PA, USA) was used [Figures 2 and 3]. The distal right portal vein was accessed just before the bifurcation by a 16G Angiocath (due to the short length of the access needle with the original set) under ultrasound guidance. Under fluoroscopic guidance, a hydrophilic-coated 150 cm guidewire (Glidewire Terumo Medical Company TMC, Tokyo, Japan) was introduced into portal vein and Superior mesenteric vein. Peel away sheath was advanced over the wire. Subcutaneous tunnel was created, and the catheter was inserted over the wire through the

**Karim A. Abd El Tawab,
Dina E. Sallam¹**

*Department of Radiology,
Interventional Radiology Unit,
Ain Shams University Hospitals,
¹Department of Pediatrics,
Nephrology Unit, Ain Shams
University Hospitals, Cairo,
Egypt*

Address for correspondence:

*Dr. Karim A. Abd El Tawab,
1 Ahmed Abd Elnaby Street,
Alnozha Aljadida, Cairo, Egypt.
E-mail: karimabdeltawab@
gmail.com*

Access this article online

Website: www.arabjir.com

DOI: 10.4103/AJIR.AJIR_26_18

Quick Response Code:



How to cite this article: Abd El Tawab KA, Sallam DE. Portal vein hemodialysis-tunneled catheter: A case report in a pediatric patient with extensive systemic venous thrombosis. *Arab J Intervent Radiol* 2019;3:26-8.

This is an open access journal, and articles are distributed under the terms of the Creative Commons Attribution-NonCommercial-ShareAlike 4.0 License, which allows others to remix, tweak, and build upon the work non-commercially, as long as appropriate credit is given and the new creations are licensed under the identical terms.

For reprints contact: reprints@medknow.com

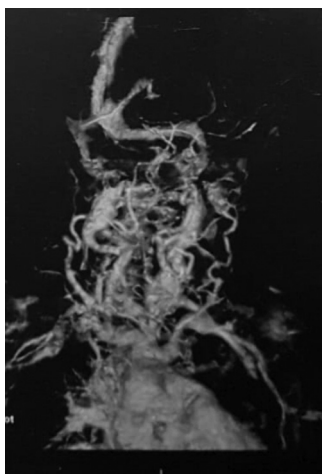


Figure 1: Three-dimensional reconstructed image showing occluded central venous occlusion with extensive mediastinal collaterals

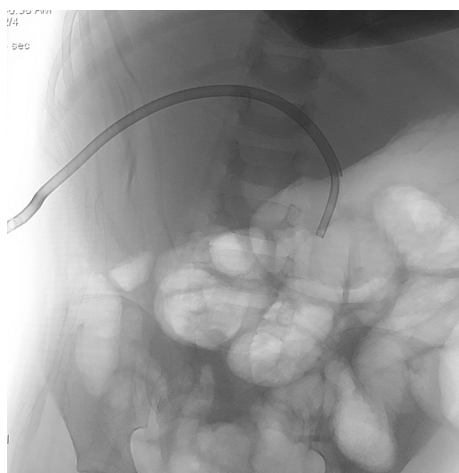


Figure 2: Fluoroscopic image of the catheter in the portal vein

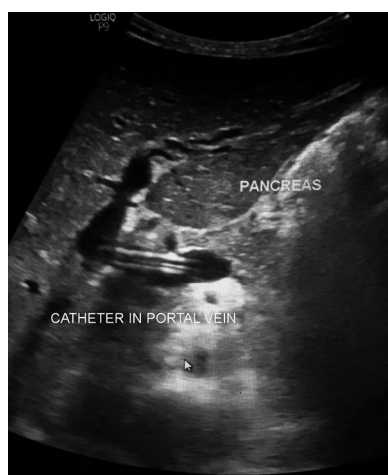

Figure 3: Ultrasound image showing the tunneled catheter in the portal vein

peel-away sheath. Heparinized normotonic saline was injected into the catheter to avoid thrombosis, and the patient was sent for dialysis same day of the catheter application. Hemodialysis was resumed and maintained

with adequate efficiency of dialysis where urea reduction ratio [URR]) was about 60% (Kt/v was nearly 1.2). The patient presented with baseline liver functions as follows: alanine aminotransferase (ALT) 45 U/L, aspartate aminotransferase (AST) 40 U/L, and Bilirubin total 0.9 mg/dL.

The patient presented 4 months later with disturbed consciousness level, dyspnea, tachycardia, fever, and persistent hypotension, a picture suggestive of septic shock denoted by positive blood culture for the mixed growth of Staph Coagulase negative, Klebsiella, and Candida. There was also clinical suspicion of pulmonary emboli, suggested by sudden attacks of tachypnea and marked decrease in oxygen saturation on pulse oximetry and confirmed by investigations (ABG SpO₂ 85%, FDP 15 mg/L, D dimer 2500 ng/mL and electrocardiography of right heart strain and acute cor pulmonale (tall peaked P waves in lead II, P pulmonale), echocardiography with right ventricular dysfunction). His liver profile on presentation was ALT 86 U/L, AST 90 U/L, bilirubin total 1.1 mg/dL. Inotropes and broad-spectrum antibiotics were commenced together with low molecular weight heparin.

His deranged bleeding profile (INR 2.8 and PTT 130s with platelet count 18,000/mm³) precluded removal of the presumably infected catheter. Acute PD catheter was inserted and was poorly functionally for 4 days when the patient died as a result of septic shock.

Discussion

In cases with exhausted arteriovenous fistulae, tunneled dialysis venous catheters are used as a temporary venous access most commonly internal jugular veins, subclavian, and femoral veins. However, exhaustion of all the aforementioned accesses is not uncommon necessitating advanced techniques to maintain effective venous access.^[4,5] Dialysis through hepatic veins has gained acceptance in many patients in various centers around the world, particularly those with fistula and graft exhaustion or multiple recurrent venous occlusions. Another access site is the translumbar route directly to IVC, which may be associated with an increased risk of catheter damage and bleeding. Transhepatic access is always preferred to translumbar in our institute. Furthermore, transhepatic application can be done successfully even if the lower IVC portion is totally occluded (infrahepatic IVC).^[6] Many publications^[1-3,5-7] have discussed the transhepatic and translumbar tunneled catheter application; however, in rare clinical situations, even those uncommon vascular access sites might be exhausted due to extensive central systemic venous thrombosis, and if PD was also non-feasible due to adhesions from recurrent dialysis, those patients are faced by a life-threatening clinical dilemma. Since the use of portal vein as an access for tunneled hemodialysis was not previously described in practice or in the existing literature,

the primary team and operators explicitly counseled the patient's family on the possible risks and benefits. Given the possible variations in portal flow between fasting and postprandial states, adequate dialysis may not be consistently achieved. However, the access was functioning properly for about 4 months before the patient died. Furthermore, the presence of indwelling catheter in the portal circulation may trigger portal vein thrombosis, which may result in fulminant liver failure, mesenteric venous ischemia or complications of portal hypertension. In this case, portal flow and adequate dialysis were maintained until the patient's death, and there was no significant changes in liver function.

In conclusion, although this report presents a case of successful dialysis using portal vein catheter when all systemic venous accesses are exhausted, we do not encourage the use of this access on a regular basis and it should be reserved only for extreme cases as a life-saving measure for short periods of time to avoid PV thrombosis and liver failure complications.

Financial support and sponsorship

Nil.

Conflicts of interest

There are no conflicts of interest.

References

1. Weeks SM. Unconventional venous access. *Tech Vasc Interv Radiol* 2002;5:114-20.
2. Po CL, Koolpe HA, Allen S, Alvez LD, Raja RM. Transhepatic PermCath for hemodialysis. *Am J Kidney Dis* 1994;24:590-1.
3. Stavropoulos SW, Pan JJ, Clark TW, Soulen MC, Shlansky-Goldberg RD, Itkin M, *et al.* Percutaneous transhepatic venous access for hemodialysis. *J Vasc Interv Radiol* 2003;14:1187-90.
4. Kidney Disease Outcomes Quality Initiative (DOQI) update 2000. *Am J Kidney Dis* 2001;34:S141-73.
5. Duncan KA, Karlin CA, Beezley M. Percutaneous transhepatic permCath for hemodialysis vascular access. *Am J Kidney Dis* 1995;25:973.
6. Azizkhan RG, Taylor LA, Jaques PF, Mauro MA, Lacey SR. Percutaneous translumbar and transhepatic inferior vena caval catheters for prolonged vascular access in children. *J Pediatr Surg* 1992;27:165-9.
7. Younes HK, Pettigrew CD, Anaya-Ayala JE, Soltes G, Saad WE, Davies MG, *et al.* Transhepatic hemodialysis catheters: Functional outcome and comparison between early and late failure. *J Vasc Interv Radiol* 2011;22:183-91.