

## Extrinsic Compression of Transplant Hepatic Artery by a Hemostatic Agent: “Surgiceloma”

### Abstract

A 38-year-old man who underwent liver transplantation was found to have absent vascular flow in the common hepatic artery (CHA) on Doppler ultrasound and angiogram 1 day after surgery. Surgical reexploration revealed a mass of expanded Surgicel compressing the CHA. Surgicel is an absorbable hemostatic agent used to control intraoperative bleeding. Blood flow was restored once the mass was removed, and the patient recovered uneventfully. Interventional radiologists need to recognize this finding of extrinsic vascular compression on hepatic angiogram to avoid unnecessary interventions. Furthermore, increased awareness of the clinical and imaging findings associated with compression of an artery by a “Surgiceloma” may increase the consideration of this phenomenon as a differential in the setting of postoperative impaired perfusion.

**Keywords:** Hemostatic agent, liver transplant, Surgicel, vascular compression

**Umar Tariq,  
Dimitra Landis,  
Anil Kotru,  
Ashok Bhanushali**

*Department of Radiology,  
Geisinger Medical Center,  
Danville, PA, USA*

### Introduction

Surgicel (Ethicon: Johnson and Johnson Medical) is a commonly used hemostatic agent composed of oxidized regenerated cellulose (ORC). Retention and expansion of hemostatic agents such as Surgicel may result in extrinsic compression of local neurovascular structures via the formation of a so-called “Surgiceloma,” resulting in neural symptoms and decreased perfusion of associated organs.<sup>[1]</sup> We present a case in which a mass of expanded excess Surgicel resulted in extrinsic compression of the common hepatic artery (CHA) in a transplant patient.

### Case Report

A 38-year-old male with a history of alcoholic cirrhosis presented with acute liver failure complicated with hepatic encephalopathy. The past medical history was significant for acute-on-chronic renal failure, hyponatremia, anemia, and adrenal insufficiency. He underwent orthotopic liver transplantation and did well during the procedure. On postoperative day 1, a Doppler ultrasound (US) showed a slightly diminished resistive index in the main and right hepatic arteries, with mild pulsus parvus et tardus waveform

[Figure 1]. It was initially thought to be secondary to usual postsurgical edema. However, the patient’s liver function tests worsened overnight. Repeat Doppler US on postoperative day 2 showed the absence of diastolic flow in the CHA [Figure 2]. Since findings were suspicious for hepatic artery thrombosis (HAT) and we were not suspecting any extrinsic compression, we chose to investigate further with an angiogram rather than a computed tomography angiogram.

Hepatic artery angiography demonstrated a lack of flow in the CHA, raising concern for HAT [Figure 3]. Emergency exploratory laparotomy revealed a patent CHA with a weak pulse. Examination of the transplant anastomosis site revealed a large mass of expanded Surgicel compressing the CHA. The Surgicel mass was removed resulting in immediate improvement of pulse in the CHA. Two small areas of bleeding from the CHA which were noted on removal of the mass were controlled with two sutures. No other abnormalities were noted, and there was no evidence of HAT. Subsequent intraoperative handheld Doppler demonstrated excellent flow in the CHA, hepatic artery proper, and both the left and right hepatic branches. Intraoperative hepatic angiogram also showed a patent anastomosis with adequate hepatic arterial

#### Address for correspondence:

*Dr. Umar Tariq,  
100 N Academy Ave,  
Danville, PA 17821, USA.  
E-mail: umartariq58@yahoo.  
com*

#### Access this article online

**Website:** www.arabjir.com

**DOI:** 10.4103/AJIR.AJIR\_4\_19

#### Quick Response Code:



**How to cite this article:** Tariq U, Landis D, Kotru A, Bhanushali A. Extrinsic compression of transplant hepatic artery by a hemostatic agent: “Surgiceloma”. Arab J Intervent Radiol 2019;3:65-7.

This is an open access journal, and articles are distributed under the terms of the Creative Commons Attribution-NonCommercial-ShareAlike 4.0 License, which allows others to remix, tweak, and build upon the work non-commercially, as long as appropriate credit is given and the new creations are licensed under the identical terms.

**For reprints contact:** reprints@medknow.com

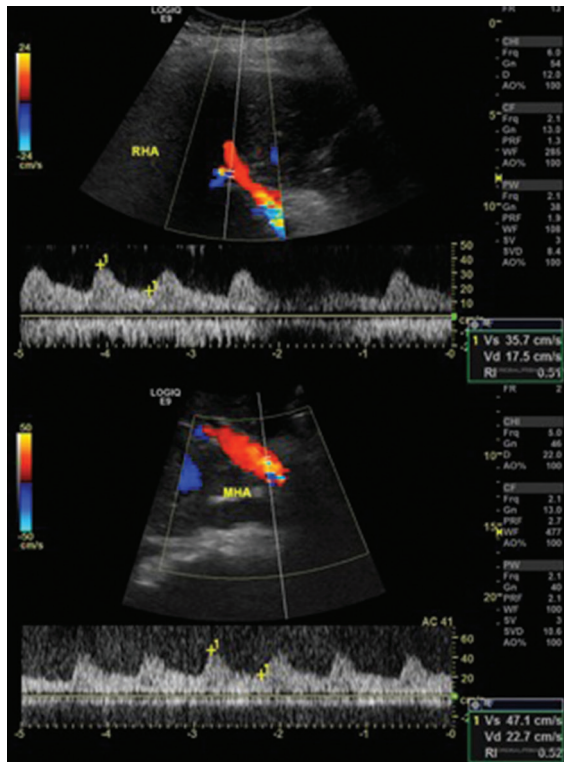


Figure 1: Ultrasound Doppler on postoperative day 1 displaying slightly diminished resistive index in the right and common hepatic arteries with mild pulsus parvus et tardus waveform

flow. Follow-up US Doppler studies showed continued improvement, with adequate blood flow, normal spectral waveforms, and improved resistive index in the hepatic vasculature. Hepatic and perihepatic vascular flow was found to be normal 4 days later, as shown in Figure 4. Liver function tests, the international normalized ratio, and lactate trended downward, and the patient was extubated. His postoperative course was unremarkable.

## Discussion

Patient survival rates post-liver transplant have been steadily improving. Despite this, there remain serious complications from the procedure that have a significant outcome on the patient and may result in retransplantation. They include inflow complications related to portal vein or hepatic artery, outflow complications related to hepatic vein or inferior vena cava, biliary leaks or strictures, postoperative collections or abscesses, graft rejection, or posttransplant malignancy.<sup>[2,3]</sup> Interventional radiology has an important role toward the management of each of these, and on most occasions, it can circumvent a major surgery or even retransplantation.<sup>[2,3]</sup> Hepatic artery complications have been reported in 4%–25% of patients<sup>[4–6]</sup> with life-threatening HAT noted in 3%–9% of patients.<sup>[7,8]</sup> The risk factors for HAT include surgical technique, ischemic reperfusion injury, small donor artery, hepatic artery stenosis, and rejection.<sup>[4]</sup> In general, surgical thrombectomy or reimplantation is typically reserved for cases where the percutaneous methods have failed.<sup>[2]</sup>

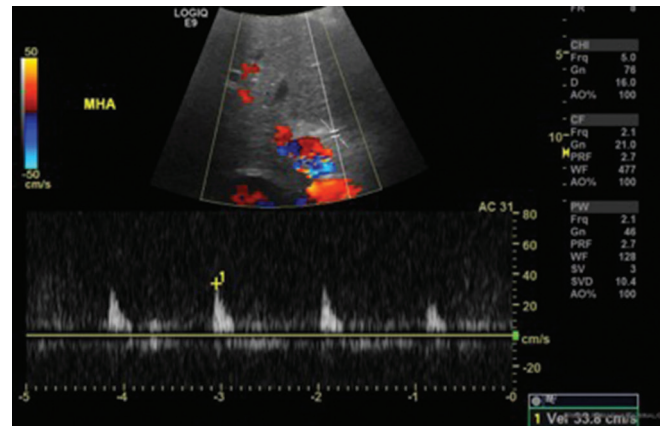


Figure 2: Ultrasound Doppler on postoperative day 2 displaying the absence of diastolic flow in the common hepatic artery

Surgicel is a hemostatic agent manufactured from the wood pulp, which is decomposed and then recombined into regenerated cellulose. It is commonly used to control intraoperative bleeding and functions by swelling into a gelatinous mass as it absorbs blood and by providing a physical matrix for the formation of a clot.<sup>[9]</sup> It also causes a decrease in the pH of its environment, which further aids in clot formation via protein denaturation. The acidic environment produced is also thought to contribute to the antimicrobial effects of ORC.<sup>[10]</sup> ORC is thought to be resorbed within approximately 2–6 weeks, although there have been reported cases of residual ORC present for several years postoperatively.<sup>[9]</sup> A rare complication associated with its use is mechanical compression of local structures by retained and expanded hemostatic product. Its potential to cause neurologic symptoms via cord compression, radiculopathy, and cauda equina syndrome is well-documented and occurs most commonly when the material is packed into rigid cavities such as neural foramina.<sup>[1,11]</sup> In addition, foreign-body reactions to unabsorbed Surgicel have been found to mimic a mass or abscess.<sup>[12,13]</sup> Vascular compression secondary to Surgiceloma is much less common, and all previously reported cases occurred following cardiovascular surgery. Formation of a hematoma around unabsorbed Surgicel has been reported to result in superior vena cava (SVC) syndrome, via compression of the SVC following mitral valve repair.<sup>[14,15]</sup> Two other cases involved periaortic and pulmonary artery compression.<sup>[16,17]</sup> We present a case of vascular compression of the hepatic artery following transplant surgery, which is unique in its involvement of visceral vasculature. These complications may be avoided by judicious intraoperative use of hemostatic agents and their subsequent timely removal following the achievement of hemostasis. Increased awareness of the clinical and imaging findings associated with compression of an artery by a "Surgiceloma" may increase the consideration of this phenomenon as a differential in the setting of postoperative impaired perfusion.

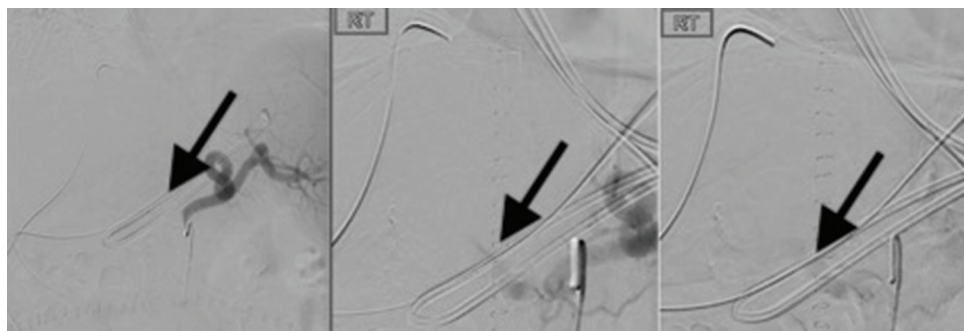


Figure 3: Hepatic angiography on postoperative day 2 with black arrows displaying the absence of satisfactory anterograde flow via the common hepatic artery

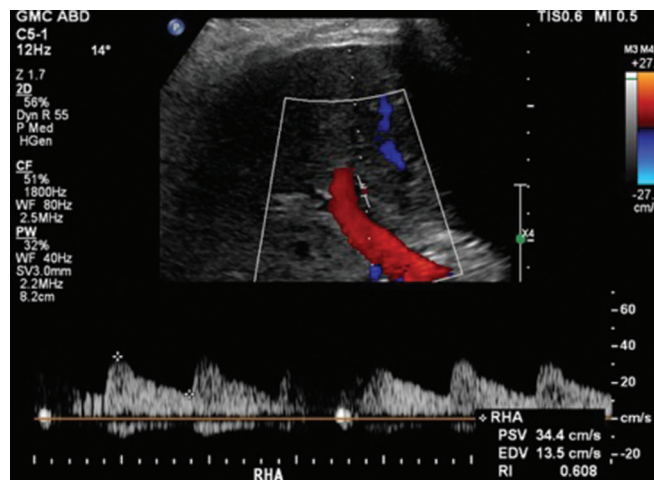


Figure 4: Ultrasound Doppler 4 days following surgical reexploration displaying normal hepatic flow and resistive index

### Financial support and sponsorship

Nil.

### Conflicts of interest

There are no conflicts of interest.

### References

- Banerjee T, Goldschmidt K. 'Surgiceloma' manifested as cauda equina syndrome. *South Med J* 1998;91:481-3.
- Mehrzhad H, Mangat K. The role of interventional radiology in treating complications following liver transplantation. *ISRN Hepatol* 2013;2013:696794.
- Thornburg B, Katariya N, Riaz A, Desai K, Hickey R, Lewandowski R, *et al.* Interventional radiology in the management of the liver transplant patient. *Liver Transpl* 2017;23:1328-41.
- Miraglia R, Maruzzelli L, Caruso S, Milazzo M, Marrone G, Mamone G, *et al.* Interventional radiology procedures in adult patients who underwent liver transplantation. *World J Gastroenterol* 2009;15:684-93.
- Andrews JC. Vascular complications following liver transplantation. *Seminars Interv Radiol* 2004;21:221-33.
- Tso WK. Interventional radiology in the management of complications in liver transplant recipients. *Hong Kong Med Diary* 2010;15:8-10.
- Silva MA, Jambulingam PS, Gunson BK, Mayer D, Buckels JA, Mirza DF, *et al.* Hepatic artery thrombosis following orthotopic liver transplantation: A 10-year experience from a single centre in the United Kingdom. *Liver Transpl* 2006;12:146-51.
- Stange BJ, Glanemann M, Nuessler NC, Settmacher U, Steinmüller T, Neuhaus P, *et al.* Hepatic artery thrombosis after adult liver transplantation. *Liver Transpl* 2003;9:612-20.
- Achneck HE, Sileshi B, Jamiolkowski RM, Albala DM, Shapiro ML, Lawson JH. A comprehensive review of topical hemostatic agents: Efficacy and recommendations for use. *Ann Surg* 2010;251:217-28.
- Schonauer C, Tessitore E, Barbagallo G, Albanese V, Moraci A. The use of local agents: Bone wax, gelatin, collagen, oxidized cellulose. *Eur Spine J* 2004;13 Suppl 1:S89-96.
- Rustagi T, Patel K, Kadrekar S, Jain A. Oxidized cellulose (Surgicel) causing postoperative Cauda equine syndrome. *Cureus* 2017;9:e1500.
- Wang H, Chen P. Surgicel® (oxidized regenerated cellulose) granuloma mimicking local recurrent gastrointestinal stromal tumor: A case report. *Oncol Lett* 2013;5:1497-500.
- Singh A, Jai S, Ganpule S, Ganpule A. Bolster material granuloma masquerading as recurrent renal cell carcinoma following partial nephrectomy. *Indian J Radiol Imaging* 2016;26:352-5.
- Eto K, Matsumoto M, Kubo Y, Kemmochi R. Superior vena cava syndrome caused by a swollen absorbable haemostat after repair of ischaemic mitral regurgitation. *J Cardiothorac Surg* 2014;9:1.
- Syburra T, Weishaupt D, Graves K, Genoni M. Oxidized regenerated cellulose in cardiac computer tomography imaging. *Interact Cardiovasc Thorac Surg* 2011;12:626-7.
- Arora ND, Varghese R, Pavithran S, Kothandam S. The pressures of surgicel® in cardiac surgery. *Ann Pediatr Cardiol* 2015;8:167-9.
- Teis A, Cámara ML, Ferrer E, Romero-Ferrer B. Critical stenosis of pulmonary homograft induced by surgicel in ross procedure. *Asian Cardiovasc Thorac Ann* 2010;18:382-3.