

## How We Do It: Adrenal Biopsy and Ablation

### Abstract

Adrenal lesions represent a heterogeneous group of neoplasms that may be benign or malignant. If imaging fails to exclude a lesion as definitely benign or if molecular profiling is required, percutaneous image-guided biopsy may be indicated. When an adrenal lesion requires surgical resection, some patients are found to be too high at surgical risk or some patients may refuse adrenalectomy. Image-guided percutaneous thermal ablation can be an effective alternative – radiofrequency, microwave, and cryoablation have all been described in literature for the successful treatment of adrenal tumors. In this article, technical and clinical factors that reduce the risk of complications, some unique to the adrenal gland, are discussed.

**Keywords:** *Ablation, adrenal, biopsy, cryoablation, hypertensive crisis, microwave, radiofrequency*

### Introduction

The most common adrenal tumor is the benign nonfunctioning adrenal adenoma.<sup>[1]</sup> These are typically detected incidentally on computed tomography (CT) or magnetic resonance (MR) imaging (MRI). The majority of adrenal adenomas can be accurately characterized by CT (adrenal protocol) or by MRI.<sup>[1,2]</sup> Other benign adrenal lesions include functional adenomas (which may secrete cortisol or aldosterone) and myelolipomas. Catecholamine-secreting pheochromocytomas originate from adrenal chromaffin cells; although most behave as benign lesions, approximately 10% are found to be malignant.<sup>[3,4]</sup> The most common malignant lesion of the adrenal gland is metastasis, most commonly originating from the lung, colon/rectum, and kidney, as well as from melanoma and lymphoma.<sup>[5,6]</sup> Adrenocortical carcinoma is a rare primary malignancy of the adrenal gland; a majority of patients will present with a large adrenal mass (>10 cm) and metastatic disease.<sup>[5,7]</sup>

Although diagnostic imaging is the first-line tool by which adrenal lesions are evaluated, percutaneous image-guided biopsy is critical to establish definitive histologic characterization. Biopsy may be necessary in patients when imaging is ambiguous (i.e., lesion cannot be

definitively characterized on imaging as an adenoma), when there are multiple malignancies, or if molecular profiling is necessary for treatment selection or clinical trial enrollment. The majority of adrenal lesions that undergo biopsy are likely performed in the setting of suspected metastases. Therefore, selection or initiation of systemic therapy may be predicated on the performing tissue or molecular profiling of new or enlarging lesions.

An adrenal lesion may be the sole site of metastatic disease based on biopsy or imaging. In such patients, surgery such as laparoscopic adrenalectomy may be considered, although with potential for significant morbidity. Percutaneous image-guided thermal ablation represents a useful treatment in which surgical risk is high. Radiofrequency ablation (RFA), microwave ablation (MWA), and cryoablation are well-described modalities in the treatment of adrenal masses. Candidates for image-guided ablation include patients with oligometastatic disease involving the adrenal gland who are a poor surgical candidate or who refuses surgery, ablation of the functioning adenoma, small adrenocortical carcinoma, and pheochromocytoma, or palliation of pain related to an enlarging adrenal mass.<sup>[3,5]</sup>

Here, we review clinical and technical considerations paramount to successful percutaneous image-guided adrenal mass biopsy and ablation, as informed by our

**How to cite this article:** Thabet A, Lahoud R, Shaqdan K, Arellano RS, Uppot RN. How we do it: Adrenal biopsy and ablation. *Arab J Intervent Radiol* 2019;3:50-7.

**Ashraf Thabet,  
Rita Lahoud,  
Khalid Shaqdan,  
Ronald S. Arellano,  
Raul N. Uppot**

*Department of Radiology,  
Division of Interventional  
Radiology, Massachusetts  
General Hospital, Boston, MA,  
USA*

### Address for correspondence:

*Dr. Ashraf Thabet,  
Department of Radiology,  
Division of Interventional  
Radiology, Massachusetts  
General Hospital, 55 Fruit  
Street, Gray-290, Boston, MA,  
USA.  
E-mail: athabet@mgh.harvard.  
edu*

### Access this article online

**Website:** [www.arabjir.com](http://www.arabjir.com)

**DOI:** 10.4103/AJIR.AJIR\_6\_19

### Quick Response Code:



This is an open access journal, and articles are distributed under the terms of the Creative Commons Attribution-NonCommercial-ShareAlike 4.0 License, which allows others to remix, tweak, and build upon the work non-commercially, as long as appropriate credit is given and the new creations are licensed under the identical terms.

**For reprints contact:** [reprints@medknow.com](mailto:reprints@medknow.com)

institutional experience as well as practice standards reported in the literature.<sup>[1,3,5,8-10]</sup>

## Imaging the Adrenal Gland

Although large adrenal lesions may be detected by sonography with high sensitivity, CT and MR represent the mainstay imaging modalities for adrenal mass characterization.<sup>[1,2]</sup> As the most common incidentally detected adrenal mass, adenomas may be characterized by tailored CT evaluation or MR, principally due to typically high lipid content.<sup>[1,2]</sup> CT evaluation generally requires assessment of density of the adrenal mass on CT prior to 60 s and 15 min after intravenous contrast administration. If the mass contains sufficient intracellular lipid, diagnosis based on density <10 HU is sufficient. Adenomas with insufficient fat content to meet this threshold can be further evaluated by calculating absolute or relative contrast enhancement washout, >60% or >40%, respectively.<sup>[1]</sup> The lipid content of adenomas also underlies MR characterization with chemical shift imaging; loss of signal on out-of-phase images supports the diagnosis of adenoma.

It is pertinent to note that laboratory evaluation can be an important adjunct to imaging. Patients with cortisol-secreting adenomas may present with Cushing syndrome. Overnight dexamethasone suppression test and 24-h urine free cortisol may support the diagnosis in patients with suggestive clinical features. Similarly, hypokalemia and metabolic alkalosis may suggest aldosteronism, although many aldosterone-secreting adenomas measure <1 cm in size.<sup>[3,11]</sup> Abnormally high urine or plasma metanephrines – metabolites of catecholamines – may suggest pheochromocytoma. Suspicion of pheochromocytoma may be prompted by clinical features of excess catecholamine release (e.g., hypertension) and a hypervascular mass on CT. On MR, pheochromocytomas are typically T2-hyperintense. In an unusual circumstance in which suspected pheochromocytoma requires biopsy, the potential for hypertensive crisis with potentially adverse cardiac and neurologic events at biopsy needs to be recognized and may prompt preprocedure pharmacologic blockade and careful intraprocedural monitoring as described below in the section on ablation. An inhomogeneous mass >4 cm with irregular margins containing hemorrhage and central necrosis is suggestive of adrenocortical carcinoma; suspicion rises where there is extension into the renal vein or inferior vena cava and/or invasion of adjacent structures.<sup>[12]</sup>

## Imaging Guidance

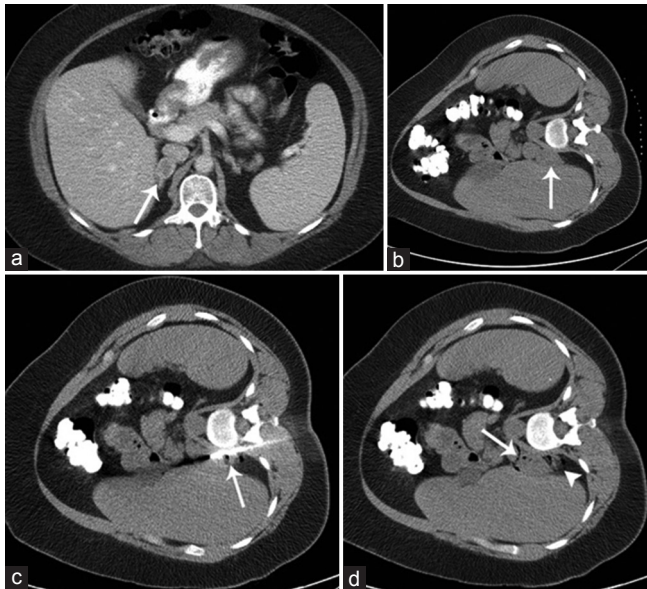
With the ability to visualize intervening structures (e.g., lung), its high spatial resolution, and general wide availability, CT (including CT fluoroscopy) is in general the workhorse guidance modality for nonvascular adrenal

interventions.<sup>[1,3,5]</sup> Nevertheless, the use of CT may be expensive and involves radiation exposure. In some scenarios, ultrasound (US) guidance may be considered an adjunct imaging modality, particularly with the use of fusion imaging, potentially reducing procedural time and enabling real-time multiplanar needle/applicator manipulation not afforded by CT alone.<sup>[13]</sup> MR and positron-emission tomography/CT (PET/CT) guidance have also been described; the latter may be useful if only a small area of a mass is fluorodeoxyglucose avid.<sup>[1]</sup> Nevertheless, MR and PET require specialized equipment and is generally not as widely available for interventional use as CT and US. During ablation, the additional consideration of protecting the adjacent structures from nontarget thermal injury prompts the need for CT (or MR guidance, if available). The operator performing ablation will need to be mindful of one or more of the following adjacent structures: lung, diaphragm, pancreas, bowel, vessels, kidney, ureter, and nerves traversing the psoas muscle (e.g., genitofemoral nerve).

## Image-Guided Biopsy of the Adrenal Gland

Biopsy of the adrenal gland may be indicated when imaging is inconclusive or molecular profiling is required for oncologic treatment. Occasionally, a patient may be referred for biopsy of an adrenal mass in the absence of adequate cross-sectional imaging tailored to evaluate adrenal nodules or in whom prior imaging is already diagnostic. In such cases, discussion with the referring health-care provider is vital to establish the need and timing of biopsy. Preprocedural laboratory values should be reviewed; platelet and coagulation studies are targeted to normal in order to minimize bleeding risk.<sup>[14,15]</sup> Nevertheless, the need to address platelet and coagulation deficiencies will be provider-, institution-, and patient-specific. For instance, a patient with recently placed coronary stent may not be able to stop antiplatelet therapy. In such scenarios, a risk-benefit analysis is performed with discussion between the interventionalist and the referring health-care provider.

We use CT guidance exclusively for adrenal mass biopsy. In general, the most direct route is typically a posterior approach. As such, patient positioning may have a profound effect on which structures may invade the biopsy path. If a posterior approach is selected, the patient is positioned ipsilateral side down (e.g., right adrenal mass entails right lateral decubitus position). This limits diaphragmatic excursion and hence, lesion mobility with respiration. A straight axial trajectory from skin to mass, with a needle, will ideally pass through only fat and muscle with no intervening lung in most cases [Figure 1]. If the intervening lung is present, the needle may be advanced with craniocaudal angulation (coming “underneath lung”). Right adrenal masses may also be attempted from a transhepatic approach and in such cases, supine positioning may suffice.

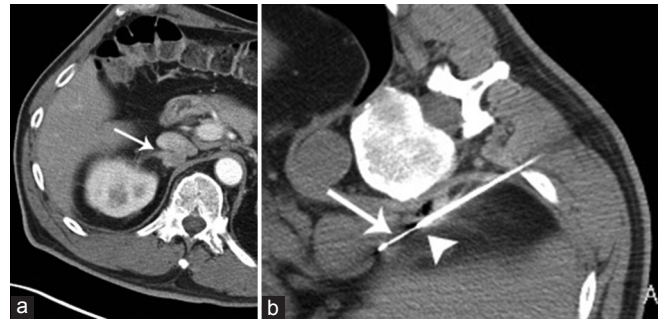


**Figure 1:** A 48-year-old female with a history of non-small cell lung cancer and (a) 3.5-cm right adrenal mass (arrow). (b) Preliminary images from CT-guided biopsy demonstrate the mass (arrow). The patient is in the right lateral decubitus position. (c) 17G introducer needle was advanced from a posterior approach into the lesion and contains an 18G core biopsy device (arrow). (d) Immediate postbiopsy CT demonstrates a small amount of blood products (arrowhead) and locules of air (arrow) within the lesion, due to needle exchanges through the introducer. Pathology confirmed metastasis. CT: Computed tomography

## Technique

Coaxial technique is the most common method for biopsy of most abdominopelvic viscera. An introducer needle is advanced using standard CT guidance or CT fluoroscopy. Once the needle tip is engaged within the target, the stylette is removed and fine-needle aspiration (FNA) and/or core biopsy is obtained [Figures 2 and 3]. At our institution, core biopsy is performed for all adrenal masses as we do not routinely require a cytotechnologist be present to inspect specimens at the time of procedure. In rare instances, FNA alone may be used for very small lesions and/or lesions in which a critical structure adjacent to the target cannot be excluded from a core biopsy throw (e.g., vessel sitting adjacent to the anterior surface of the target when using posterior approach).

In general, we use a 17G introducer, an 18G core biopsy device, and 22–25G fine needles. When FNA is performed, the needle is advanced through the introducer and the stylette is only removed when the FNA needle has engaged the target; this will avoid blood products present within the introducer lumen from filling the FNA needle lumen. As another measure to reduce blood within the FNA sample, application of syringe aspiration during FNA is generally not required unless no sample is obtained after an FNA throw; rather, to-and-fro motion of the FNA needle will allow cells to accumulate within the lumen by capillary action. Some operators prefer to perform FNA prior to core biopsy; if a cytotechnologist or cytopathologist is present at



**Figure 2:** A 64-year-old male with liposarcoma and (a) new 2.1-cm right adrenal nodule (arrow). (b) CT image during percutaneous biopsy with the patient in the right lateral decubitus position. The tip of the introducer (arrowhead) is outside the lesion; ideally, the introducer needle tip should be seated within the lesion to secure access for multiple coaxial biopsies. The side-cutting notch (arrowhead) of the 18G core biopsy device is within the lesion. Pathology confirmed metastasis. CT: Computed tomography

the time of biopsy and the specimen is sufficient, this may obviate the need for core biopsy. In addition, core biopsy might result in a more bloody subsequent FNA specimen. If more specific tissue or molecular profiling is required, and in the instance of lymphoma, core biopsy is essential. Core biopsy specimens of suspected lymphoma are generally sent in saline; most other core biopsy specimens may be sent in formalin although this may be institution dependent. In the setting of lymphoma, if only FNA can be performed, specimens are sent for flow cytometry.

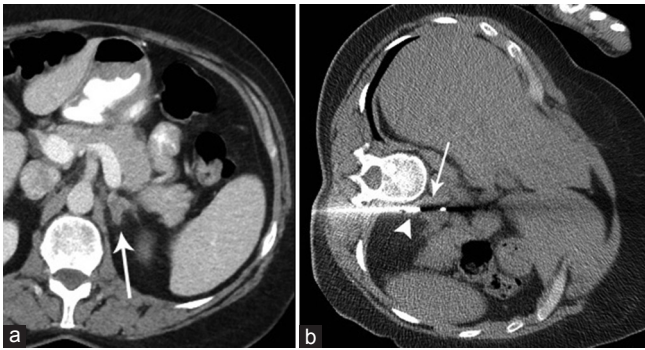
Various core biopsy devices are available that may be used in coaxial fashion. The typical core biopsy device contains a side-cutting notch [Figure 3]. Some of these devices enable exposure of different lengths of this notch (e.g., 1 or 2 cm exposure) depending on the size of the lesion and adjacent structures at the risk of needle injury. Other devices available in the USA include a full-core tri-axial cut-and-capture system. Some devices may also allow the user to adjust the length of capture (e.g., 1, 2, or 3 cm). A full-core system may obtain a complete cylinder of tissue, as opposed to the fractional volume obtained by a side-notch system. Adequacy of tissue volume will depend on the lesion, pathologist, and requested testing; our general aim is to obtain at least two 2 cm-length 18G core specimens or equivalent.

## Complications

The most common complication after adrenal biopsy is hemorrhage, although this is typically self-limiting.<sup>[1]</sup> A small amount of blood products surrounding the target lesion after biopsy [Figure 1] is an expected finding. A transhepatic approach may increase hematoma risk.<sup>[1,16]</sup> Core biopsy does not seem to increase the risk of clinically significant hemorrhage during adrenal biopsy in the needle sizes described above.<sup>[1,16]</sup>

Pneumothorax is another potential complication. The shortest path to adrenal lesions is typically via posterior





**Figure 3:** A 53-year-old female with non-small cell lung cancer and a new (a) 2-cm left adrenal nodule (arrow). (b) The tip (arrowhead) of the 17G introducer needle is seated in the lesion. The side-cutting notch (arrow) of the 18G core biopsy device brackets the lesion. Pathology confirmed metastasis

to anterior approach and therefore, there is a risk that the needle traverses the pleura and even the lung. Most pneumothoraces are observed after needle removal. If a pneumothorax develops prior to needle removal, some operators aspirate the air while the needle is withdrawn. In general, large, enlarging, or clinically significant pneumothoraces will prompt placement of a chest tube. Patients are admitted for overnight management and followed up with chest radiography. In most instances, the chest tube is removed the next day. For clinically silent pneumothorax, follow-up chest radiograph 2 h after the procedure will determine whether it is stable or smaller. The patient may be discharged with clear instructions to go to the nearest emergency room if chest pain or shortness of breath develops.

## Ablation

Image-guided percutaneous thermal ablation of adrenal masses is well documented.<sup>[5,6,17-21]</sup> There are several prerequisites for effective treatment using thermal ablation. First, adequate preprocedural cross-sectional imaging is essential. This may take the form of CT or MR because the *sine qua non* of successful treatment on imaging is lack of contrast enhancement in the ablation zone; preprocedural CT with and without contrast is helpful for future assessment of the ablation zone. Lesion size is also an important consideration – the likely primary success in achieving necrosis in the entire planned ablation zone is inversely proportional to the target zone's size and as such, the prospect of achieving complete necrosis in lesions larger than 5 cm may be guarded.<sup>[22]</sup>

Another prerequisite is a close collaborative relationship with oncologist, endocrinologist, and anesthetist. A multidisciplinary team approach should help inform the need for preablation biopsy. In some instances, diagnosis may not be certain. Biopsy may be performed separately to the ablation; the primary advantages of this approach are that the biopsy may not require the assistance of an anesthesiologist and obviates the need for ablation if

pathology returns with an unexpected result, for example, benign nonfunctioning adenoma. Conversely, biopsy performed immediately prior to ablation saves the patient from multiple procedures, with associated anesthesia risks and disruption to patient's life. The need for biopsy is clearly individualized to the particular case.

Catastrophic catecholamine release is a possibility with ablation of any adrenal lesion due to thermal injury to normal adrenal medullary chromaffin cells.<sup>[8]</sup> Catecholamine release may result in hypertensive crisis and may be associated with cardiac and neurologic sequelae.<sup>[3,23]</sup> As such, adrenal ablations are performed with the assistance of an anesthesiologist. Radial artery blood pressure monitoring is performed at our institution with ready availability of vasodilators if a hypertensive crisis arises. During each phase of the ablation procedure, clear communication among team members in the procedure is essential, i.e., anesthesia is kept apprised about each step of the procedure. Anesthesia may also perform a paravertebral block on the side of ablation to assist in pain control.

When targeting functional lesions, collaboration with an endocrinologist to optimize preprocedural adrenergic blockade is helpful. An alpha-antagonist such as phenoxybenzamine may be started a few weeks prior to ablation. A few days prior to the procedure, beta-blocker therapy is begun; this may minimize the risk of unopposed alpha stimulation if a beta-blocker is started too early.<sup>[8]</sup> Some operators may also add a tyrosine hydroxylase inhibitor to inhibit catecholamine synthesis.<sup>[8,24]</sup> Postprocedural hormone management may be initiated by endocrinologist.

In other lesions, it is critical to note that the destruction of normal adrenal medulla results in the release of stored catecholamines; hence, when normal adrenal gland on the side of ablation is visualized, or if the adrenal gland is not totally encompassed by the mass (lesion  $\leq 4.5$  cm), or if there is no previous radiation or ablation of the target lesion, the risk of hypertensive crisis during ablation of nonfunctioning lesions may be higher.<sup>[8]</sup> A reversible alpha-antagonist may be considered; one regimen may include 1 mg doxazosin mesylate daily for 14 days and 25 mg metoprolol succinate daily for 4 days prior to the day of ablation.<sup>[8]</sup> It is imperative to note that, as reported in one series, pharmacologic blockade using reversible antagonists may not necessarily prevent hypertensive crisis but may reduce the maximum systolic blood pressure observed.<sup>[8]</sup>

Procedural preparation is otherwise similar to other image-guided procedures. Coagulation and platelet laboratory studies should be typically within normal limits as per institutional and the Society of Interventional Radiology guidelines.<sup>[14,15]</sup> Some patients may be discharged the same day even if performed with anesthesia; this is done on a case-by-case basis, but regardless, a plan for

admission for overnight recovery is in place in case the same day discharge becomes unfeasible.

In nearly all cases, adrenal ablations are performed with CT guidance. The patient is placed in ipsilateral decubitus position, as described above for adrenal biopsy. Another risk-modifying technique is hydrodissection. Instillation of a fluid via an 18–22G needle may allow displacement of an adjacent structure otherwise at risk of thermal injury.<sup>[3,22]</sup> Under CT guidance, a 20G Chiba needle (Cook Medical, Bloomington, IN, USA) is advanced into a plane between the adrenal lesion and the adjacent structure, a small amount of fluid is instilled (10–20 mL), and CT is performed to assess the fluid spread. Normal saline is adequate if MWA or cryoablation is planned because ionic solutions may conduct current, 5% dextrose in water (D5W) is selected in RFA cases.<sup>[3]</sup> In most cases, we use a 1:25–1:50 dilution of iodinated contrast in either solution to better delineate the hydrodissectant fluid, margins of the lesion, and adjacent structures.<sup>[3]</sup> A target separation of at least 10 mm is desired and, as such, is the primary determinant of the total volume of hydrodissectant instilled; intermittent imaging during the procedure is important to ensure the maintenance of displacement and prompt additional volume of hydrodissectant, if necessary.

### Radiofrequency Ablation

Perhaps, the most well-established thermal ablative technique is RFA. RFA has been reported in the treatment of adrenal metastases, pheochromocytoma, and adrenocortical carcinoma.<sup>[3,17,19,25]</sup> With RFA, a current is applied through a circuit composed of the probe and grounding pads placed on the patient's thighs; this current results in ionic agitation and frictional heat around the probe.<sup>[3]</sup> Adequate cell lysis is achieved at temperatures  $>50^{\circ}\text{C}$ – $60^{\circ}\text{C}$ .<sup>[3]</sup> Available RFA probe designs include a single needle, a cluster probe containing three parallel needles, or a probe with deployable tines; the cluster probe might be most commonly employed for adrenal lesions.<sup>[3,19]</sup> Once the RFA probe is placed within the adrenal lesion, the RFA power is ramped up slowly; adverse hypertensive effects may take several minutes to manifest and may last several minutes after the current is terminated.<sup>[3,19]</sup> As such, the importance of communication among team members regarding each step of the procedure cannot be overemphasized. Multiple overlapping ablations may be required for larger lesions.

### Microwave Ablation

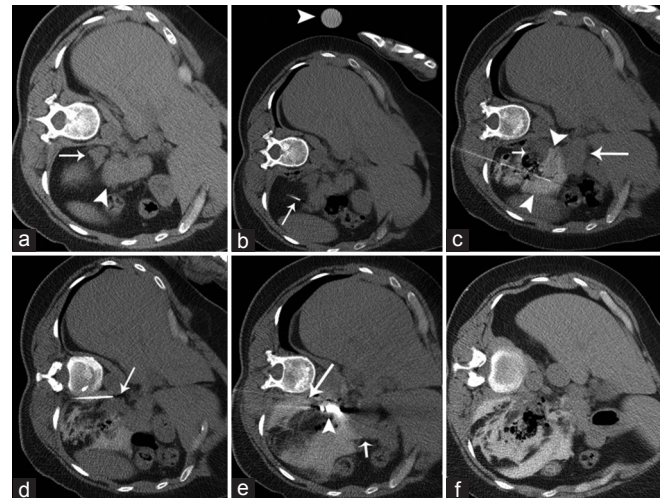
In contrast to RFA, MWA involves direct emission of electromagnetic energy from the microwave antenna (probe). The advantages of MWA over RFA include larger ablation volumes, high temperatures, shorter procedure times, reduced susceptibility to heat sink, and no risk of skin burn as grounding pads are not used.<sup>[3,5,26]</sup> More robust heating may also make MWA a better choice for cystic adrenal lesions.<sup>[3,26]</sup> Yet, such robust and rapid

heating may reduce titratability versus RFA,<sup>[3]</sup> given the risk of catecholamine surge during adrenal ablation, this may represent a relative disadvantage. In our practice, MWA and cryoablation [Figures 4–6] have supplanted RFA for adrenal ablation.

### Cryoablation

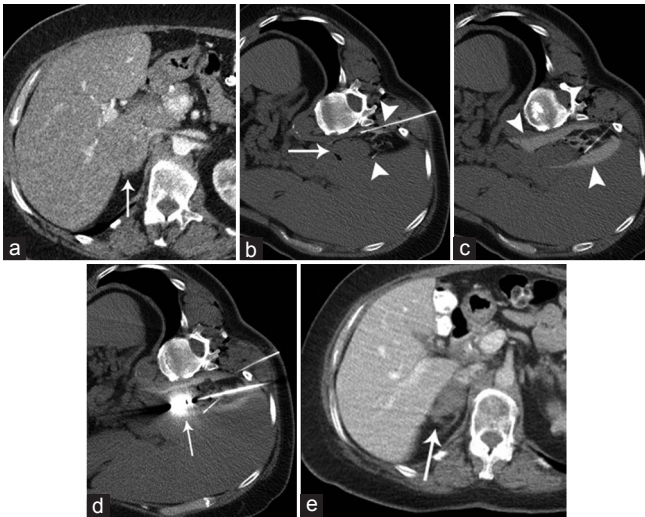
Using the Joule–Thomson principle, cryoablation effectively creates an “iceball;” temperatures within the ablation may be as low as  $-150^{\circ}\text{C}$ .<sup>[3,5]</sup> The extent of cell injury is augmented by alternating periods of freezing with thawing. The extent of cell injury is enhanced by a faster cooling rate, a lower target temperature, and slower thawing. As such, a typical cryoablation program may involve a freeze-slow thaw-freeze cycle of 10, 8, and 10 min, respectively.<sup>[5]</sup>

One principal advantage of cryoablation is visualization of the iceball with imaging [Figure 6]. The iceball will appear as an oval or round hypodensity at the distal portion of the cryoprobe; the edge of the iceball is the  $0^{\circ}\text{C}$  isotherm. Irreversible cell death is generally expected at the  $-20^{\circ}$  to  $-30^{\circ}\text{C}$  isotherm, which is typically 3 mm deep into the edge of the iceball and is an important consideration when planning the ablation zone. Another potential advantage is the ability to place 8–25 cryoprobes at once. Sequential CT during a freeze cycle should confirm the enlargement of the iceball; if concern develops



**Figure 4:** The same patient as in Figure 3. (a) Preliminary image from CT-guided biopsy and microwave ablation demonstrates the mass (arrow) abutting the pancreatic tail (arrowhead), which would be at risk of nontarget thermal injury. (b) A 20G Chiba needle (arrow) was advanced near the pancreatic tail. Syringe (arrowhead) containing hydrodissection solution (1:25 iopamidol contrast in normal saline) was imaged on the top of the patient to confirm adequate dilution. (c) Test injection of the Chiba needle demonstrates hydrodissectant solution (arrowheads) separating the adrenal lesion (short arrow) and pancreatic tail (long arrow). (d) A second 20G Chiba needle (arrow) was placed between the lesion and diaphragmatic crus. (e) A 14G microwave antenna (arrowhead) was inserted into the lesion. Hydrodissection solution (long arrow) abuts the crus and pancreatic tail (short arrow). (f) Immediate postablation CT demonstrates gas locules within the ablation zone, typical during MWA. CT: Computed tomography, MWA: Microwave ablation





**Figure 5:** A 58-year-old female with cholangiocarcinoma and (a) 3.5-cm right adrenal mass (arrow) which abuts the liver and diaphragmatic crus. (b) Prior to MWA, two 20G Chiba needles (arrowheads) are placed medial and lateral to the adrenal mass (arrow). (c) Instillation of 1:25 iopamidol in normal saline (arrowhead) through both needles separates the lesion from the aforementioned structures. (d) A 14G microwave antenna (arrow) is advanced into the lesion. Intermittent CT is performed during ablation to confirm sufficient hydrodissection. (e) Contrast-enhanced CT 1 year after MWA demonstrates no enhancement within the ablation zone (arrow), compatible with treatment success. CT: Computed tomography, MWA: Microwave ablation

that an adjacent structure may be injured, the freeze cycle may be terminated for just the cryoprobe adjacent to that structure.

Release of catecholamines due to heating in RFA or MWA may lead to an intraoperative hypertensive crisis; the operator may respond by terminating heating. The principal disadvantage of cryoablation is that release of catecholamines typically occurs during thawing;<sup>[4]</sup> as such, the ability to immediately stop the ablation is not available and management of the hypertensive crisis is solely medical.

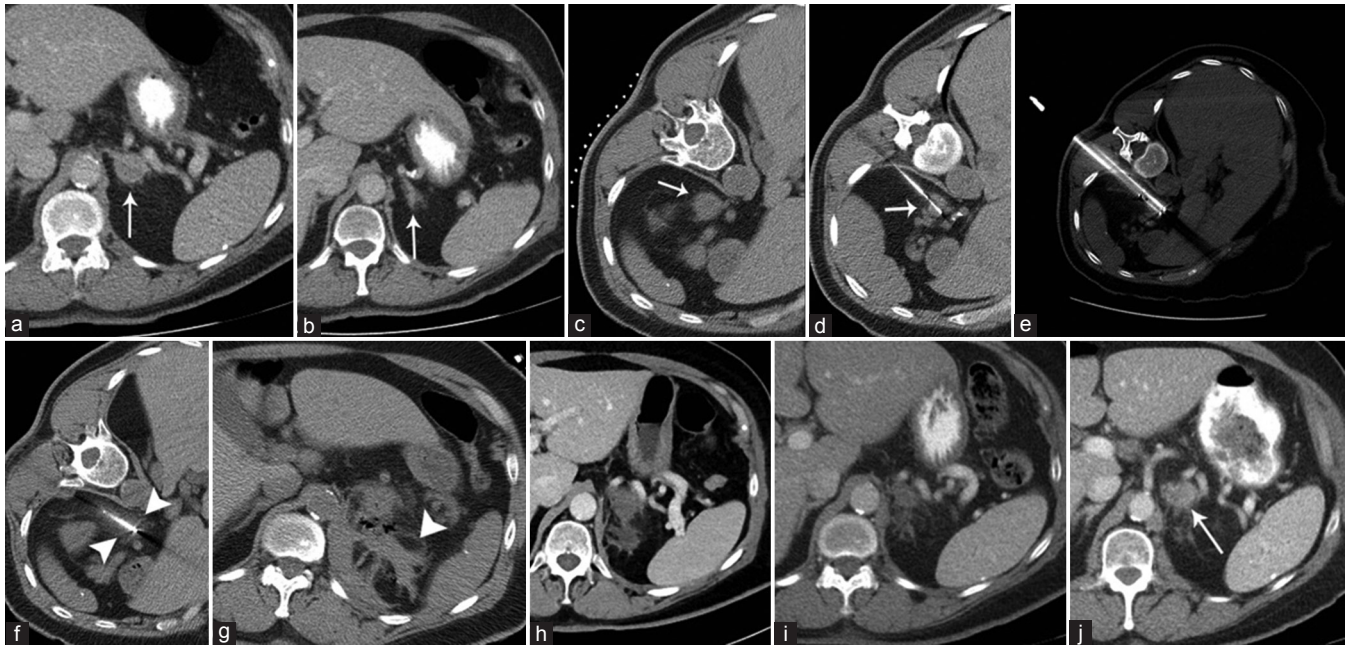
## Complications

Hypertensive crisis is a relatively unique complication of adrenal ablation. As previously discussed, ablation of pheochromocytoma may result in a catecholamine surge. The destruction of normal adrenal medulla results in the release of stored catecholamines; hence, when no normal adrenal gland on the side of ablation is visualized, or when adrenal gland is totally encompassed by a large (>4.5 cm) adrenal mass, or in previously irradiated or ablated adrenal glands, the risk of hypertensive crisis during ablation of nonfunctioning lesions seems to be lower.<sup>[8]</sup>

Other risks are similar to ablation of other organs as well as adrenal biopsy. For instance, nontarget thermal injury to the lung, diaphragm, kidney, and nerves is possible but minimized by meticulous preprocedural planning and intraoperative monitoring.

## Periprocedural Practice Points

1. A review of preprocedural imaging may reveal the need for hydrodissection, the likelihood that multiple ablation sessions may be required (e.g., lesions >5 cm), and whether normal adrenal tissue is visualized on the side of ablation
2. Preprocedural pharmacologic therapy is considered in all pheochromocytoma patients. For other lesions, pharmacologic blockade may be considered when normal adrenal tissue is visualized and/or a lesion is  $\leq 4.5$  cm; MWA may be preferred over cryoablation. Postprocedural hormone replacement may be considered in consultation with endocrinologist, particularly in patients in whom the contralateral adrenal gland is missing or irradiated
3. In general, radial artery blood pressure monitoring with anesthesia support and ready availability of intravenous antihypertensive medications are ensured. A baseline electrocardiogram is obtained prior to the procedure
4. Most patients are positioned ipsilateral side down
5. Preliminary CT demonstrates the lesion and adjacent structures. Our goal is to extend the ablation zone 5 mm external to the margins of the lesion. When used, the hydrodissection needle is left in place for the entire case and additional fluid is instilled if subsequent images demonstrate loss of separation from the adjacent structures
6. The ablation applicator is inserted into the lesion after notifying the anesthesiologist
7. MWA: Power and time are set on the MWA generator, and the ablation program is started after anesthesiologist is informed. Consultation of manufacturer-provided charts and operator experience will guide selection of power (Watts) and time (minutes). Intermittent CT may be performed during the ablation program to assess the status of hydrodissection. For larger lesions, multiple overlapping ablations may be required
8. Cryoablation: Various cryoprobes are typically available for each manufacturer; these may differ in the shape and volume of the predicted iceball. Manufacturer-provided charts and operator experience will inform the selection of cryoprobe type. In many instances, at least 1.5-cm separation of each cryoprobe from the other is desired. The anesthesiologist is notified when each cryoprobe is about to enter the lesion. A 10-min freeze cycle is begun after the anesthesiologist is notified; CT images may be obtained at 3, 6, and 10 min to assess the growing iceball. The freeze program may be terminated early if an adjacent structure is seen to be at risk of injury; only one cryoprobe (closest to the structure at risk) may need to be switched off. An 8-min "passive" thaw (temperature is brought up within a few degrees of 0°C rather than the body temperature) is performed followed by another 10-min freeze cycle, with intermittent CT imaging. The cycles may be



**Figure 6:** A 67-year-old female with non-small cell lung cancer and new (a) 2.3-cm left adrenal nodule (arrow). (b) Normal adrenal tissue (arrow) is seen caudal to the lesion. (c) Preliminary image during CT-guided biopsy and cryoablation demonstrates the lesion (arrow) with no adjacent structures at risk of nontarget thermal injury. (d) 18G core biopsy (arrow) of the lesion was performed immediately prior to ablation to obtain tissue for profiling. (e) Cryoablation was selected as per operator preference. Two of three cryoprobes advanced into the lesion are demonstrated; separation of the cryoprobes by 1.5 cm is ideal. (f) A freeze-thaw-freeze cycle of 10, 8, and 10 min, respectively, was planned. Image is obtained at the end of the first freeze cycle; note the hypodense iceball (arrowheads) encompassing the lesion. Two minutes into the second freeze cycle, a hypertensive crisis developed, with systolic blood pressure exceeding 300 mmHg. The freeze cycle was terminated, and intravenous vasodilator therapy was initiated rapidly by anesthesia. (g) Postprocedure CT demonstrated blood products (arrowhead) within the ablation zone. (h) Contrast-enhanced CT 1 month after ablation demonstrates interval evolution of the ablation zone, with reduction in the size of hematoma. No enhancement in the ablation zone was noted (noncontrast scan not shown). (i) Contrast-enhanced CT 3 months after ablation demonstrates no enhancement in the ablation bed. (j) Contrast-enhanced CT 9 months after ablation demonstrates growth of an enhancing nodule (arrow) in the anterior most aspect of the ablation zone. No further ablation was pursued as the patient developed lung metastases. CT: Computed tomography

abbreviated based on patient-specific factors such as adjacent structures and/or small lesion size. Once the second freeze cycle is complete, an active thaw cycle is performed and cryoprobes are removed

9. A postprocedural CT is performed to monitor for complications. A noncontrast scan will typically show high attenuation within the ablation zone, which may represent coagulation necrosis and/or blood products. Some interventionalists will perform CT with intravenous contrast to assess for residual enhancing tissue and may retreat immediately; this may be challenging after cryoablation as the ablation zone is typically “hard,” complicating needle puncture.

### Follow-Up

Clinic visit is scheduled within 1 month, with follow-up imaging using the same modality and protocol as the preprocedural study (noncontrast and postcontrast images). Nodular/thick areas of enhancement and/or lesion enlargement are suggestive of viable tumor and may prompt consideration for repeat ablation. We generally obtain imaging 1, 3, 6, and 12 months after ablation; subsequent imaging may then coincide with oncologist’s protocol, but is typically no less frequently than once yearly.

### Conclusion

Percutaneous image-guided biopsy and thermal ablation of adrenal tumors are important components of the interventionalists’ armamentarium. With careful attention to history, clinical signs, laboratory values, and preprocedural imaging, coupled with multidisciplinary collaboration, adrenal biopsy and ablation can be highly effective and safe. Indeed, ablation is increasingly recognized as an alternative to adrenalectomy in patients who are poor surgical candidates or who refuse surgery.

### Declaration of patient consent

The authors certify that they have obtained all appropriate patient consent forms. In the form the patient(s) has/have given his/her/their consent for his/her/their images and other clinical information to be reported in the journal. The patients understand that their names and initials will not be published and due efforts will be made to conceal their identity, but anonymity cannot be guaranteed.

### Financial support and sponsorship

Nil.

### Conflicts of interest

There are no conflicts of interest.

## References

- Sharma KV, Venkatesan AM, Swerdlow D, DaSilva D, Beck A, Jain N, *et al.* Image-guided adrenal and renal biopsy. *Tech Vasc Interv Radiol* 2010;13:100-9.
- Song JH, Mayo-Smith WW. Current status of imaging for adrenal gland tumors. *Surg Oncol Clin N Am* 2014;23:847-61.
- Venkatesan AM, Locklin J, Dupuy DE, Wood BJ. Percutaneous ablation of adrenal tumors. *Tech Vasc Interv Radiol* 2010;13:89-99.
- Adler JT, Meyer-Rochow GY, Chen H, Benn DE, Robinson BG, Sippel RS, *et al.* Pheochromocytoma: Current approaches and future directions. *Oncologist* 2008;13:779-93.
- Ethier MD, Beland MD, Mayo-Smith W. Image-guided ablation of adrenal tumors. *Tech Vasc Interv Radiol* 2013;16:262-8.
- Wolf FJ, Dupuy DE, Machan JT, Mayo-Smith WW. Adrenal neoplasms: Effectiveness and safety of CT-guided ablation of 23 tumors in 22 patients. *Eur J Radiol* 2012;81:1717-23.
- Allolio B, Fassnacht M. Clinical review: Adrenocortical carcinoma: Clinical update. *J Clin Endocrinol Metab* 2006;91:2027-37.
- Fintelmann FJ, Tuncali K, Puchner S, Gervais DA, Thabet A, Shyn PB, *et al.* Catecholamine surge during image-guided ablation of adrenal gland metastases: Predictors, consequences, and recommendations for management. *J Vasc Interv Radiol* 2016;27:395-402.
- Gupta S, Wallace MJ, Cardella JF, Kundu S, Miller DL, Rose SC, *et al.* Quality improvement guidelines for percutaneous needle biopsy. *J Vasc Interv Radiol* 2010;21:969-75.
- Ahmed M, Solbiati L, Brace CL, Breen DJ, Callstrom MR, Charboneau JW, *et al.* Image-guided tumor ablation: Standardization of terminology and reporting criteria – A 10-year update. *Radiology* 2014;273:241-60.
- Dunnick NR, Leight GS Jr., Roubidoux MA, Leder RA, Paulson E, Kurylo L, *et al.* CT in the diagnosis of primary aldosteronism: Sensitivity in 29 patients. *AJR Am J Roentgenol* 1993;160:321-4.
- Bharwani N, Rockall AG, Sahdev A, Gueorguiev M, Drake W, Grossman AB, *et al.* Adrenocortical carcinoma: The range of appearances on CT and MRI. *AJR Am J Roentgenol* 2011;196:W706-14.
- Kruecker J, Xu S, Venkatesan A, Locklin JK, Amalou H, Glossop N, *et al.* Clinical utility of real-time fusion guidance for biopsy and ablation. *J Vasc Interv Radiol* 2011;22:515-24.
- Patel IJ, Davidson JC, Nikolic B, Salazar GM, Schwartzberg MS, Walker TG, *et al.* Consensus guidelines for periprocedural management of coagulation status and hemostasis risk in percutaneous image-guided interventions. *J Vasc Interv Radiol* 2012;23:727-36.
- Patel IJ, Davidson JC, Nikolic B, Salazar GM, Schwartzberg MS, Walker TG, *et al.* Addendum of newer anticoagulants to the SIR consensus guideline. *J Vasc Interv Radiol* 2013;24:641-5.
- Welch TJ, Sheedy PF 2<sup>nd</sup>, Stephens DH, Johnson CM, Swensen SJ. Percutaneous adrenal biopsy: Review of a 10-year experience. *Radiology* 1994;193:341-4.
- Mayo-Smith WW, Dupuy DE. Adrenal neoplasms: CT-guided radiofrequency ablation – Preliminary results. *Radiology* 2004;231:225-30.
- Johnson SP, Bagrosky BM, Mitchell EL, McIntyre RC Jr., Grant NG. CT-guided radiofrequency ablation of an aldosterone-secreting primary adrenal tumor in a surgically unfit patient. *J Vasc Interv Radiol* 2008;19:1115-7.
- Venkatesan AM, Locklin J, Lai EW, Adams KT, Fojo AT, Pacak K, *et al.* Radiofrequency ablation of metastatic pheochromocytoma. *J Vasc Interv Radiol* 2009;20:1483-90.
- Abbas A, Idriz S, Railton NJ, McGill N, Nasruddin AB, Sandeman DD, *et al.* Image-guided ablation of Conn's adenomas in the management of primary hyperaldosteronism. *Clin Radiol* 2013;68:279-83.
- Carrafiello G, Laganà D, Recaldini C, Giorgianni A, Ianniello A, Lumia D, *et al.* Imaging-guided percutaneous radiofrequency ablation of adrenal metastases: Preliminary results at a single institution with a single device. *Cardiovasc Intervent Radiol* 2008;31:762-7.
- Yamakado K. Image-guided ablation of adrenal lesions. *Semin Intervent Radiol* 2014;31:149-56.
- Chini EN, Brown MJ, Farrell MA, Charboneau JW. Hypertensive crisis in a patient undergoing percutaneous radiofrequency ablation of an adrenal mass under general anesthesia. *Anesth Analg* 2004;99:1867-9.
- Efremidis SC, Harsoulis F, Douma S, Zafiriadou E, Zamboulis C, Kouri A, *et al.* Adrenal insufficiency with enlarged adrenals. *Abdom Imaging* 1996;21:168-71.
- Wood BJ, Abraham J, Hvizda JL, Alexander HR, Fojo T. Radiofrequency ablation of adrenal tumors and adrenocortical carcinoma metastases. *Cancer* 2003;97:554-60.
- Simon CJ, Dupuy DE, Mayo-Smith WW. Microwave ablation: Principles and applications. *Radiographics* 2005;25 Suppl 1:S69-83.