

Access this article online
Quick Response Code:

Website: www.jlponline.org
DOI: 10.4103/JLP.JLP_121_18

Serological evidence of human leptospirosis in patients with acute undifferentiated febrile illness from Uttarakhand, India: A pilot study

Mohit Bhatia, Pradeep Kumar, Pratima Gupta, Puneet Kumar Gupta, Minakshi Dhar, Deepjyoti Kalita

Abstract:

CONTEXT: To the best of our knowledge, there are no reports of serological evidence of human leptospirosis from Uttarakhand state in India.

AIMS: The aim of this study was to screen for serological evidence of leptospirosis in patients with acute undifferentiated febrile illness at a tertiary care teaching hospital in Uttarakhand.

SETTINGS AND DESIGN: A pilot study was conducted from March to November 2017.

SUBJECTS AND METHODS: Fifty-three adult patients who presented in Medicine outpatient Department with a history of fever of ≥ 7 up to 14 days duration with or without other associated symptoms such as a headache, rashes, myalgia, arthralgia, and conjunctival suffusion were enrolled in the study using convenience sampling technique. Blood samples of these patients were collected and subjected to peripheral smear examination for malaria parasites, dengue immunoglobulin M (IgM) immunochromatographic card test, IgM Typhidot, Leptospira and Scrub typhus IgM ELISA, respectively. Aerobic blood culture was performed in 24 cases. Relevant clinico-epidemiological details were obtained as per the pro forma formulated in accordance with the modified Faine's criteria.

STATISTICAL ANALYSIS USED: Descriptive statistics.

RESULTS: The study population consisted of 50.94% of males and 49.06% of females with a mean age \pm standard deviation of 34.2 ± 15.2 years. Fifty febrile patients had additional symptoms of which myalgia was the most common (81.1%) followed by arthralgia (22.6%). Peripheral smears of all patients were negative for malaria parasites. Dengue and Typhidot IgM positivity was observed in two and eight patients, respectively. Six and five patients were tested positive by leptospira and scrub typhus IgM ELISA, respectively. *Salmonella* Typhi was isolated from blood sample of only one patient. Serum samples of two patients showed dual positivity. All six leptospira seropositive patients satisfied modified Faine's criteria.

CONCLUSIONS: Leptospirosis is a seemingly unexplored infection in Uttarakhand and should be considered as a differential diagnosis in patients with acute undifferentiated febrile illness.

Key words:

Acute undifferentiated febrile illness, leptospirosis, modified Faine's criteria, scrub typhus

Department of
Microbiology, All India
Institute of Medical
Sciences, Rishikesh,
Uttarakhand, India

Address for correspondence:

Dr. Mohit Bhatia,
Department of
Microbiology, All India
Institute of Medical
Sciences, Rishikesh,
Uttarakhand, India.
E-mail: docmb1984@
gmail.com

Submission: 21-09-2018

Accepted: 07-01-2019

Introduction

Leptospirosis is an emerging infectious disease affecting human beings and many other species of vertebrates.^[1] It has

This is an open access journal, and articles are distributed under the terms of the Creative Commons Attribution-NonCommercial-ShareAlike 4.0 License, which allows others to remix, tweak, and build upon the work non-commercially, as long as appropriate credit is given and the new creations are licensed under the identical terms.

For reprints contact: reprints@medknow.com

a wide geographical distribution involving tropical, subtropical and temperate regions and has been recognized as the most common zoonotic infection in the world.^[2] Human leptospiral infections result primarily from direct or indirect exposure to the urine of infected animals.

How to cite this article: Bhatia M, Kumar P, Gupta P, Gupta PK, Dhar M, Kalita D. Serological evidence of human leptospirosis in patients with acute undifferentiated febrile illness from Uttarakhand, India: A pilot study. J Lab Physicians 2019;11:11-6.

Moisture is an important factor of the survival of the leptospires in the environment. Other modes of transmission of infection, such as handling infected animal tissues, ingestion of contaminated food and water, and inhalation of droplets of urine are also possible.^[3] Some important factors which have been implicated in predisposition to this infection are heavy rainfall, animal rearing practices, unplanned urbanization and agrarian way of life.^[4]

Leptospirosis is endemic in many countries of the South East Asia region.^[1] This infection was first recognized in India in 1931. Numerous cases of leptospirosis have been reported from Southern, Central, Eastern, and Western parts of India, where it has long been recognized as one of the foremost causes of acute febrile illness. There are few reports of leptospirosis from North India which could probably be due to a lack of awareness, clinical suspicion and active surveillance.^[4]

Uttarakhand state located in the Northern part of India has a total area of 53,483 km², of which 86% is mountainous and 65% is covered by forest.^[5] It is home to a diversity of flora and fauna. The state experiences moderate to heavy rainfall throughout the year with frequent flooding of several districts. Agriculture is one of the most significant sectors of the economy of Uttarakhand. In spite of all these factors, there are no published reports of human leptospirosis from this region.

This study was conducted to screen for serological evidence of leptospirosis in patients with acute onset of fever at a tertiary care teaching hospital located in Rishikesh, Uttarakhand.

Subjects and Methods

A pilot study was conducted from March to November 2017. Approval to conduct this study was obtained from the Institutional Ethics Committee (81/IEC/PGM/2016). Fifty-three adult patients who presented in Medicine Outpatient Department with a history of fever of ≥ 7 up to 14 days duration with or without other associated symptoms such as a headache, myalgia, arthralgia, conjunctival suffusion, and rashes were enrolled in the study using convenience sampling technique after obtaining informed consent. Blood samples of these patients were collected and subjected to the following tests: (1) Peripheral smear examination for Malaria parasites; (2) Dengue immunoglobulin M (IgM) immunochromatographic card test (ICT) (Denguecheck Combo, Zephyr Biomedicals, India); (3) IgM ICT for enteric fever (Typhidot IgM, Enteroscreen-WB, Zephyr Biomedicals, India); (4) *Leptospira* IgM ELISA (Panbio *Leptospira* IgM ELISA, Germany), and (5) Scrub typhus

IgM ELISA (Scrub Typhus Detect IgM ELISA, InBios International, Inc., USA), respectively. Aerobic blood culture was performed in 24 cases.

Relevant clinical and epidemiological data were obtained as per the pro forma formulated in accordance with modified Faine's criteria recommended by Shivakumar *et al.*^[6] Appropriate scores were assigned to patients taking into account clinical, epidemiological, and laboratory parameters. A score of 26 or more when using Part A or Part A+B or 25 or more using Part A+B+C was presumed to be a case of recent leptospirosis.

Descriptive statistics in the form of mean, standard deviation (SD), and percentages was used for formulating the results of this study.

Results

Baseline characteristics

The study population consisted of 50.9% (27/53) males and 49.1% (26/53) females with a mean age \pm SD of 34.2 ± 15.2 years.

Geographic distribution

Figure 1 depicts the geographical distribution of all 53 patients. Majority of these patients (47.2%) were from Rishikesh followed by Dehradun (26.4%).

Clinical features

Fifty febrile patients had additional symptoms of which myalgia was most common (81.1%) followed by arthralgia (22.6%). While pallor was noted in six of these patients, none had icterus, cyanosis, clubbing, lymphadenopathy, edema, or eschar on clinical examination. These findings are enumerated in Table 1.

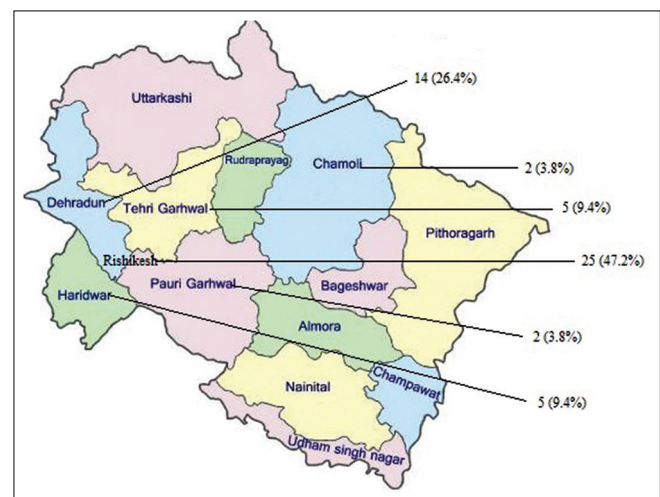


Figure 1: Map of Uttarakhand state in India depicting geographic distribution of patients with acute undifferentiated febrile illness

Antibiotic treatment history

Five patients were receiving treatment with antibiotics before visiting our hospital. Four of these patients were tested negative for malaria, dengue, enteric fever, scrub typhus, and leptospirosis, respectively. One patient was seropositive for scrub typhus.

Diagnostic tests

Peripheral smears of all patients were negative for malaria parasites. Dengue and typhidot IgM positivity was observed in two and eight patients, respectively. Six and five patients were tested positive for *Leptospira* and scrub typhus IgM, respectively. *Salmonella* Typhi was isolated from blood sample of only one out of 24 patients. Serum samples of two patients showed dual positivity. While one of these samples was tested positive for *Salmonella* and Scrub typhus IgM antibodies, the other showed seropositivity for both enteric fever and leptospirosis. However, aerobic blood culture could not be done in these two cases to rule out the prospect of cross-reactivity with enteric fever. Table 2 depicts the results of diagnostic tests performed during the course of this study.

Clinico-epidemiological and laboratory profile of patients seropositive for leptospirosis

Table 3 depicts these findings based on modified Faine's criteria proposed by Shivakumar *et al.*^[6] While all six patients had high-grade fever ($\geq 39^{\circ}\text{C}$) and myalgia, two of these patients also had a headache at the time of presentation. History of exposure to contaminated environment and animals could not be elucidated in these patients. All six patients had a cumulative score of ≥ 25 as per the aforementioned criteria indicative of disease due to infection caused by *Leptospira spp.*

Discussion

The clinical features of leptospirosis resemble a wide range of bacterial and viral diseases.^[7] Anicteric leptospirosis, which is a self-limiting illness, is the most common clinical syndrome. Icteric leptospirosis (Weil's disease), is generally the most severe illness, with symptoms caused by liver, kidney, and vascular dysfunction.^[8] The commonly followed case definition recommended by the World Health Organization and International Leptospirosis Society states that any person presenting with acute onset of fever, headache, and body aches associated with severe muscle tenderness (particularly in calf muscles), hemorrhages (including sub-conjunctival hemorrhage), jaundice, cough, breathlessness and hemoptysis, oliguria, signs of meningeal irritation should be suspected as a case of leptospirosis and investigated.^[9]

In the present study, all febrile patients who were seropositive for leptospirosis were anicteric with

Table 1: Clinical features of patients enrolled in the study (n=53)

Clinical features	Number of patients, n/N (%)
Fever	53/53 (100)
Myalgia	43/53 (81.1)
Arthralgia	12/53 (22.6)
Headache	11/53 (20.8)
Pallor	6/53 (11.3)
Abdominal discomfort	4/53 (7.5)
Nausea and vomiting	2/53 (3.8)
Cough	1/53 (1.9)
Skin rashes	2/53 (3.8)
Eschar	0/53 (0)
Icterus	0/53 (0)
Cyanosis	0/53 (0)
Clubbing	0/53 (0)
Lymphadenopathy	0/53 (0)
Edema	0/53 (0)

Table 2: Results of diagnostic tests

Diagnostic test	Number of patients tested positive, n (%)
Typhidot IgM	8 (15.1)
Leptospira IgM ELISA	6 (11.3)
Scrub typhus IgM ELISA	5 (9.4)
Dengue IgM ICT	2 (3.8)
Peripheral blood smear for malaria parasite	0 (0)

ELISA = Enzyme Linked Immunosorbent Assay,

ICT = Immunochromatographic card test, IgM = Immunoglobulin M

myalgia being the most common symptom. Another notable finding was that none of the study group patients who were seropositive for scrub typhus had an eschar on their bodies. Although eschar is a pathognomonic feature of scrub typhus, its absence does not rule out this infection.^[10] Eschars are rare among Southeast Asian patients.^[11] The low frequency of eschar (10%–19%) has been reported by various investigators, with some reports failing to find eschars in any patients.^[12]

Six patients presenting with acute febrile illness gave positive results with *Leptospira* IgM ELISA. To the best of our knowledge, this is the first report of serological evidence of human leptospirosis from Uttarakhand. Serological evidence of bovine leptospirosis in Uttarakhand has recently been reported by Balamurugan *et al.*^[13] The authors collected a total of 373 serum samples from 45 farms in Maharashtra, Gujarat, Andhra Pradesh, Telangana, Karnataka, Tamil Nadu, Punjab, Haryana, Chhattisgarh, Sikkim, and Uttarakhand states from dairy cattle with a history of reproductive disorders such as abortion, repeat breeding, anoestrus, and endometritis and also from apparently healthy animals. These samples were screened for leptospira serogroup-specific antibodies by microscopic agglutination test (MAT) using a panel of 18 live reference serovar antigens.

Table 3: Clinico-epidemiological and laboratory profile of patients seropositive for leptospirosis based on modified Faine's criteria (n=6)

	Score	Number of patients, n/N (%)*
Part A: Clinical data		
Headache	2	2/6 (33.3)
Fever	2	6/6 (100)
If fever, temperature 39°C or more	2	6/6 (100)
Conjunctival suffusion (bilateral)	4	0/6 (0)
Meningism	4	0/6 (0)
Muscle pain (especially calf muscle)	4	6/6 (100)
Conjunctival suffusion + meningism + muscle pain	10	0/6 (0)
Jaundice	1	0/6 (0)
Albuminuria or nitrogen retention	2	0/6 (0)
Part B: Epidemiological factors		
Rainfall	5	6/6 (100)
Contact with contaminated environment	4	Not available
Animal contact	1	Not available
Part C: Bacteriological and laboratory findings		
Isolation of leptospire in culture	Diagnosis certain	Not applicable
ELISA IgM positive	15	6/6 (100)
MSAT positive	15	Not applicable
MAT single high titre	15	Not applicable
MAT rising titres (paired sera)	25	Not applicable
*Total score ≥ 25 (Parts A + B + C)		6/6 (100)

*Total cumulative score of two patients was 30 and that of the remaining four was 28 each respectively. ELISA = Enzyme Linked Immunosorbent Assay, IgM = Immunoglobulin M, MSAT = Macroscopic slide agglutination test, MAT = Microscopic agglutination test

Few cases of scrub typhus were reported from Uttarakhand in 1992 to 2009, respectively.^[12] Ever since the confirmation of a multi-state outbreak of scrub typhus in 2012 by the National Centre for Disease Control, New Delhi, an increased number of patients have been reported from rural and urban areas of this region.^[14]

In the present study, the serum sample of one patient was tested positive for enteric fever and leptospirosis and that of another patient for enteric fever and scrub typhus, respectively. Both dual infections and serological cross-reactivity between leptospirosis and various other infectious diseases have been reported.^[4,15-18] Seropositivity for both leptospirosis and enteric fever was reported by Sushu *et al.* The authors explained this finding as either co-infection owing to their endemic status, cross-reactivity or nonspecific polyclonal immune reactivity.^[19] In a study conducted by Bhatia *et al.*, 38 out of 50 serologically confirmed enteric fever, Hepatitis B, dengue, and HIV cases were also tested positive for leptospirosis by macroscopic slide agglutination test (MSAT) and IgM ELISA. However, serum samples of all these patients were tested negative by MAT, which is considered as serological gold standard for the diagnosis of leptospirosis. The authors were unsure about the prospect of serological cross-reactivity owing to various diagnostic pitfalls of MAT. They also could not rule the possibility of mixed infections as aerobic blood culture (for enteric fever), and the detection of specific

nucleic acid sequences (for dengue, hepatitis B, and HIV) were not incorporated in the study.^[20]

There are a few case reports on scrub typhus and enteric fever co-infection using Weil-Felix test and Widal, respectively.^[21-24] Gupta *et al.* conducted a study in which 10 out of 258 serum samples of patients with acute febrile illness were positive for both scrub typhus and leptospirosis by IgM ELISA. These dual positive samples were additionally positive by serology for other infections such as Dengue ($n = 2$), *Mycoplasma pneumoniae* ($n = 1$), Malaria ($n = 1$), *Chlamydia pneumoniae* ($n = 6$), Enteric fever ($n = 2$), and *Legionella pneumophila* ($n = 1$)]. Only one case of dual infection was confirmed by polymerase chain reaction.^[25] In a study conducted by Lim *et al.*, the accuracy of a serological gold standard for the diagnosis of scrub typhus was questioned.^[26]

Due to various pitfalls in establishing early diagnosis of leptospirosis, the World Health Organization, introduced Faine's criteria which includes the scoring of clinical, epidemiological, and laboratory parameters of patients (Parts A, B, and C, respectively). This criterion has been simultaneously modified and validated by Brato *et al.* and Shivakumar *et al.* who recommended the addition of abdominal symptoms, local factors such as rainfall and newer investigations in the total scoring, respectively.^[6,27,28] In the present study, 100% leptospira seropositive patients had a cumulative score of ≥ 25 as per modified Faine's criteria indicative of recent leptospirosis.

Variable results have been obtained in several studies which have evaluated the clinical utility of modified Faine's criteria. Leptospirosis was diagnosed using this criteria in 92.2% (106/115) of patients who were tested positive by leptospira IgM ELISA in a study conducted by Jose and Sumana^[29] Sharma *et al.* in their study observed that the sensitivity, specificity and positive predictive value of the WHO modified Faine's criteria for diagnosing leptospirosis were 3.03%, 80%, and 66%, respectively.^[30] Bhatia *et al.* conducted a study in which poor positive predictive values were observed for IgM ICT, MSAT, IgM ELISA, and modified Faine's criteria (14.3%, 6.5%, 8.7%, and 21%) taking MAT as the gold standard.^[31] The conflicting results obtained in these studies could probably be due to several factors such as study design, sample size, gold standard used, and prevalence of the disease. The present study also had certain limitations such as small sample size, not subjecting the leptospira seropositive samples to MAT, and lack of patient treatment and outcome data.

Conclusions

Leptospirosis is a seemingly unexplored infection in the Northern part of India, especially Uttarakhand. It has often been considered as the "mysterious mimic," the diagnosis of which is an uphill task for physicians and diagnosticians alike. More number of studies should be conducted to evaluate and validate different diagnostic tools. Leptospirosis must be considered as a differential diagnosis in patients with acute undifferentiated febrile illness. Modified Faine's criteria can be used as a ready reckoner while evaluating such patients.

Financial support and sponsorship
Nil.

Conflicts of interest

There are no conflicts of interest.

References

- Vijayachari P. Introduction. In: Leptospirosis Laboratory Manual, Regional Medical Research centre, Port Blair, WHO Country office for India, WHO, 2007. p.1-3.
- Narita M, Fujitani S, Haake DA, Paterson DL. Leptospirosis after recreational exposure to water in the Yaeyama Islands, Japan. *Am J Trop Med Hyg* 2005;73:652-6.
- World Health Organization. Leptospirosis Fact Sheet. World Health Organization. Available from: http://www.searo.who.int/about/administration_structure/cds/CDS_leptospirosis-Fact_Sheet.pdf. [Last accessed on 2018 Sep 01].
- Sethi S, Sharma N, Kakkar N, Taneja J, Chatterjee SS, Banga SS, *et al.* Increasing trends of leptospirosis in Northern India: A clinico-epidemiological study. *PLoS Negl Trop Dis* 2010;4:e579.
- Uttarakhand. Available from: <https://www.en.wikipedia.org/wiki/Uttarakhand>. [Last accessed on 2018 Sep 01].
- Shivakumar S, Shareek PS. Diagnosis of leptospirosis utilizing modified Faine's criteria. *J Assoc Physicians India* 2004;52:678-9.
- Sharma KK, Kalawat U. Early diagnosis of leptospirosis by conventional methods: One-year prospective study. *Indian J Pathol Microbiol* 2008;51:209-11.
- Betty AF, Daniel FS, Alice SW, editors. The spirochetes. In: Bailey & Scott's Diagnostic Microbiology. 12th ed. St. Louis, Missouri: Mosby Elsevier; 2007. p. 539-40.
- Singh SS. Clinical Manifestations. In: Leptospirosis Laboratory Manual. Regional Medical Research centre, Port Blair, WHO Country office for India: WHO; 2007. p. 22-6.
- Kurup A, Issac A, Loh JP, Lee TB, Chua R, Bist P, *et al.* Scrub typhus with sepsis and acute respiratory distress syndrome. *J Clin Microbiol* 2013;51:2787-90.
- Mahajan SK. Scrub typhus. *J Assoc Physicians India* 2005;53:954-8.
- Bhargava A, Kaushik R, Kaushik RM, Sharma A, Ahmad S, Dhar M, *et al.* Scrub typhus in Uttarakhand & adjoining Uttar Pradesh: Seasonality, clinical presentations & predictors of mortality. *Indian J Med Res* 2016;144:901-9.
- Balamurugan V, Alamuri A, Bharathkumar K, Patil SS, Govindaraj GN, Nagalingam M, *et al.* Prevalence of leptospira serogroup-specific antibodies in cattle associated with reproductive problems in endemic states of India. *Trop Anim Health Prod* 2018;50:1131-8.
- Mittal V, Bhattacharya D, Chhabra M. Multi-state outbreak of scrub typhus. *NCDC News* 2013;2:3-4.
- Anupriya A, Meera J, Uma A. Dual edge sword-leptospirosis and typhoid coinfection with rare complications – A case report. *Sch J Med Case Rep* 2016;4:363-5.
- Chaudhry R, Das A, Premalatha MM, Choudhary A, Chourasia BK, Chandel DS, *et al.* Serological and molecular approaches for diagnosis of leptospirosis in a tertiary care hospital in North India: A 10-year study. *Indian J Med Res* 2013;137:785-90.
- Mishra B, Singhal L, Sethi S, Ratho RK. Leptospirosis coexistent with dengue fever: A diagnostic dilemma. *J Glob Infect Dis* 2013;5:121-2.
- Chaudhry R, Pandey A, Das A, Broor S. Infection potpourri: Are we watching? *Indian J Pathol Microbiol* 2009;52:125.
- Sushi KM, Sivasangeetha K, Kumar AS, Shastri P, Ganesan A, Anitha D, *et al.* Seroprevalence of leptospirosis, enteric fever and dengue in patients with acute febrile illness in Tamil Nadu, India. *Indian J Basic Appl Med Res* 2014;3:615-23.
- Bhatia M, Umamathy BL, Navaneeth BV. An evaluation of dark field microscopy, culture and commercial serological kits in the diagnosis of leptospirosis. *Indian J Med Microbiol* 2015;33:416-21.
- Manappallil RG. Typh fevers: A combination of typhoid and typhus. *Asian J Med Sci* 2017;8:40-1.
- Mazumder RN, Pietroni MA, Mosabbir N, Salam MA. Typhus fever: An overlooked diagnosis. *J Health Popul Nutr* 2009;27:419-21.
- Basak R, Islam N. Typhus fever: An uncommon childhood infection-report of a case from northern region of Bangladesh. *Chattagram Maa-O-Shishu Hosp Med Coll J* 2013;12:49-51.
- Seow CW, Logarajah V, Tan NW. Typhoid and scrub typhus coinfection in a returned traveler. *Glob Pediatr Health* 2017;4:2333794X17726941.
- Gupta N, Chaudhry R, Mirdha B, Das B, Dar L, Kabra S, *et al.* Scrub typhus and leptospirosis: The fallacy of diagnosing with IGM enzyme linked immunosorbant assay. *J Microb Biochem Technol* 2016;8:71-5.
- Lim C, Paris DH, Blacksell SD, Laongnualpanich A, Kantipong P, Chierakul W, *et al.* How to determine the accuracy of an alternative diagnostic test when it is actually better than the reference tests: A re-evaluation of diagnostic tests for scrub typhus using Bayesian LCMs. *PLoS One* 2015;10:e0114930.
- Faine S. Guidelines for the control of Leptospirosis. *WHO Offset Publ* 1982;67:1-171.

28. Brato DG, Mendoza MT, Coredero CP; Leptospirosis Study Group. Validation of the WHO criteria using the MAT as the gold standard in the diagnosis of leptospirosis. *PJMID* 1998;27:125-8.
29. Jose LR, Sumana MN. Utilization of Faine's criteria for the diagnosis of leptospirosis. *IOSR J Dent Med Sci* 2016;15:28-30.
30. Sharma N, Sethi S, Bhalla A. Evaluation of the Modified WHO Faine's Criteria for Diagnosing Human Leptospirosis in a Tertiary Care Hospital of North India, *Open Forum Infectious Diseases*, Oxford Academic. OUP Academic, Oxford University Press; 2016. Available from: https://www.academic.oup.com/ofid/article/3/suppl_1/1421/2635760. [Last accessed on 2018 Sep 01].
31. Bhatia M, Umapathy BL, Navaneeth BV. Evaluation of diagnostic utility of modified Faine's criteria in leptospirosis-experience from a tertiary care hospital. *Natl J Integr Res Med* 2018;6:20-6.