

# Presentation and Management of Postcircumcision Meatal Stenosis at Hawari Center, Benghazi, Libya: A Clinical Review of 86 Cases

Muftah Hamad Elkhafifi

Hawari Center for Urology and Otolaryngology and Department of Surgery, Faculty of Medicine, Benghazi University, Benghazi, Libya

## Abstract

**Background:** Circumcision is a commonly practiced surgical procedure particularly in Islamic countries. As any other surgical procedure, it is attended by some complications of either early (e.g., bleeding) or late (e.g., meatal stenosis [MS]). **Objectives:** This study was designed to study the different clinical pictures, age at presentation, and management and outcome of postcircumcision MS. **Patients and Methods:** This is a retrospective study involving 86 children diagnosed with symptomatic MS and underwent meatotomy during the period from January 2010 to December 2018 at Hawari Center for Urology and Otolaryngology, Benghazi. The medical records of the patients reviewed included age at presentation, different clinical pictures, management, and outcomes. All patients were circumcised during the neonatal or infancy period. **Results:** Patients' age ranged between 3 and 13 years with a mean age of 5.14 years. More than three-quarters of the patients (84.8%) were between 3 and 8 years of age. Forty-six patients (53.4%) presented with pain (burning) during micturition; 17 patients (19.7%) with thin casting stream; 13 patients (15.11%) with thin dorsally deviated stream; five patients (5.8%) with sudden urge to micturiate; 3 (3.40%) patients with frequency of micturition; and only two patients (2.3%) with prolonged voiding time. All our patients operated by meatotomy as a day case procedure under general anesthesia, and there were no recurrences of MS symptoms in any case during the follow-up period. **Conclusion:** MS is a frequent late complication of neonatal circumcision; it should be excluded by careful meatal examination in any child who is circumcised particularly at the neonatal or nappy period and presented with abnormal micturition or even lower abdominal pain.

**Keywords:** Circumcision, complications, meatal stenosis, neonatal

## INTRODUCTION

Circumcision is the surgical removal of all or part of the human male prepuce. It is estimated that one in three male individuals worldwide is circumcised, with almost universal coverage in some setting and low prevalence in others.<sup>[1]</sup> Circumcision is one of the oldest procedures which was originally used for religious purposes, and religious circumcision is still done by Muslims and Jews worldwide. This surgery is also common in Christian Americans and is performed for cultural, medical, and esthetic reasons among Africans and native Australians.<sup>[2]</sup> The procedure is typically done in the neonatal period for religious reasons but may also be done in older children and adults for the same reasons or to treat several medical conditions including balanoposthitis, phimosis, or paraphimosis.<sup>[3]</sup> Meatal stenosis (MS) is a condition that almost always is acquired and occurs following neonatal circumcision. The risk of MS in

noncircumcised boys is 10–26 times lower than circumcised boys.<sup>[4]</sup>

In most cases, MS does not become apparent until after the child becomes toilet trained and rarely leads to obstructive uropathy. Commonly, the child presents with either a forceful, fine stream that has a great casting distance, dorsally deflected stream, or prolonged voiding times. There are two theories regarding the pathogenesis of MS; ischemic and inflammatory. In a boy with suspected MS, the meatus should be calibrated with a Bougie a

**Address for correspondence:** Dr. Muftah Hamad Elkhafifi,  
Department of Surgery, Faculty of Medicine,  
Benghazi University, Benghazi, Libya.  
E-mail: abdokhaf2007@gmail.com

This is an open access journal, and articles are distributed under the terms of the Creative Commons Attribution-NonCommercial-ShareAlike 4.0 License, which allows others to remix, tweak, and build upon the work non-commercially, as long as appropriate credit is given and the new creations are licensed under the identical terms.

**For reprints contact:** reprints@medknow.com

**How to cite this article:** Elkhafifi MH. Presentation and management of postcircumcision meatal stenosis at Hawari Center, Benghazi, Libya: A clinical review of 86 cases. *Libyan Int Med Univ J* 2019;4:69-73.

**Received:** 16-10-2019 **Revised:** 03-12-2019 **Accepted:** 04-12-2019

**Published Online:** 30-12-2019

### Access this article online

Quick Response Code:



**Website:**  
journal.lim.u.edu.ly

**DOI:**  
10.4103/LIJU.LIJU\_24\_19

boule or assessed with infant sounds. If the meatus is diminished in size or if the child has abnormal voiding symptoms, renal and bladder ultrasound examination is indicated. If the child has a history of urinary tract infection (UTI), a voiding cystourethrogram (VCUG) should be done also. However, MS rarely causes obstructive changes in the urinary tract. In a series of 280 children with MS, 5% of the patients had surgically significant lesions on VCUG, and only 1% had upper urinary tract abnormalities.<sup>[5]</sup> This study was designed to study the different clinical pictures, age at presentation, and management and outcome of postcircumcision MS in Libyan children.

## PATIENTS AND METHODS

This retrospective study was conducted at the Department of Urology, Hawari Center for Urology and Otolaryngology, Benghazi, Libya, during the period from January 2010 to December 2018. Eighty-six patients presented with MS were included in this study with their age range from 3 to 13 years. All patients had a detailed history and genitourinary examination. The medical records were reviewed retrospectively regarding age at presentation, different clinical pictures, management, and their outcomes. Relevant investigations such as complete blood count, blood urea, serum creatinine, bleeding profiles, and urine analysis were evaluated.

The diagnosis of MS was confirmed by the inability to insert an age-matched feeding tube into the urethral meatus and the distortion of the meatus from an ellipsoid to a pinpoint shape. No investigations such as ultrasonography or micturating cystourethrography were performed during the evaluation.

As a curative procedure and under general anesthesia, all of our patients underwent a standard meatotomy as day case procedure where meatotomy done with application of hemostat at the stenosed segment up to a few millimeters down from the meatus for 1–2 min followed by ventral midline incision along the crushed segment. Hemostatic sutures were applied to anchor the urethral mucosa at the meatal lips. Antibiotic dressing was done and postoperative analgesia was prescribed.

### Statistical analysis

Statistical Package for Social Sciences (SPSS) version 15, (IBM Corp., New York, U.S.A.) was used for data presentation and analysis and the results are expressed as frequencies and percentages.

## RESULTS

The mean age of the patients was 5.14 years (range 3–14 years). The majority of patients (73 out of 86) (84.88%) were between 3 and 8 years of age [Figure 1].

The most common symptoms among our patients was pain (burning) during micturition which accounts for 53.4%; followed by thin casting stream (19.76%); dorsally deviated stream (15%); sudden urge to micturition (5.8%); frequency of micturition (3.38%); and prolonged time of micturition (2.32%) [Figure 2].

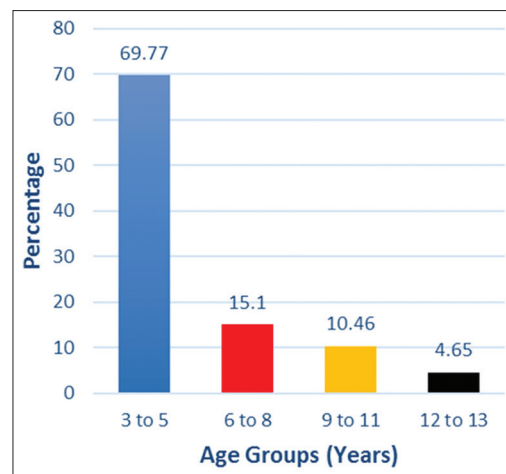


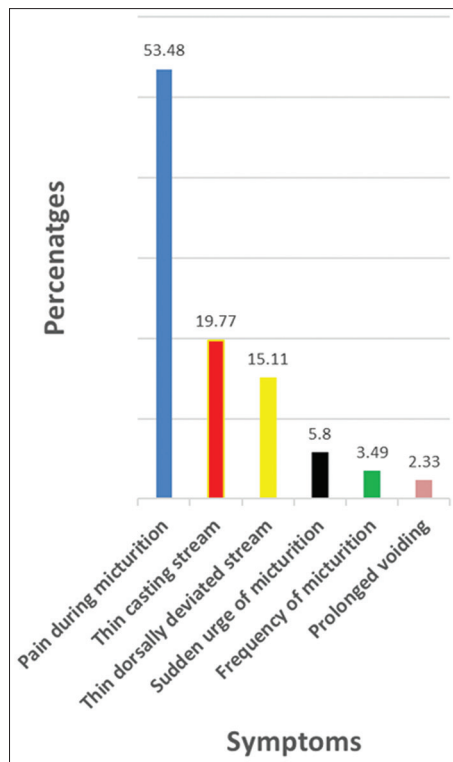
Figure 1: Age groups of children with symptoms of meatal stenosis

After the curative procedures, the patients were followed for a period up to 17 months. No recurrence of any symptoms was seen during the follow-up period.

## DISCUSSION

Circumcision is one of the most common neonatal surgical procedures performed throughout the world, and most of them are performed for religious beliefs, not for medical reasons.<sup>[6,7]</sup> MS is one of the late complications of circumcision that occurs in 5%–20% of circumcised cases.<sup>[8]</sup> However, higher rate may be seen in areas in which the procedure is done by nonqualified regional peoples.<sup>[9,10]</sup> The incidence is significantly higher in neonatal circumcision compared to higher age groups.<sup>[11]</sup> The frequency may be as high as 20% after circumcision if the condition is defined as a meatal diameter of <5 Fr.<sup>[9,12]</sup> It accounts for 26% of late complications.<sup>[10,13]</sup> The wide variations in frequencies of adverse effect following circumcision are likely due to several factors such as age, training, and expertise of the provider.<sup>[14,15]</sup> The pathophysiology of postcircumcision MS is debatable. Two causes are discussed: meatitis and meatal ischemia. Meatitis (nonspecific inflammation of the meatus) is the most common explanation reported in the literature; physiologically, there is eversion of the distal urethral mucosa through the urethral meatus (lips of the meatus) and excisions of the foreskin expose; this everted mucosa to constant forces of friction and trauma from children's underwear.<sup>[16,17]</sup> Another explanation could be ischemia of the meatal mucosa secondary to damage of frenular artery as the frenular artery is possibly the vascular supply to the urethral meatus and perhaps to a larger area of the distal male urethra.<sup>[16,17]</sup>

MS is divided into mild, moderate to severe, and severe. Mild types of MS do not require any treatment, while in moderate-to-severe types, treatment can be done using topical ointment or urethral dilatation. In severe types, surgery such as meatotomy should be performed as a curative procedure.<sup>[2,16]</sup> A cohort study performed by Litvak *et al.* demonstrated that a boy younger than 10 years of age should have a meatus of at



**Figure 2:** Frequency of symptoms of meatal stenosis

least 8 Fr, while boys 11–12 years of age should accommodate at least 10 Fr.<sup>[18]</sup>

Diagnosis of MS is usually based on a change in the elliptical shape of the meatal opening to a circular shape because of fibrosis or scarring, with visually apparent narrowing. There are, however, differences in meatal widths in different males, so a narrow meatus does not necessarily indicate functionally significant stenosis.<sup>[19]</sup>

Our study was a retrospective descriptive study where 86 boys of more than 3 years of age were included in the study. The most common presenting symptoms among our patients were pain (burning) during micturition and thin casting stream, which is consistent with the study done by Mahmoudi on 120 children with MS, where the most prevalent symptoms were dysuria and narrowing of the urinary stream or urinary deviation.<sup>[20]</sup> It is similar to results of study by Cartwright *et al.* where dysuria was the commonest presenting symptom.<sup>[21]</sup> In the study by Persad *et al.* done on 12 cases of MS following circumcision, the main symptoms were penile pain at the initiation of micturition (12 of 12) and narrow, high-speed stream (8 of 12).<sup>[17]</sup> In the study by Ghods *et al.*, the most common symptoms among symptomatic patient group were discomfort on voiding or dysuria and decreased urinary caliber.<sup>[13]</sup> Upadhyay *et al.* reported their 12 years' experience with 50 cases and the most common presenting complaint among 34 (68%) symptomatic patients was decreased urinary caliber.<sup>[22]</sup>

Similar to our results, in the study performed by Joudi *et al.*, 25 out of 27 (92.6%) of symptomatic cases were presented with

decreased urinary width and prolonged voiding times;<sup>[12]</sup> however, prolonged voiding times in our cases represents only 2.3% of all patients.

The differentiation between meatal narrowing and the urethral MS is really the crux of the problem. Stenosis implies disease while narrowing may be only an anatomic variant and visual inspection does not correlate with actual calibration. The clinical status of the patient and not the appearance of the meatus was the deciding factor.<sup>[23]</sup>

MS is one of the late complications of circumcision that is mainly seen 1–2 years later.<sup>[6]</sup> Regarding the age of presentation, it is closely related to the age of circumcision. MS is often missed because boys do not get long-term follow-up care after circumcision. Its symptoms often are mistaken for UTIs and may be treated empirically by antibiotics.<sup>[24]</sup> The symptoms of MS are usually ignored for many months until parents detect the child's voiding habits.<sup>[17]</sup> The mean age at presentation is related to the time of circumcision as we performed our evaluation from the toilet training till puberty (range 3–13 years) with a mean age of 5.14 years. In the study by Upadhyay *et al.*, the mean age at presentation of symptomatic children was 4 years (range 3 months to 13 years);<sup>[22]</sup> whereas the mean age of the patients was 2.5 years (range 3 months to 6 years) in the study by Mahmoudi.<sup>[20]</sup>

### Limitations

The limitations of this retrospective study are the small number of patients enrolled. Moreover, there was no control group. Furthermore, regarding obstructive uropathy secondary to MS, as it is of rare occurrence as noticed by large studies, we reserve the use of auxiliary investigations such as ultrasound scan and retrograde urethrogram for persistence of symptoms during follow-up period after meatotomy.

### Recommendations

Our results highlight the importance of long-term follow-up including genital examination, to detect possible meatal MS as its presentation can be very late.

### CONCLUSION

Although MS is a common long-term complication following circumcision during infancy or nappy age, it continues to be unrecognized condition until toilet training and presentation can be very late. MS needs long-term follow-up, and it should be excluded by careful meatal examination in any child who is circumcised particularly at the neonatal or nappy period and presented with abnormal micturition or even lower abdominal pain.

### Acknowledgments

The author thanks Mr. Anas Ghazi, Miss Salima Elkhafifi, and Miss Amira (IT and communications skills) for their great technical help during the preparation of this manuscript.

### Financial support and sponsorship

Nil.

## Conflicts of interest

There are no conflicts of interest.

## REFERENCES

- Ekenze OS. Complications of neonatal circumcision requiring surgical intervention in a developing country. *J Trop Pediatr* 2013;59:29-7.
- Saeedi P, Ahmadnia H, Akhavan Rezayat A. Evaluation of the effect of meatal stenosis on the urinary tract by using ultrasonography. *Urol J* 2017;14:3071-4.
- Brian K. Circumcision: Preparation, Procedure and follow-up and Recovery Newsletter; 14 June, 2017.
- Frisch M, Simonsen J. Cultural background, non-therapeutic circumcision and the risk of meatal stenosis and other urethral stricture disease: Two nationwide register-based cohort studies in Denmark 1977-2013. *Surgeon* 2018;16:107-18.
- Jack ES. Congenital anomalies of the genitalia. In: Walsh PC, Retick AB, Vaughan ED, Wein AJ, editors. *Campbell-Walsh Urology*. 7<sup>th</sup> ed. Philadelphia: Saunders/Elsevier; 1998. p. 2120-34.
- Karami H, Abedinzadeh M, Moslemi MK. Assessment of meatal stenosis in neonates undergoing circumcision using plastibell device with two different techniques. *Res Rep Urol* 2018;10:113-5.
- Moses S, Bailey RC, Ronald AR. Male circumcision: Assessment of health benefits and risks. *Sex Transm Infect* 1998;74:368-73.
- Frisch M, Earp BD. Circumcision of male infants and children as a public health measure in developed countries: A critical assessment of recent evidence. *Glob Public Health* 2018;13:626-41.
- Bazmamoun H, Ghorbanpour M, Mousavi-Bahar SH. Lubrication of circumcision site for prevention of meatal stenosis in children younger than 2 years old. *Urol J* 2008;5:233-6.
- Mondal SK, Ali MA, Alam MK, Hasina K, Talukder AR, Yusuf MA, *et al*. Use of lubricant at meatus and circumcision site in younger children prevent post circumcision meatal stenosis: A randomized control trial. *J Shaheed Suhrawardy Med Coll* 2013;5:35-8.
- Salimi A, Besharati M, Rashidi Nia SH, Shahmoradi S, Eftekhari SS. Application of the topical hydrocortisone ointment decreases post-circumcision meatal stenosis in neonate: A cross-sectional study. *Int J Pediatr* 2017;5:5061-7.
- Joudi M, Fathi M, Hiradfar M. Incidence of asymptomatic meatal stenosis in children following neonatal circumcision. *J Pediatr Urol* 2011;7:526-8.
- Ghods K, Soltany S, Alavy TJ, Ghorbani R, Arab D, Ardestani-Zadeh A, *et al*. Meatal stenosis following circumcision with plastibell device and conventional dissection surgery; a prospective investigation. *J Renal Inj Prev* 2018;2:84-8.
- Weiss HA, Larke N, Halperin D, Schenker I. Complications of Circumcision in male neonates, infants and children: A systemic review. *BMC Urol* 2010;10:1-13.
- Subramaniam R, Jacobsen AS. Sutureless circumcision: A prospective randomised controlled study. *Pediatr Surg Int* 2004;20:783-5.
- Robson WL, Leung AK. The circumcision question. *Postgrad Med* 1992;91:237-42, 244.
- Persad R, Sharma S, McTavish J, Imber C, Mouriquand PD. Clinical presentation and pathophysiology of meatal stenosis following circumcision. *Br J Urol* 1995;75:91-3.
- Litvak AS, Morris JA Jr., McRoberts JW. Normal size of the urethral meatus in boys. *J Urol* 1976;115:736-7.
- Morris BJ, Moreton S, Krieger JN. Meatal stenosis: Getting the diagnosis right. *Res Rep Urol* 2018;10:237-9.
- Mahmoudi H. Evaluation of meatal stenosis following neonatal circumcision. *Urol J* 2005;2:86-8.
- Cartwright PC, Snow BW, McNees DC. Urethral meatotomy in the office using topical EMLA cream for anesthesia. *J Urol* 1996;156:857-8.
- Upadhyay V, Hammodat HM, Pease PW. Post circumcision meatal stenosis: 12 years' experience. *N Z Med J* 1998;111:57-8.
- American Academy of Pediatrics. Urology section. Urethral meatal stenosis in males. *Pediatrics* 1978;61:778-80.
- Meatal Stenosis. Medscape Website. Available from: <http://emedicine.Medscape.com/article/10160-overview>. [Last accessed on 2019 Sep 16].

## ملخص المقال باللغة العربية

عرض وتدبير تضيق الصّمَاخ البولي ما بعد الختان في مركز هوارى، بنغازي، ليبيا. مراجعة سريرية لـ 86 حالة

المؤلف: مفتاح حمد

مركز الهوارى لجراحة المسالك البولية وطب الأنف والأذن والحنجرة، بنغازي، ليبيا.

البريد الإلكتروني: abdokhaf2007@gmail.com

**الخلفية:** الختان هو عملية جراحية تمارس بشكل شائع خاصة في الدول الإسلامية. مثل أي إجراء جراحي آخر هناك بعض المضاعفات سواء في وقت مبكر (على سبيل المثال، النزيف) أو في وقت متأخر (على سبيل المثال، تضيق الصماخ البولي).

**الأهداف:** تم تصميم هذه الدراسة لدراسة الصور السريرية المختلفة، والعمر في العرض التقديمي، وتدبير ونتائج تضيق الصماخ البولي ما بعد الختان.

**المرضى والطرق:** هذه دراسة رجعية شملت 86 طفلاً تم تشخيص إصابتهم بمرض تضيق الصماخ البولي وخضعوا للفحص في مركز هوارى لجراحة المسالك البولية وطب الأنف والأذن والحنجرة، بنغازي خلال الفترة من يناير 2010 إلى ديسمبر 2018م. شملت السجلات الطبية للمرضى الذين تم استعراضهم العمر عند العرض، والصور السريرية المختلفة، والتدابير الطبية ونتائجها. تم ختان جميع المرضى خلال فترة حديثي الولادة أو الطفولة.

**النتائج:** تراوحت أعمار المرضى بين 3 و13 سنة مع متوسط عمر 5.14 سنوات. كان أكثر من ثلاثة أرباع المرضى (84.8%) تتراوح أعمارهم بين 3 و8 سنوات من العمر. ستة وأربعون مريضاً (53.4%) كانوا يعانون من ألم (حرق) أثناء التبول. 17 مريضاً (19.7%) يعانون من تيار رقيق للبول؛ 13 مريضاً (15.1%) يعانون من تيار انحراف ظهري رقيق للبول. خمسة مرضى (5.8%) من الرغبة المفاجئة للتبول؛ 3 (3.40%) من المرضى كانوا يعانون من تكرار التبول. فقط اثنين من المرضى (2.3%) كانوا يعانون من وقت طويل لتفريغ المثانة. جميع مرضانا تم علاجهم عن طريق شق الصماخ كإجراء لحالة يومية تحت التخدير العام، اختفت جميع أعراض تضيق الصماخ البولي في جميع المرضى خلال فترة المتابعة.

**الخلاصة:** تضيق الصماخ البولي هو من المضاعفات المتأخرة المتكررة لختان حديثي الولادة. يجب استبعادها عن طريق الفحص الدقيق لأي طفل يتم ختانه خاصة في فترة حديثي الولادة أو استعمال الحفاضات، تعرض لتبول غير طبيعي أو حتى ألم أسفل البطن.

**الكلمات المفتاحية:** الختان، المضاعفات، تضيق الصماخ، الولدان، بنغازي، ليبيا.