

## Comparative Study of Subgaleal and Subdural Closed Drain in Surgically Treated Cases of Chronic Subdural Hematoma

### Abstract

**Background:** Chronic subdural hematoma (CSDH) is seen most common in geriatric patients, and trauma is the most important reason for CSDH. Operative treatment of CSDH in symptomatic patients is yet the gold standard of therapy because it allows decompression of the subdural space and aids improvement in neurological status. Burr-hole craniostomy is the most common accepted treatment for CSDH. There is still controversy regarding which type of drain placement is best in the outcome: subdural or subgaleal drain. **Aim:** The aim of the study was to compare the outcome of subgaleal versus subdural drain in surgically treated patients of CSDH. **Materials and Methods:** Patients were assigned by simple random sampling in two groups. The study was conducted from February 2016 to July 2017. A total of 70 patients were enrolled into the study and were divided in two groups (Group 1 – Subgaleal drain; Group 2 – Subdural drain). Statistical analysis was done using Chi-square and *t*-test. Outcome was assessed at the end of hospital stay by modified Rankin scale. Postoperative computed tomography scan was done after 24 h of surgery. **Results:** This study concluded that both types of drains are equally effective for the treatment of CSDH. There is a statistically significant difference in the occurrence of seizure in both the groups as there was no seizure in subgaleal drain group compared to 5 (14.3%) patients who had seizures postoperatively in subdural drain group ( $P = 0.020$ ). There was insignificant difference with respect to preoperative Glasgow Coma Scale/sex/preoperative hematoma volume/postoperative hematoma volume/preoperative midline shift. **Conclusion:** Subgaleal drain is safe and technically easy, as subgaleal drain has no direct contact with brain parenchyma, thus less chances of brain laceration, intracerebral hematoma formation, and seizures.

**Keywords:** Burr hole, chronic subdural hematoma, seizures, subdural drain, subgaleal drain

**Jagminder Singh,  
Shivender Sobti,  
Ashwani  
Chaudhary,  
Vikram Chaudhary,  
Tarun Garg**

*Department of Neurosurgery,  
Dayanand Medical College and  
Hospital, Ludhiana, Punjab,  
India*

### Introduction

Chronic subdural hematoma (CSDH) is one of the most common neurosurgical diseases. The incidence in the general population is 5/100,000/year and is more common in aged population, i.e., 70 years and older with an incidence of 58/100,000.<sup>[1]</sup> Surgical treatment is mainly considered for treatment with burr hole, twist drill, and craniotomy as the preferred procedures.<sup>[2,3]</sup> The incidence of CSDH is gradually increasing as a result of aging population and associated medical conditions like patients on hemodialysis/antiplatelets and anticoagulants. Studies have been done regarding the use of drain or no drain in these procedures.<sup>[4,5]</sup> Few studies have compared the site of drain in CSDH. The present study is done to evaluate the role of site of drain placement in CSDH.

This is an open access journal, and articles are distributed under the terms of the Creative Commons Attribution-NonCommercial-ShareAlike 4.0 License, which allows others to remix, tweak, and build upon the work non-commercially, as long as appropriate credit is given and the new creations are licensed under the identical terms.

For reprints contact: WKHLRPMedknow\_reprints@wolterskluwer.com

### Materials and Methods

Patients were assigned by simple random sampling in two groups. The study was conducted from February 2016 to July 2017. A total of 70 patients were enrolled in the study and were divided in two groups (Group 1 – subgaleal drain; Group 2 – subdural drain). The study was a prospective study. Appropriate institutional ethics committee clearance and patients' consent were obtained. Patients were investigated using computed tomography scan (CT scan). Patients with CSDH having mass effect/worsening condition despite optimal conservative management were included in the study. Patients in whom intraoperative conditions warranted a craniotomy or in whom subdural drain insertion was not feasible were excluded from the study. Statistical analysis was done using Chi-square and *t*-test. The outcome

**How to cite this article:** Singh J, Sobti S, Chaudhary A, Chaudhary V, Garg T. Comparative study of subgaleal and subdural closed drain in surgically treated cases of chronic subdural hematoma. *Asian J Neurosurg* 2021;16:96-8.

Submitted: 22-Mar-2020

Revised: 06-Sep-2020

Accepted: 15-Oct-2020

Published: 23-Feb-2021

### Address for correspondence:

*Dr. Shivender Sobti,  
11/12 B, Opposite BCM School,  
Basant Avenue, Near Dugri,  
Phase 2, Ludhiana - 141 013,  
Punjab, India.  
E-mail: sobtish@gmail.com*

### Access this article online

Website: [www.asianjns.org](http://www.asianjns.org)

DOI: 10.4103/ajns.AJNS\_101\_20

### Quick Response Code:



was assessed at the end of hospital stay by modified Rankin scale (mRS). Postoperative CT scan was done after 24 h of surgery. The number of burr holes was based on surgeon's discretion. Subdural hematoma (SDH) cavity was irrigated copiously with normal saline until clear return came out.

### Placement of drain

Group I – The subgaleal space was dissected widely using a blunt dissector and a subgaleal drain was placed. The end of drain was kept away from the burr hole site to avoid any accidental slippage of the tube into the subdural cavity [Figure 1].<sup>[6]</sup>

Group II – The subdural drain was placed in subdural space.

Romovac suction drain (Romson) was used. The drains were taken out from about 5 cm away from scalp incision. The incision was closed in two layers. The drain was connected to a soft collection bag that was kept in a dependent position. Negative pressure was not applied.

### Results

Seventy patients were enrolled in the study; 35 patients each were enrolled in Group I (with subgaleal drain) and in Group II (with subdural drain).

The common clinical symptoms were headache and hemiparesis. Vomiting is seen in ten patients. Dementia and incontinence were other features. Most of the patients had Glasgow Coma Scale (GCS) 10–15. Sixty-four patients had unilateral SDH and 6 patients had bilateral SDH. Single burr hole was made in 31 patients in Group I and 27 patients in Group II. Double burr holes were made in 2 patients in Group I and 4 patients in Group II. Bilateral burr holes were made in 6 patients. The mean volume was 122.63 mL in Group I and 119.86 ml in Group II. Midline shift in Group I was 6.44 mm and 6.3 mm in Group II. Complications were seen in both the groups. Pneumocephalus was the most common complication which was seen equally in both the groups. Seizures were seen only in subdural group (five patients), while no patient in subgaleal group had seizures. Redo surgery was done in one patient in subgaleal drain group (Group I). Two patients in Group II and one patient in Group I developed intracerebral hematoma (ICH). The difference of seizures in both the groups was found to be significant. The two groups were comparable with regard to age/preoperative GCS/sex/preoperative hematoma volume/preoperative midline shift/residual hematoma/postoperative pneumocephalus [Tables 1 and 2].

### Discussion

CSDH usually forms in the elderly population. The processes involved in the formation of CSDH are angiogenesis, fibrinolysis, and inflammation. The membrane surrounding CSDH is a source of fluid exudation and hemorrhage. Angiogenic stimuli lead to the

**Table 1: Comparison between two groups**

	Group I	Group II
Age (mean)	59.4	60.20
Sex		
Male	22	22
Female	13	13
GCS, mean	13.29	13.49
Volume of haematoma preoperative (ml), mean	122.63	119.86
Midline shift (mm), mean	6.44	6.3
Side		
Left	15	15
Right	18	16
Bilateral	02	04
Burr hole		
Single	31	27
Double	2	4
Bilateral	2	4
Drain duration (h)	34.6	32.91
Volume of hematoma postoperative (ml), mean	19.4	17.8

GCS – Glasgow Coma Scale

**Table 2: Complications in both the groups**

Complications	Group I	Group II
Seizure	0	5
Pneumocephalous	5	5
Redo surgery	1	0
ICH	0	2
Rebleed	1	0
Subdural empyema	0	1

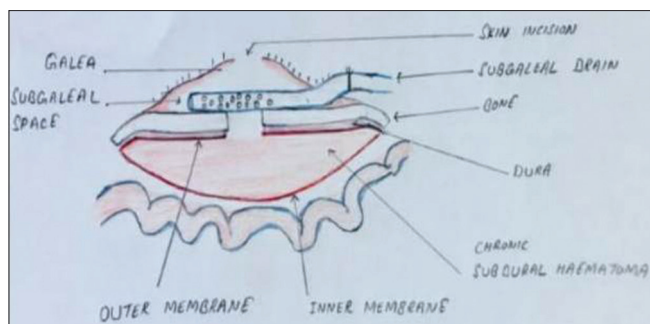
ICH – Intracerebral hematoma

formation of blood vessels which are fragile, while the fibrinolytic processes lead to continuous hemorrhage as they prevent clot formation.<sup>[7]</sup> Santarius *et al.* demonstrated lower recurrence rates in patients in whom drain was used as compared to no drain group at 6-month follow-up. Gazzeri *et al.* and Zumofen *et al.*<sup>[8,9]</sup> reported a case series of extracalvarial (subperiosteal/subgaleal) drain insertion following burr-hole craniostomy (BHC). The result showed recurrence rates comparable to previously published results in literature.

Chih *et al.*<sup>[10]</sup> observed a nonsignificant increase in complications in subdural drain group.

The common clinical symptoms in CSDH are headache and hemiparesis. In our study, the incidence of headache and hemiparesis was 68% and 64%, respectively.

Bellut *et al.*<sup>[11]</sup> published the results on comparison and recurrence in subdural and subgaleal drainage. Hematoma remnant in subgaleal and subdural groups was 6.2% and 1.5%, respectively, and favored subdural drain over subgaleal drain. Guilfoyle *et al.*<sup>[12]</sup> found subdural drain to be more effective in reducing the incidence of residual or recurrent hematoma that required reoperation. In our study, we found 31.4% of patients in subgaleal drain group



**Figure 1: Diagram showing placement of subgaleal drain**

and 22.9% of patients in subdural drain group were having postoperative residual hematoma but was insignificant ( $P = 0.420$ ). The mean residual hematomas in both the groups were also not significant.

Incidence of subdural empyema has been reported to be in a range of 0%–6%. Gazzeri *et al.* and Zumofen *et al.*<sup>[8,9]</sup> reported very low rate of subdural empyema in association with intracranial placement of a drain. In our study, we found one patient of subdural empyema in subdural drain group.

Gazzeri *et al.*<sup>[8]</sup> and Zumofen *et al.*<sup>[9]</sup> reported intracranial hematoma with the use of subdural drain. We reported two cases of ICH in subdural group.

Seizure rates of 2%–19% have been reported in CSDH patients. Oral *et al.*<sup>[13]</sup> found subgaleal drainage as relatively less invasive, safe, as the drainage tube is not in direct contact with the brain tissue and membranes of CSDH. In our study, 4.3% of patients of subdural drain group had postoperative seizures, while there were no seizures in subgaleal group.

Mean mRS was the same in both the groups at the time of discharge in our study. Kaliaperumal *et al.*<sup>[14]</sup> concluded better mRS in the subgaleal group at 6-month follow-up. Insignificant difference in mean hospital stay was observed in both the groups. Yadav *et al.*<sup>[6]</sup> reported similar results.

## Conclusion

Recurrence rates after drainage of CSDH by BHC do not depend on drain position and number of burr holes. Seizure frequency and ICH formation rate are increased in patients having subdural drains. Larger studies having a larger number of patients have to be done to further investigate these findings.

## Financial support and sponsorship

Nil.

## Conflicts of interest

There are no conflicts of interest.

## References

1. Kudo H, Kuwamura K, Izawa I, Sawa H, Tamaki N. Chronic subdural hematoma in elderly people: Present status on Awaji Island and epidemiological prospect. *Neurol Med Chir (Tokyo)* 1992;32:207-9.
2. Santarius T, Lawton R, Kirkpatrick PJ, Hutchinson PJ. The management of primary chronic subdural haematoma: A questionnaire survey of practice in the United Kingdom and the Republic of Ireland. *Br J Neurosurg* 2008;22:529-34.
3. Cenic A, Bhandari M, Reddy K. Management of chronic subdural hematoma: A national survey and literature review. *Can J Neurol Sci* 2005;32:501-6.
4. Karibe H, Kameyama M, Kawase M, Hirano T, Kawaguchi T, Tominaga T. Epidemiology of chronic subdural hematomas. *No Shinkei Geka* 2011;39:1149-53.
5. Krupa M. Chronic subdural hematoma: A review of the literature. Part 1. *Ann Acad Med Stetin* 2009;55:47-52.
6. Yadav YR, Parihar V, Chourasia ID, Bajaj J, Namdev H. The role of subgaleal suction drain placement in chronic subdural hematoma evacuation. *Asian J Neurosurg* 2016;11:214-8.
7. Edlmann E, Giorgi-Coll S, Whitfield PC, Carpenter KL, Hutchinson PJ. Pathophysiology of chronic subdural haematoma: Inflammation, angiogenesis and implications for pharmacotherapy. *J Neuroinflammation* 2017;14:108.
8. Gazzeri R, Galarza M, Neroni M, Canova A, Refice GM, Esposito S. Continuous subgaleal suction drainage for the treatment of chronic subdural haematoma. *Acta Neurochir (Wien)* 2007;149:487-93.
9. Zumofen D, Regli L, Levivier M, Kraysenbühl N. Chronic subdural hematomas treated by burr hole trepanation and a subperiosteal drainage system. *Neurosurgery* 2009;64:1116-21.
10. Chih AN, Hieng AW, Rahman NA, Abdullah JM. Subperiosteal drainage versus subdural drainage in the management of chronic subdural hematoma (a comparative study). *Malays J Med Sci* 2017;24:21-30.
11. Bellut D, Woernle CM, Burkhardt JK, Kockro RA, Bertalanffy H, Kraysenbühl N. Subdural drainage versus subperiosteal drainage in burr-hole trepanation for symptomatic chronic subdural hematomas. *World Neurosurg* 2012;77:111-8.
12. Guilfoyle MR, Hutchinson PJ, Santarius T. Improved long-term survival with subdural drains following evacuation of chronic subdural haematoma. *Acta Neurochir (Wien)* 2017;159:903-5.
13. Oral S, Borklu RE, Kucuk A, Ulutabanca H, Selcuklu A. Comparison of subgaleal and subdural closed drainage system in the surgical treatment of chronic subdural hematoma. *North Clin Istanbul* 2015;2:115-21.
14. Kaliaperumal C, Khalil A, Fenton E, Okafo U, Kaar G, O'Sullivan M, *et al.* A prospective randomised study to compare the utility and outcomes of subdural and subperiosteal drains for the treatment of chronic subdural haematoma. *Acta Neurochir (Wien)* 2012;154:2083-8.