

Cocaine-Induced Massive Ischemic Stroke Treated by Decompressive Craniectomy with Favorable Outcome

Abstract

Cocaine abuse is a significant health hazard with multiple cardiac and neurological complications. Cocaine-induced ischemic stroke can have multiple underlying pathophysiological mechanisms, resulting in various complex neurological presentations. We describe a case of a young man who had a massive ischemic multi-territorial stroke who was managed successfully with decompressive craniectomy with a favorable outcome. Cocaine use should be routinely suspected in young patients presenting with ischemic stroke, and a urine toxicology screen should be part of the initial workup for such patients. Brain magnetic resonance imaging is an essential neuroimaging modality, which is very helpful in confirming the ischemic insult and planning management. Early diagnosis and treatment are crucial due to potential reversibility and reduction of the size of infarcted tissue. In addition, multidisciplinary care, including a vascular neurosurgeon, should be implicated.

Keywords: Cocaine, decompressive craniectomy, ischemic stroke, Saudi Arabia

Introduction

Illicit drugs are illegally produced, trafficked, and/or consumed. These drugs are under international control. According to the United Nations statistics, around 200 million people use illegal drugs yearly around the world, with 25 million being classed as problem users. This number represents approximately 4.8% of the world's population aged 15–64 years.^[1] Intake of illicit drugs has led to major health and social issues due to its increased consumption among young people.^[2] The major causes of death in drug users are overdose, suicide, acquired immunodeficiency syndrome, and violence.^[3] It has been associated with several cardiovascular complications, including myocardial infarction, arrhythmias, endocarditis, dilated cardiomyopathy, major vessel rupture and dissection, including the aorta, sudden cardiac death, arterial thrombosis, and kidney or spleen infarction. Cerebrovascular disorders, both hemorrhagic and ischemic stroke, also contribute to the disability, morbidity, and mortality associated with illicit drug use.^[4] Cocaine-induced ischemic stroke has multiple underlying

pathophysiological mechanisms that result in various complex neurological presentations.^[5] In this article, we describe a case of a young man who had a massive ischemic multi-territorial stroke who was managed successfully with decompressive craniectomy with a favorable outcome. We also describe the mechanisms of the detrimental effects of cocaine and identify the mechanisms of stroke associated with cocaine abuse.

Case Report

A 32-year-old soldier was found unconscious in his military campus while performing night duties. It was estimated that the last time being well was more than 10 h. On arrival to the emergency department, he had dense right hemiplegia with multiple facial traumatic lacerations but no signs of a base of skull fracture, including the battle sign or raccoon eye sign. His blood pressure was high at 180/100 with normal heart and respiratory rates. His breathing pattern was normal with normal pulse oximetry. His Glasgow coma scale was 9/15, and his pupils were equal and reactive. His power was 0/5 on the right side with the right Babinski sign. His

**Hussein
Algahtani^{1,2,3},
Bader Shirah^{2,3},
Mubarak
Algahtany⁴,
Saeed Alqahtani⁴,
Nawal
Abdelghaffar^{5,6}**

¹Department of Medicine, King Abdulaziz Medical City, ²College of Medicine, King Saud Bin Abdulaziz University for Health Sciences, ³King Abdullah International Medical Research Center, Jeddah, ⁴College of Medicine, King Khalid University, ⁵Department of Neurology, Aseer Central Hospital, Abha, Saudi Arabia, ⁶Department of Neurology, Faculty of Medicine, Kasr Al Ainy Hospital, Cairo University, Cairo, Egypt

Address for correspondence:
Dr. Hussein Algahtani,
King Abdulaziz Medical City,
King Saud Bin Abdulaziz
University for Health Sciences,
P.O. Box: 12723, Jeddah,
21483, Saudi Arabia.
E-mail: halgahtani@hotmail.
com

Access this article online

Website: www.asianjns.org

DOI: 10.4103/ajns.AJNS_104_21

Quick Response Code:



This is an open access journal, and articles are distributed under the terms of the Creative Commons Attribution-NonCommercial-ShareAlike 4.0 License, which allows others to remix, tweak, and build upon the work non-commercially, as long as appropriate credit is given and the new creations are licensed under the identical terms.

For reprints contact: WKHLRPMedknow_reprints@wolterskluwer.com

How to cite this article: Algahtani H, Shirah B, Algahtany M, Alqahtani S, Abdelghaffar N. Cocaine-induced massive ischemic stroke treated by decompressive craniectomy with favorable outcome. Asian J Neurosurg 2021;16:830-4.

Submitted: 09-Mar-2021 **Revised:** 15-Aug-2021
Accepted: 21-Aug-2021 **Published:** 18-Dec-2021

modified Rankin scale score was 5. Systemic examination was normal, including skin, bones, cardiovascular system, and abdomen. On questioning the emergency medical services personnel regarding the presence of illegal drugs, they informed us of the presence of alcohol bottles and cocaine powder on the scene. The family admitted illicit drug abuse, but he was never admitted to a hospital for any medical reason.

Initial blood work, including complete blood count, renal function test, electrolytes, glucose, liver function test, thyroid function test, and HIV were all unremarkable. An urgent computed tomography (CT) scan of the brain showed a massive ischemic stroke in the distribution of the left-sided middle and posterior cerebral arteries with right-sided midline shift and impending herniation [Figure 1]. CT angiography of the cerebral circulation showed a patent arterial system. CT of the neck, chest, abdomen, and pelvis was unremarkable. Transthoracic echocardiography was reported as normal with no systolic or diastolic dysfunction and no intracardiac thrombus.

The patient was taken to the intensive care unit, where he was intubated, sedated, and mechanically ventilated. Immediate decompressive craniectomy was done to save the patient's life, which was uneventful [Figure 2]. After a stormy course in the intensive care unit, the patient improved in all aspects, including higher mental functions, alertness, awareness, and cooperation with the medical staff. He was extubated and sent for an aggressive physiotherapy program. He was discharged home on secondary preventive measures, including aspirin and statins after 2 months of hospital stay. At discharge, his modified Rankin scale score improved to 4.

He was admitted electively 3 months later for cranioplasty using an autologous bone, which was performed

successfully. A follow-up CT scan showed remarkable improvement of the midline shift and herniation with residual ischemic infarction in the territory of middle and posterior cerebral arteries on the left side [Figure 3].

Discussion

Cocaine is the second most frequently used illicit drug in both the United States of America and the United Kingdom (after cannabis) with approximately 5%–10% of the American population used illicit cocaine. It is used by around 14 million people around the world which represents 0.3% of the global population between 15 and 64 years old.^[6] It is originally extracted from an *Erythroxylon* coca bush that grows primarily in South America, and coca leaves have been chewed by South American Indians for several centuries.^[7] It is consumed in two chemical forms: cocaine hydrochloride (a water-soluble crystal powder that is absorbed by mucous membranes) and cocaine alkaloid (produced by dissolving cocaine hydrochloride in water, ammonia, and ether to obtain a “free base” or in water and baking soda to produce “crack”). Both forms can be smoked. The alkaloidal form of cocaine known as crack was introduced in 1983 which has led to a major surge in its use, followed by an increase in the incidence of medical, neurologic, and psychiatric complications.^[8] Addiction to stimulants such as cocaine is a chronic disorder that is difficult to treat with exceedingly high rates of relapse that can happen following months or even years of abstinence.^[9]

The increasing use of crack cocaine with a subsequent rise in the complications rate has been reflected in the medical literature. The earliest isolated case reports were

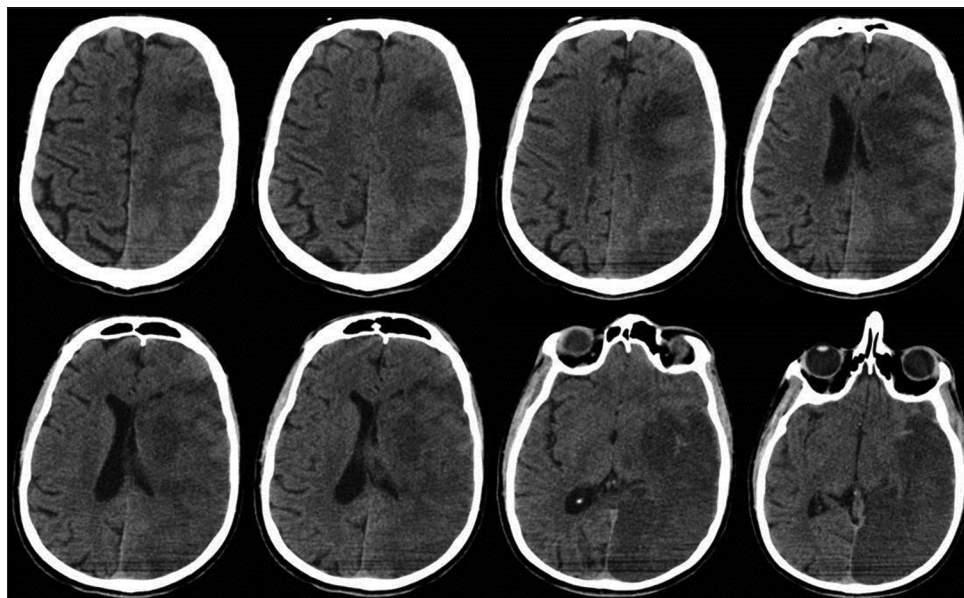


Figure 1: Computed tomography scan of the brain showing a massive ischemic stroke in the distribution of the left-sided middle and posterior cerebral arteries with right-sided midline shift and impending herniation

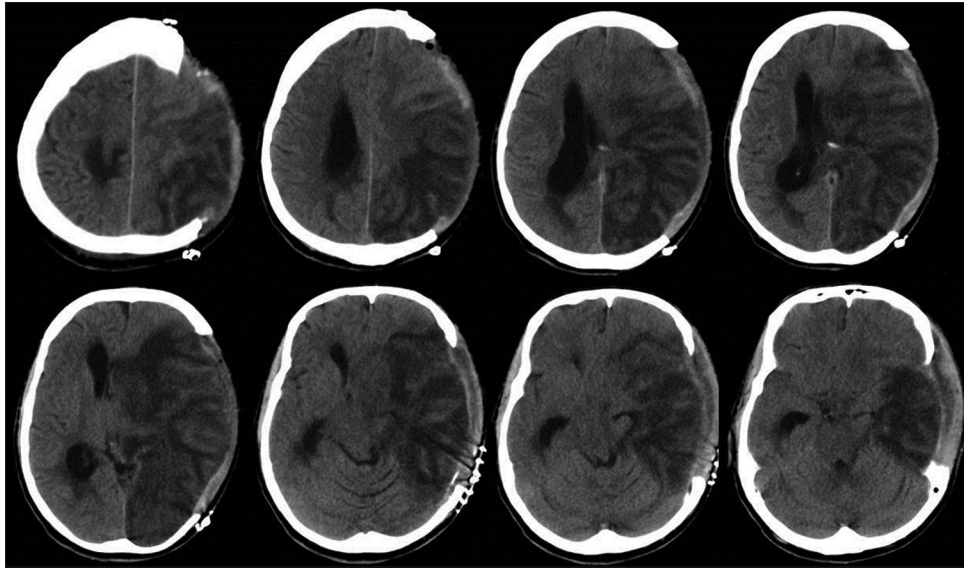


Figure 2: Computed tomography scan of the brain after decompressive craniectomy showing evolutionary changes of the massive left-hemispheric infarction with persistent rightwards midline shift and left uncal herniation

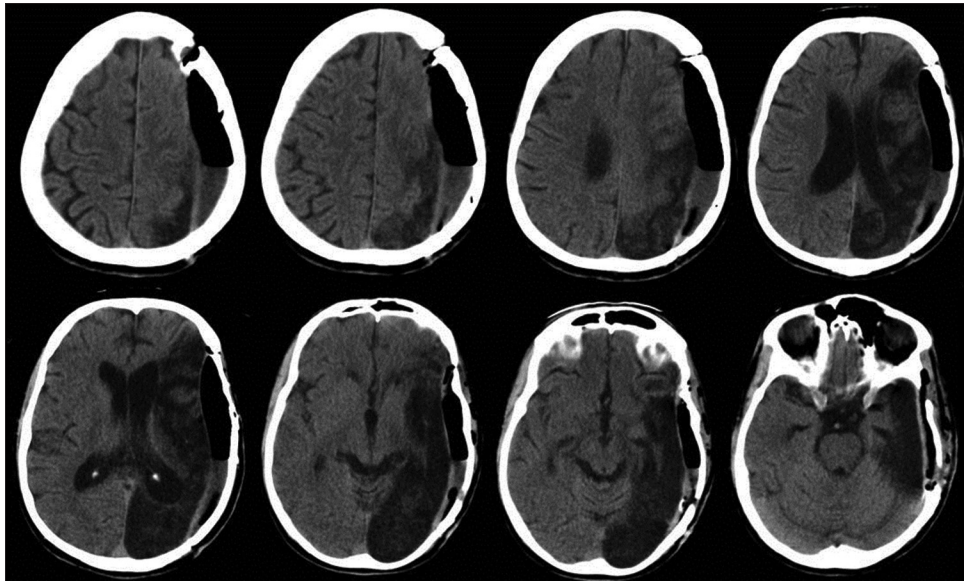


Figure 3: Computed tomography scan of the brain 3 months later showing remarkable improvement of the midline shift and herniation with residual ischemic infarction in the territory of middle and posterior cerebral arteries on the left side

replaced by a series of accounts of systemic complications of crack cocaine. These accounts were followed by publications describing specific complications such as cardiac, neurological complications, and rhabdomyolysis.^[10] Cocaine toxicity may affect almost every organ system in the body, with the most substantial changes seen in the cardiovascular system, liver, and brain. Cocaine appears to be hepatotoxic in both humans and animals, and this hepatotoxicity is enhanced by concomitant drug abuse, including alcohol, barbiturates, and cocaine adulterants. Cocaine abuse may lead to several pulmonary disorders, including barotrauma, pneumonia, pulmonary congestion, edema, hypertrophy of pulmonary arteries, and pulmonary necrosis.^[7]

Neurological complications related to cocaine use include neurovascular events (cerebral or spinal), seizures, hyperpyrexia, headache, movement disorders, and peripheral neuropathy.^[11] Cocaine is associated with 14 times more probability of developing a stroke than that noncocaine-using subjects of the same age recruited from the same patient pool. Ischemic strokes represent between 25% and 60% of cocaine-induced strokes with about 80% of the infarcts occur in the regional distribution of the middle cerebral artery. They typically occur in young adults without preexisting vascular malformations or other risk factors for strokes.^[12] In 1977, the first report of a cocaine-related stroke was published by Brust and Richter, which was accepted with skepticism.^[13] A few years

later, several isolated case reports were published which suggested that this was an extremely rare complication. However, since 1985 the incidence of cocaine-related cerebrovascular complications has reached epidemic proportions.^[14]

The main mechanism of cocaine action is explained by its capability of blocking sodium channels leading to the inhibition of the reuptake of norepinephrine, 5-hydroxytryptamine, and dopamine, also known as a triple reuptake inhibitor. This may result in massive sympathetic overactivity and catecholamine release, leading to tachycardia, arrhythmia, profound hypertension, intense vasoconstriction, acute coronary syndrome, and even sudden cardiac death. This mechanism may trigger transient cardiac ischemia resulting in partial or global ventricular wall abnormality far better than any other stimulant drug due to its unique lipophilic efficiency.^[15] Cocaine may cause platelet activation, α -granule release, and platelet containing microaggregate formation producing a prothrombotic state and predisposition to ischemic events. This mechanism is likely responsible for both middle and posterior cerebral artery strokes in our patient, given his long-standing cocaine use.^[16] Cocaine also induces apoptosis in the cerebral vascular smooth muscles, leading to ischemia and activation of endothelin-1-dependant receptors and subsequent cerebral vasoconstriction.^[17] Cocaine can cross the blood-brain barrier faster leading to cerebral vasculitis, accelerated atherosclerosis, cocaine-induced cardiomyopathy, intracranial bleeding, and ischemic stroke.^[18]

Alcohol use (both recent and long-term heavy drinking) is an important cause of ischemic stroke in the young. The main mechanisms of alcohol association with stroke are cardiac arrhythmias as well as effects on hemostasis, fibrinolysis, and blood clotting.^[19] Combining alcohol with cocaine leads to the formation of a pharmacologically active substance in the body known as cocaethylene. This substance is stronger than either alcohol or cocaine separately. Cocaethylene raises the risk of stroke due to its longer plasma elimination half-life.^[20,21] In our patient, using alcohol along with cocaine may have triggered the stroke.

The treatment of confirmed acute thrombotic or thromboembolic stroke induced by cocaine abuse is to establish reperfusion thrombolytic therapy rapidly within the standard window of time.^[22] Computerized tomography or magnetic resonance imaging (MRI) diffusion and perfusion-weighted imaging should be obtained prior to such a decision to assess the ischemic penumbra and identify threatened but salvageable tissue that might benefit from thrombolysis or thrombectomy.^[23] In two published reports, intra-arterial thrombolysis and aspiration were successfully performed in patients with basilar artery thrombosis induced by cocaine. In both case reports, the

patients were young, had no reported significant medical history, and were not comatose at the initial presentation. In addition, there was no early hemorrhagic conversion seen in the brain images. In such patients, intra-arterial thrombolysis with or without mechanical thrombectomy can be considered as a therapeutic option.^[24,25] In our case, due to the late presentation, further endovascular interventions were not offered.

Conclusion

Cocaine abuse is a significant health hazard with multiple cardiac and neurological complications. Several pathophysiological mechanisms for cocaine-induced ischemic stroke have been implicated, including triple reuptake inhibitor with subsequent massive sympathetic overactivity. Cocaine use should be routinely suspected in young patients presenting with ischemic stroke, and a urine toxicology screen should be part of the initial workup for such patients. Brain MRI is an essential neuroimaging modality, which is very helpful in confirming the ischemic insult and planning management. Early diagnosis and treatment are crucial due to potential reversibility and reduction of the size of infarcted tissue. In addition, multidisciplinary care, including a vascular neurosurgeon should be implicated.

Financial support and sponsorship

Nil.

Conflicts of interest

There are no conflicts of interest.

References

- Esse K, Fossati-Bellani M, Traylor A, Martin-Schild S. Epidemic of illicit drug use, mechanisms of action/addiction and stroke as a health hazard. *Brain Behav* 2011;1:44-54.
- Nanda A, Vannemreddy P, Willis B, Kelley R. Stroke in the young: relationship of active cocaine use with stroke mechanism and outcome. *Acta Neurochir Suppl* 2006;96:91-6.
- Narvaez JC, Magalhães PV, Fries GR, Colpo GD, Czepielewski LS, Vianna P, *et al.* Peripheral toxicity in crack cocaine use disorders. *Neurosci Lett* 2013;544:80-4.
- Talarico GP, Crosta ML, Giannico MB, Summaria F, Calò L, Patrizi R. Cocaine and coronary artery diseases: A systematic review of the literature. *J Cardiovasc Med (Hagerstown)* 2017;18:291-4.
- Sharma T, Kumar M, Rizkallah A, Cappelluti E, Padmanabhan P. Cocaine-induced thrombosis: Review of predisposing factors, potential mechanisms, and clinical consequences with a striking case report. *Cureus* 2019;11:e4700.
- Kim ST, Park T. Acute and chronic effects of cocaine on cardiovascular health. *Int J Mol Sci* 2019;20:E584.
- De Giorgi A, Fabbian F, Pala M, Bonetti F, Babini I, Bagnaresi I, *et al.* Cocaine and acute vascular diseases. *Curr Drug Abuse Rev* 2012;5:129-34.
- Dinis-Oliveira RJ. Metabolomics of cocaine: Implications in toxicity. *Toxicol Mech Methods* 2015;25:494-500.
- Enevoldson TP. Recreational drugs and their neurological

- consequences. *J Neurol Neurosurg Psychiatry* 2004;75 Suppl 3:i9-15.
10. Ryan SA. Cocaine use in adolescents and young adults. *Pediatr Clin North Am* 2019;66:1135-47.
 11. Sordo L, Indave BI, Barrio G, Degenhardt L, de la Fuente L, Bravo MJ. Cocaine use and risk of stroke: A systematic review. *Drug Alcohol Depend* 2014;142:1-13.
 12. Bhattacharya P, Taraman S, Shankar L, Chaturvedi S, Madhavan R. Clinical profiles, complications, and disability in cocaine-related ischemic stroke. *J Stroke Cerebrovasc Dis* 2011;20:443-9.
 13. Brust JC, Richter RW. Stroke associated with cocaine abuse? *N Y State J Med* 1977;77:1473-5.
 14. Treadwell SD, Robinson TG. Cocaine use and stroke. *Postgrad Med J* 2007;83:389-94.
 15. Merenda A, Muir KW, Koch S. Cracking the role of cocaine in stroke. *Stroke* 2016;47:909-10.
 16. Fonseca AC, Ferro JM. Drug abuse and stroke. *Curr Neurol Neurosci Rep* 2013;13:325.
 17. Yoon SH, Zuccarello M, Rapoport RM. Acute cocaine induces endothelin-1-dependent constriction of rabbit basilar artery. *Endothelium* 2007;14:137-9.
 18. Sharma HS, Muresanu D, Sharma A, Patnaik R. Cocaine-induced breakdown of the blood-brain barrier and neurotoxicity. *Int Rev Neurobiol* 2009;88:297-334.
 19. Munsat TL, Mancall EL, DesLauriers MP. The AAN launches a new education program: CONTINUUM lifelong learning in neurology. *Neurology* 1994;44:771-2.
 20. Jones AW. Forensic drug profile: Cocaethylene. *J Anal Toxicol* 2019;43:155-60.
 21. Farooq MU, Bhatt A, Patel M. Neurotoxic and cardiotoxic effects of cocaine and ethanol. *J Med Toxicol* 2009;5:134-8.
 22. Catanese L, Tarsia J, Fisher M. Acute ischemic stroke therapy overview. *Circ Res* 2017;120:541-58.
 23. Montoya-Filardi A, Mazón M. The addicted brain: Imaging neurological complications of recreational drug abuse. *Radiologia* 2017;59:17-30.
 24. Alqahtani SA, Burger K, Potolicchio S. Cocaine-induced acute fatal basilar artery thrombosis: Report of a case and review of the literature. *Am J Case Rep* 2015;16:393-7.
 25. Vidale S, Peroni R, Di Palma F, Sampietro A, Gozzi G, Arnaboldi M. Intra-arterial thrombolysis in a young patient with cocaine-associated stroke. *Neurol Sci* 2014;35:1465-6.