

## Calcifying Pseudoneoplasms of the Neuraxis: Not Only Surgical Treatment

Sir,

Calcifying pseudotumor is a rare nonneoplastic lesion of the spine. The etiology is unknown. It is probably the result of an excessive inflammatory response.<sup>[1]</sup> A recent extensive review of the literature put together 59 patients between 1977 and 2016. All patients were treated surgically. The follow-up is not homogeneous, and a clear analysis of morbidity and outcome is difficult.<sup>[2]</sup> Nevertheless, even though surgical excision has a good prognosis,<sup>[3]</sup> it is not the only kind of treatment. Kwan *et al.*<sup>[4]</sup> reported thoracic calcifying pseudoneoplasms of the neuraxis (CPN) in a 48-year-old man, which resolved symptomatically and on imaging after treatment with oral indomethacin 25 mg three times daily. The symptoms improved dramatically after only 3 days after the initiation of therapy, and magnetic resonance imaging showed complete disappearance of the lesion following 16 weeks of treatment. The choice of this anti-inflammatory drug depends by its ability to block the prostaglandin PGE<sub>2</sub>, a correlated agent with the mechanism of heterotopic ossification.<sup>[5,6]</sup>

In our department, we had the same results with indomethacin protocol of Kwan.

A 44-year-old woman presented with a history of dorsal spinal pain which radiated to the right medium thoracic region for 2 months. The pain and the sleep disturb of the patient were resistant to medical treatment. Clinical history was evident of presence of smoking and seropositivity to hepatitis C virus and absence of history of spinal trauma.

Laboratory tests demonstrated that complete blood count and liver and inflammatory indexes were normal. The

patient's neurological status was normal without motor or sensory deficit. Computed tomography (CT) scan showed a right preforaminal extradural lesion of 7 mm located upper posterior to the T6–T7 disc. The lesion was isodense with a calcified rim [Figure 1]. On MRI [Figure 2], the lesion showed hypointense signal on T1- and T2-weighted images, and the sagittal reconstruction showed a clear separation between the lesion and the T6–T7 disc. On such radiological finding and after a deep literature review, we postulated a diagnosis of thoracic CPN. Due to the absence of neurological deficits or sign of myelopathy, Kwan indomethacin protocol was started, associated with gastro-protective medical therapy. After 2 weeks from the beginning of the treatment, the patient showed complete recovery of the symptoms. At the end of this therapy, a new dorsal CT and MRI were performed. Both studies showed the total disappearance of the lesion [Figures 3 and 4].

Indomethacin treatment could be a viable alternative to surgical treatment. In some spinal district, like the thoracic segment, surgical resection could be challenging,

Moreover, despite a very low rate of recurrence, surgical treatment of the spinal CPN has a quite high rate of subtotal resection (51%, 14/27 cases according to the review by Duque *et al.*<sup>[2]</sup>) due to this review.

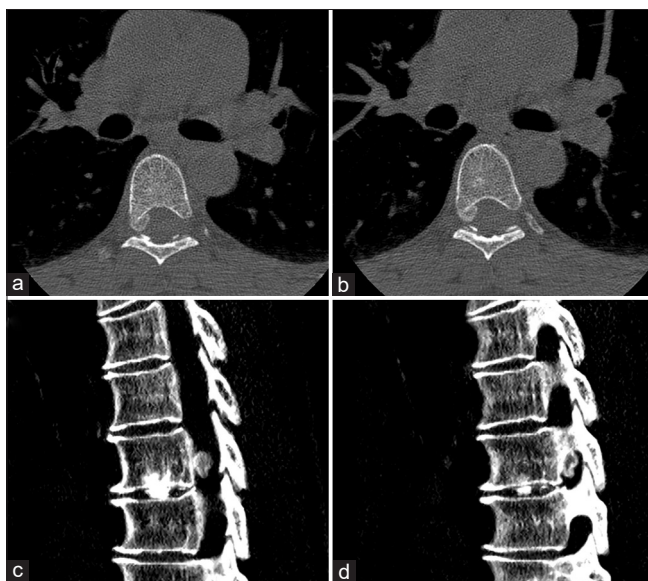


Figure 1: First computed tomography scan showing the presence of a calcifying lesion in the thoracic spinal canal and its relationship with the right foramen, in the axial plane (a and b) and in the sagittal plane (c and d)

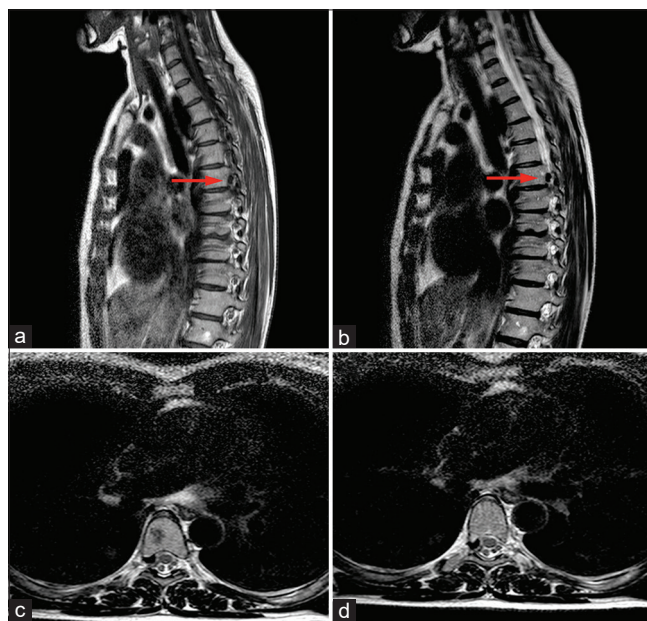
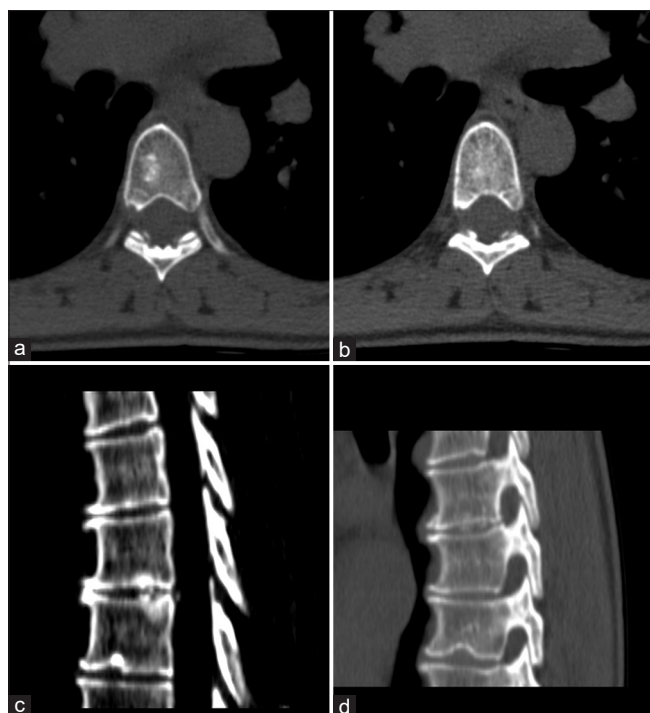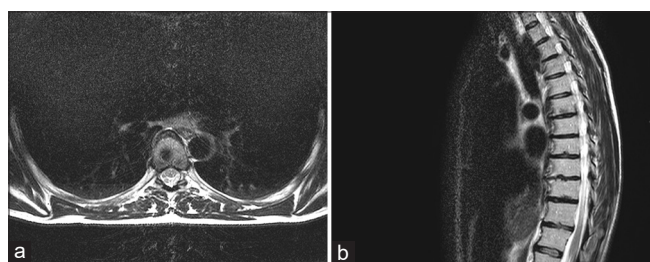


Figure 2: Magnetic resonance imaging study before the initiation of the therapy. The lesion showed hypointense signal on T1-weighted images (a) and on T2-weighted images (b, sagittal plane and c and d, axial plane). The sagittal reconstruction showed a clear separation between the lesion and the T6–T7 disc (red arrow)



**Figure 3:** Computed tomography-scan performed at the end of the therapy, in the axial (a and b) and sagittal (c and d) reconstruction, showed the completely disappearance of the calcifying pseudoneoplasm



**Figure 4:** Spinal magnetic resonance imaging after the indomethacin-protocol: Axial (a) and sagittal (b) reconstructions showed the disappearance of the lesion

### Financial support and sponsorship

Nil.

### Conflicts of interest

There are no conflicts of interest.

**Andrea Boschi<sup>1</sup>, Antonio Pisano<sup>1,2</sup>,  
Stefano Romoli<sup>2</sup>**

<sup>1</sup>Department of Neurosurgery, Careggi University Hospital,

<sup>2</sup>Neuromusculoskeletal Department, Spine Surgery Unit, Careggi University Hospital, Largo Palagi, 1-50139 Florence, Italy

### Address for correspondence:

Dr. Antonio Pisano,

Department of Neurosurgery, Careggi University Hospital,  
Largo Palagi 1, 50139, Florence, Italy.

Department of Neuromusculoskeletal, Spine Surgery Unit, Careggi University Hospital, Largo Palagi 1, 50139, Florence, Italy.

E-mail: antonio.pisano91@gmail.com

### References

- Bertoni F, Unni KK, Dahlin DC, Beabout JW, Onofrio BM. Calcifying pseudoneoplasms of the neural axis. *J Neurosurg* 1990;72:42-8.
- Duque SG, Lopez DM, de Méndivil AO, Fernandez JD. Calcifying pseudoneoplasms of the neuraxis: Report on four cases and review of the literature. *Clin Neurol Neurosurg* 2016;143:116-20.
- Song SY, Ahn SY, Rhee JJ, Lee JW, Hur JW, Lee HK. Three cases of calcifying pseudoneoplasm which involve the epidural space of the Spine. *Korean J Spine* 2015;12:235-8.
- Kwan MK, Abdelhai AM, Saw LB, Chan CY. Symptomatic calcifying pseudotumor of the thoracic spine that resolved with the indomethacin treatment: A case report. *Spine (Phila Pa 1976)* 2012;37:E1676-9.
- Schurch B, Capaul M, Vallotton MB, Rossier AB. Prostaglandin E2 measurements: Their value in the early diagnosis of heterotopic ossification in spinal cord injury patients. *Arch Phys Med Rehabil* 1997;78:687-91.
- Teasell RW, Mehta S, Aubut JL, Ashe MC, Sequeira K, Macaluso S, *et al.* A systematic review of the therapeutic interventions for heterotopic ossification after spinal cord injury. *Spinal Cord* 2010;48:512-21.

This is an open access journal, and articles are distributed under the terms of the Creative Commons Attribution-NonCommercial-ShareAlike 4.0 License, which allows others to remix, tweak, and build upon the work non-commercially, as long as appropriate credit is given and the new creations are licensed under the identical terms.

Access this article online	
<b>Quick Response Code:</b> 	<b>Website:</b> <a href="http://www.asianjns.org">www.asianjns.org</a>
	<b>DOI:</b> 10.4103/ajns.AJNS_113_20

**How to cite this article:** Boschi A, Pisano A, Romoli S. Calcifying pseudoneoplasms of the neuraxis: Not only surgical treatment. *Asian J Neurosurg* 2020;15:796-7.

**Submission:** 25-Mar-2020

**Revised:** 24-Jun-2020

**Accepted:** 09-Jul-2020

**Published:** 28-Aug-2020

© 2020 Asian Journal of Neurosurgery | Published by Wolters Kluwer - Medknow