

A True Mimicker to Plasmacytoma Clinically, Radiologically, and Pathologically – A Rare Case Report

Abstract

Lympho plasmacytoma is distinct type of diffuse large B cell lymphoma predominantly seen in HIV-positive patients. The diagnosis of lympho plasmacytoma could be a challenge due to its overlapping characterizes with those of myeloma and lymphoma. We report a case of a 50-year-old man who initially presented with a painful solitary destructive lesion at the second lumbar vertebra. Clinico-pathological findings were consistent with a solitary plasmacytoma, and he was treated with definitive radiotherapy. Eight months after completing radiotherapy, he was found to have similar lesions at D4 vertebral body, multiple ribs, and pelvis. Subsequent biopsy confirmed lympho plasmacytoma. Because of its rarity and heterogeneous presentations, lympho plasmacytoma could easily be overlooked clinically and pathologically in immunocompetent patients. The diagnosis of lympho plasmacytoma should be considered when there is coexpression of myeloma and lymphoma immune markers.

Keywords: *Lympho plasmacytoma, lymphoma, myeloma, solitary plasmacytoma*

Introduction

Lympho plasmacytoma is distinct type of diffuse large B cell lymphoma (DLBCL) predominantly seen in HIV-positive patients.^[1] The diagnosis of lympho plasmacytoma could be a challenge due to its overlapping characterizes with those of myeloma and lymphoma. Because of its rarity, no standard management strategy has been established. A review by Morscio *et al.* showed a median overall survival (OS) of 8 months. It also revealed HIV-negative patients have slightly better OS (11 months) compared with HIV-positive patients (10 months).^[2] HIV-negative lympho plasmacytoma has found to have similar lesions at D4 vertebral body, multiple ribs, and pelvis. He was treated been shown to affect a relatively higher proportion of female patients in contrast to HIV-positive patients. The median age of HIV-negative lympho plasmacytoma patients was 55 years.^[3] Lympho plasmacytoma in immunocompetent patients appeared to be more heterogeneous in terms of sites of involvement.^[3] We describe an HIV-negative case of lympho plasmacytoma who initially appeared to

have solitary plasmacytoma. Eight months later, he was with chemotherapy and immunotherapy combinations.

Materials and Methods

Case report of mimicking presentation of lympho plasmacytoma as plasmacytoma in Indo American Hospital, Vaikom on October 2019; was recorded. Clinical presentation, radiological features, extent of resection, and management were noted. Management after surgical intervention is done after discussing it with our Oncologist.

Case Report

A middle-aged previously healthy man initially presented with 2 months history of left-sided sciatica-like pain. The pain then progressed to involve lower back. He did not have any bowel or bladder symptoms. His HIV status was negative. The initial computed tomography (CT) of lumbar spine showed a lytic lesion involving the left half of L2 vertebral body and pedicle. Subsequent magnetic resonance imaging (MRI) of lumbosacral spine demonstrated T1 hypo, T2 isointense contrast-enhancing L2 vertebral body lesion involving the left half

**Shino P. Ashly,
Anu C. Thomas,
Sajeev S.
Vadakkedam**

*Department of Neurosurgery,
Indo American Hospital,
Vaikom, Kerala, India*

Address for correspondence:

*Dr. Shino P. Ashly,
Department of Neurosurgery,
Indo American Hospital,
Vaikom, Kerala, India.
E-mail: shinoashly@gmail.com*

Access this article online

Website: www.asianjns.org

DOI: 10.4103/ajns.AJNS_116_21

Quick Response Code:



This is an open access journal, and articles are distributed under the terms of the Creative Commons Attribution-NonCommercial-ShareAlike 4.0 License, which allows others to remix, tweak, and build upon the work non-commercially, as long as appropriate credit is given and the new creations are licensed under the identical terms.

For reprints contact: WKHLRPMedknow_reprints@wolterskluwer.com

How to cite this article: Ashly SP, Thomas AC, Vadakkedam SS. A true mimicker to plasmacytoma clinically, radiologically, and pathologically – A rare case report. *Asian J Neurosurg* 2021;16:841-5.

Submitted: 17-Mar-2021 **Accepted:** 16-Jul-2021

Published: 18-Dec-2021

of body and left pedicle [Figures 1 and 2]. He proceeded to have posterior spinal fixation with lateral extracavitary approach (LECA) cage fusion and surgical decompression of the lesion. Intraoperatively lesion was fleshy, fibrous, and highly vascular. The histopathological diagnosis was plasmacytoma [Figure 3]. Immunophenotyping showed positive staining for CD138 with high MIB1 index. Bone marrow aspirate showed no increased plasma cells, no clonality, and normal cytogenetics. Capillary serum electrophoresis and serum-free light chains did not demonstrate a paraprotein or light chain excess. The full blood count was within the normal range. The myeloid markers were negative and a diagnosis of plasmacytoma was made.

He received 45 Gy in 25 fractions of radical radiotherapy to the L2 region. His back pain and sciatica completely resolved after the radiotherapy and his follow-up imagings showed good position of implants [Figure 4].

Six months after completing radiotherapy (8 months since initial diagnosis), he developed acute onset of numbness and weakness of both lower limbs for 2 days along with

bladder symptoms. Clinically, he had D6 myelopathy. His CT of the thoracic spine showed a lytic lesion with collapse of T4 vertebral body [Figure 5]. MRI of the spine demonstrated T1 hypo, T2 iso intense contrast-enhancing lesion involving D4 vertebral body with collapse, and anterior epidural soft-tissue component causing spinal cord compression [Figure 6]. He also had multiple contrast-enhancing lesions in pelvic bones and few ribs. His repeated myeloma workups and lab reports were negative. Oncology consultation made and they reported possibility of multiple myeloma, and advised biopsy. As the patient had progressive neurological deficits, we decided to operate and decompress the lesion. He underwent posterior spinal fixation with LECA cage fusion and surgical decompression. Intraoperatively lesion was fleshy, fibrous, and highly vascular.

Biopsy report from the D4 lesion from one nationally accredited center was plasmacytoma, and we were planned for adjuvant radiotherapy as like the previous lesion. However, biopsy report from another nationally accredited center was suggestive of malignant lymphoproliferative disorder with B cell predominance [Figure 7]. The following markers showed positive immunostaining: CD138, CD20, CD3, and was negative for CD56. Lesion was with high

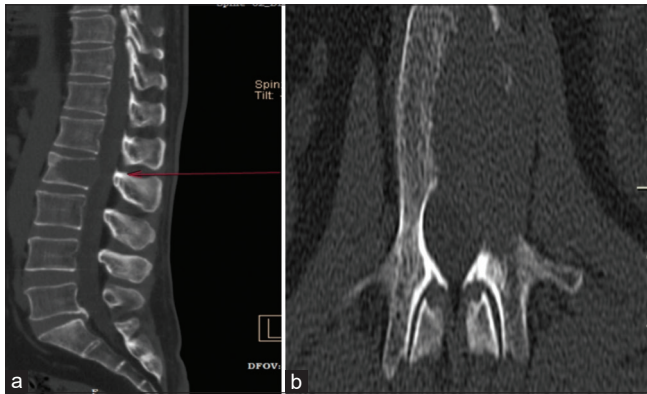


Figure 1: Sagittal (a) and axial (b) section of computed tomography reveals- lytic lesion involving the left half of L2 vertebral body and pedicle

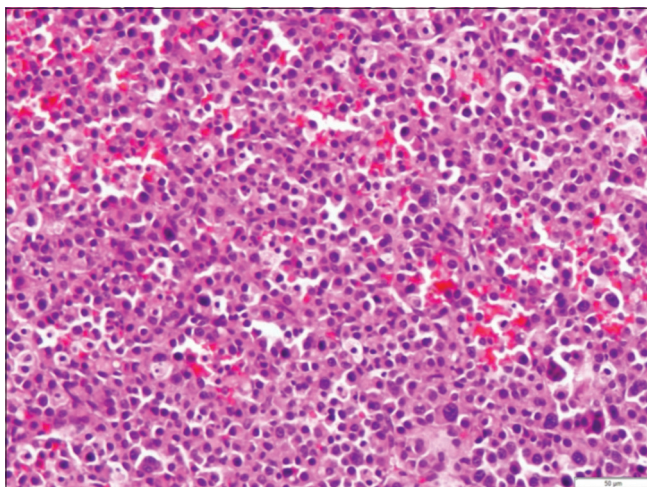


Figure 3: Histopathological examination of surgical specimen, after first surgery revealing plasmacytoma

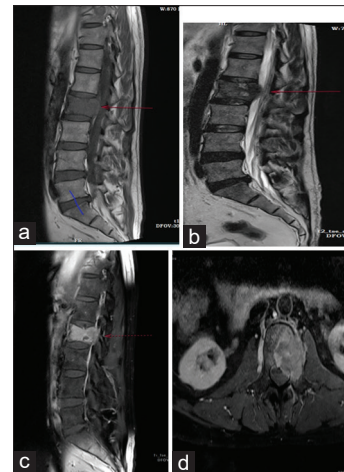


Figure 2: Sagittal section of T1 magnetic resonance imaging (a), T2 (b) with Gadolinium contrast (c) and post contrast axial (d) magnetic resonance imaging reveals- a T1 hypo, t2 iso intense contrast enhancing L2 vertebral body lesion involving left half of body and left pedicle

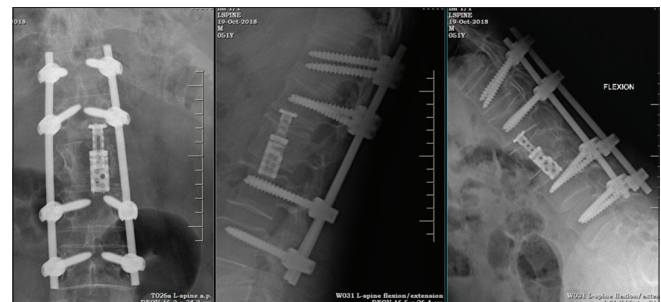


Figure 4: Postoperative X-ray after first surgery

MIB-1 labeling. Expert anatomical pathology opinion was that the features were consistent with aggressive B-cell lymphoma, most likely lympho plasmacytoma.

After the second histopathology report, his adjuvant therapy plan changed from radiotherapy to chemotherapy. He was treated with different chemotherapy and immunotherapy combinations and got symptomatic improvement. On the latest review, he got complete neurologic recovery and he was disease-free for the past 2 years. His imagings show good position of implants [Figure 8].

Discussion

Lympho plasmacytoma is a rare type of high-grade lymphoma frequently involving extranodal sites. HIV-negative lympho plasmacytoma patients are known to present with relatively advanced clinical stage with B symptoms, and less common bone marrow involvement than in HIV-positive patients.^[3] Our patient initially presented like a typical solitary plasmacytoma. The fragmented histology sample taken from laminectomy procedure favored plasma cell neoplasm. However, it

may due to extensive crush artifacts and necrosis made it difficult to recognize lymphoma-related histological features. Therefore, we should highlight the importance to obtain adequate tissue samples to facilitate accurate diagnosis. After the confirmation of lympho plasmacytoma on the second biopsy (D4 lesion), the sample taken from L2 lesion was compared. Both specimens showed identical histological and immunological features, which confirmed same pathological process. One of the important differential diagnoses for lympho plasmacytoma is plasmablastic myeloma.^[4] Differential diagnosis consideration for lympho plasmacytoma includes a wide range of other lymphoid tumors^[1,4] with immunoblastic, plasmablastic or plasmacytic or immunoblastic appearances, such as DLBCL with plasmacytic differentiation, plasmablastic myeloma, and solitary plasmacytoma. A comparison between lympho plasmacytoma and plasmacytoma in clinical features, morphology, and immunophenotype is listed in the table [Figure 9].

The absence of bone marrow involvement or hypercalcemia/renal dysfunction in our patient makes plasmablastic

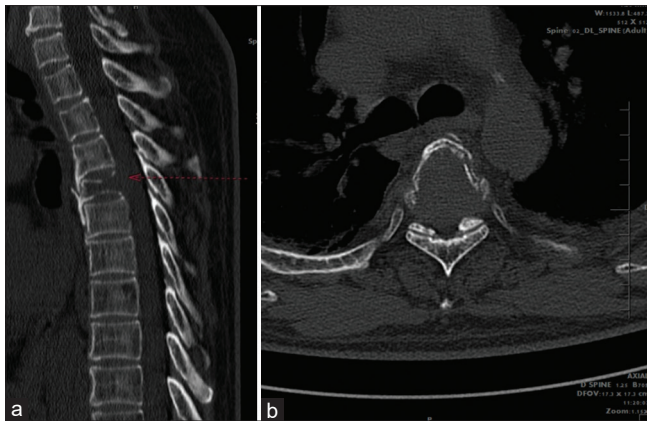


Figure 5: Sagittal (a) and axial (b) section of computed tomography reveals- lytic lesion with collapse of D4

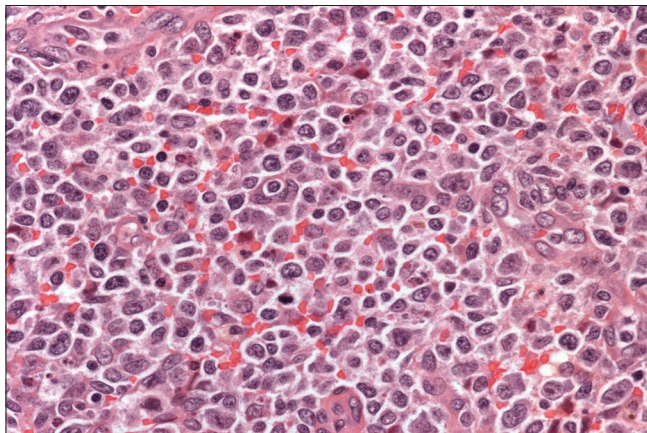


Figure 7: Histopathological examination of surgical specimen, after second surgery revealing malignant lymphoproliferative disorder with B cell predominance

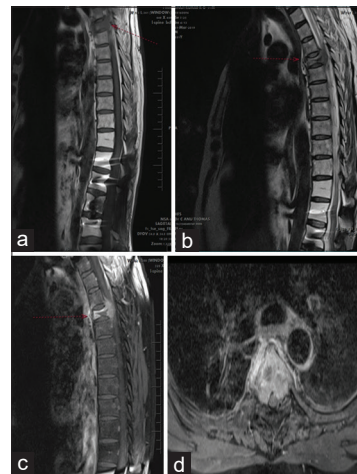


Figure 6: Sagittal section of T1 magnetic resonance imaging (a), T2 (b), with Gadolinium contrast (c) and post contrast axial (d) magnetic resonance imaging reveals a- T1 hypo, t2 iso intense Contrast enhancing D4 vertebral body lesion with collapse, and anterior epidural soft tissue component causing spinal cord compression

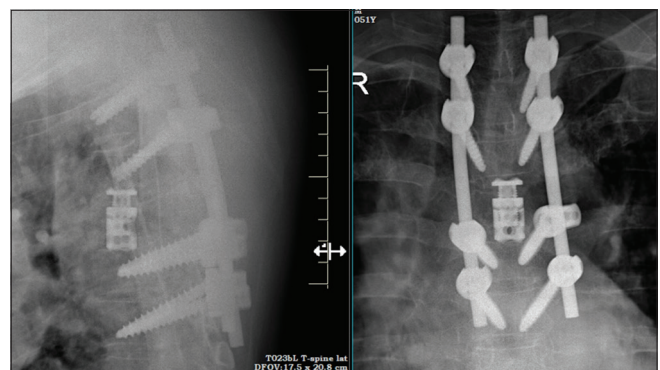


Figure 8: Postoperative X-ray after second surgery

Lympho Plasmacytoma	Plasmacytoma
Plasmacells mixed with lymphocytes	Uniform plasma cells
Mainly immunocompromised person	Affects immunocompromised and immunocompetant person
EBV + (60%)	EBV -
Scattered CD 138+ cells	Uniform CD 138+ cells
CD 19+,CD 20+,CD 45+	Negative
Negative	CD 56+
Primary Treatment- Chemotherapy BRD, CVP	Primary Treatment- Radiotherapy
Aggressive –Mortality with out treatment 80-90%	Less aggressive
EBV- Epstein Barr virus BRD- Bortizomib,Rituximab and dexamethason CVP- Cyclophosphamide,Vincristine and prednisolone	

Figure 9: Difference between lympho plasmacytoma and plasmacytoma

myeloma an unlikely diagnosis. In 2010, Castillo *et al.*^[5] conducted a systematic review of 76 cases of HIV-negative lympho plasmacytoma with predominately extraoral locations and reported a median survival time of 9 months and 2-year OS of only 10%. Liu *et al.*^[6] reviewed eight cases of HIV-negative patients with lympho plasmacytoma who underwent chemotherapy and reported complete response in seven cases. There is no well-established treatment regimen for lympho plasmacytoma due to its rarity. Cyclophosphamide, hydroxydaunorubicin, oncovin, and prednisolone (CHOP) is considered a suboptimal treatment option and the National Comprehensive Cancer Network guideline recommends more aggressive therapy.^[7] One of the treatment options for patients with HIV-associated lympho plasmacytoma is bortezomib alone or in combination with CHOP.^[8,9] Another alternative is Bortizomib, Rituximab, and dexamethasone and cyclophosphamide, vincristine, and prednisolone.^[10] The role of intrathecal chemotherapy as the central nervous system (CNS) prophylaxis was not well studied. In view of frequent extranodal site involvement and aggressive natural history of disease, CNS prophylaxis was justified by some authors.^[3]

Given the unfavorable outcome of lympho plasmacytoma and expression of myeloma markers, clinicians frequently try agents that are not a standard component of lymphoma management but are routinely used in the treatment of multiple myeloma. Proteasome inhibitors have been used in lympho plasmacytoma with variable response.^[8,11,12] The second lines of treatment include gemcitabine, lenalidomide, and vinorelbine. Lenalidomide based-chemotherapy has been shown to achieve good response in lympho plasmacytoma.^[13-15] However, lenalidomide alone was seldom used in lympho plasmacytoma. Interestingly, there are few case reports that have described dramatic response to single-agent lenalidomide in lympho plasmacytoma.^[16,17] Nivolumab is a programmed cell death protein 1 inhibitor

that has shown anticancer activity in relapsed hematological malignancies.^[18]

Conclusions

Coexpression of myeloma and lymphoma markers should raise the suspicion of lympho plasmacytoma in any patient. The case emphasizes the need for obtaining adequate tissue samples to facilitate accurate diagnosis on the first instance.

Declaration of patient consent

The authors certify that they have obtained all appropriate patient consent forms. In the form the patient(s) has/have given his/her/their consent for his/her/their images and other clinical information to be reported in the journal. The patients understand that their names and initials will not be published and due efforts will be made to conceal their identity, but anonymity cannot be guaranteed.

Financial support and sponsorship

Nil.

Conflicts of interest

There are no conflicts of interest.

References

1. Swerdlow SH. WHO Classification of Tumours of Haematopoietic and Lymphoid Tissues. 4th ed. Lyon: IARC; 2017.
2. Morscio J, Dierickx D, Nijs J, Verhoef G, Bittoun E, Vanoeteren X, *et al.* Clinicopathologic comparison of plasmablastic lymphoma in HIV-positive, immunocompetent, and posttransplant patients: Single-center series of 25 cases and meta-analysis of 277 reported cases. *Am J Surg Pathol* 2014;38:875-86.
3. Castillo JJ, Bibas M, Miranda RN. The biology and treatment of plasmablastic lymphoma. *Blood* 2015;125:2323-30.
4. Harmon CM, Smith LB. Plasmablastic lymphoma: A review of clinicopathologic features and differential diagnosis. *Arch Pathol Lab Med* 2016;140:1074-8.
5. Castillo JJ, Winer ES, Stachurski D, Perez K, Jabbour M, Milani C, *et al.* HIV-negative plasmablastic lymphoma: Not in the mouth. *Clin Lymphoma Myeloma Leuk* 2011;11:185-9.
6. Liu JJ, Zhang L, Ayala E, Field T, Ochoa-Bayona JL, Perez L, *et al.* Human immunodeficiency virus (HIV)-negative plasmablastic lymphoma: A single institutional experience and literature review. *Leuk Res* 2011;35:1571-7.
7. Guidelines Version NCCN, 2014. AIDS-Related B-Cell lymphomas. Available from: http://www.nccn.org/professionals/physician_gls/pdf/nhl.pdf. [Last accessed on 2014 Sep 18].
8. Bibas M, Grisetti S, Alba L, Picchi G, Del Nonno F, Antinori A. Patient with HIV-associated plasmablastic lymphoma responding to bortezomib alone and in combination with dexamethasone, gemcitabine, oxaliplatin, cytarabine, and pegfilgrastim chemotherapy and lenalidomide alone. *J Clin Oncol* 2010;28:e704-8.
9. Fernandez-Alvarez R, Gonzalez-Rodriguez AP, Rubio-Castro A, Gonzalez ME, Payer AR, Alonso-Garcia A, *et al.* Bortezomib plus CHOP for the treatment of HIV-associated plasmablastic lymphoma: Clinical experience in three patients. *Leuk Lymphoma* 2016;57:463-6.

10. Noy A, Lensing SY, Moore PC, Gupta N, Aboulafia D, Ambinder R, *et al.* Plasmablastic lymphoma is treatable in the HAART era. A 10 year retrospective by the AIDS Malignancy Consortium. *Leuk Lymphoma* 2016;57:1731-4.
11. Cao C, Liu T, Zhu H, Wang L, Kai S, Xiang B. Bortezomib-contained chemotherapy and thalidomide combined with CHOP (Cyclophosphamide, Doxorubicin, Vincristine, and Prednisone) play promising roles in plasmablastic lymphoma: A case report and literature review. *Clin Lymphoma Myeloma Leuk* 2014;14:e145-50.
12. Castillo JJ, Reagan JL, Sikov WM, Winer ES. Bortezomib in combination with infusional dose-adjusted EPOCH for the treatment of plasmablastic lymphoma. *Br J Haematol* 2015;169:352-5.
13. Schmit JM, DeLaune J, Norkin M, Grosbach A. A case of plasmablastic lymphoma achieving complete response and durable remission after lenalidomide-based therapy. *Oncol Res Treat* 2017;40:46-8.
14. Yanamandra U, Sahu KK, Jain N, Prakash G, Saikia U, Malhotra P. Plasmablastic lymphoma: Successful management with CHOP and lenalidomide in resource constraint settings. *Ann Hematol* 2016;95:1715-7.
15. Pretscher D, Kalisch A, Wilhelm M, Birkmann J. Refractory plasmablastic lymphoma - A review of treatment options beyond standard therapy. *Ann Hematol* 2017;96:967-70.
16. Carras S, Regny C, Peoc'h M, Gervasoni J, Gressin R, Cahn JY, *et al.* Dramatic efficacy of low dose lenalidomide as single agent in a patient with refractory gastric non-human immunodeficiency virus-associated plasmablastic lymphoma. *Leuk Lymphoma* 2015;56:2986-8.
17. Sher T, Miller KC, Lee K, Chanan-Khan A. Remission induction with lenalidomide alone in a patient with previously untreated plasmablastic myeloma: A case report. *Clin Lymphoma Myeloma* 2009;9:328-30.
18. Lesokhin AM, Ansell SM, Armand P, Scott EC, Halwani A, Gutierrez M, *et al.* Nivolumab in patients with relapsed or refractory hematologic malignancy: Preliminary results of a phase Ib study. *J Clin Oncol* 2016;34:2698-704.