

## Effect of Mannitol Irrigation on Brain Edema in a Live Rat Model

### Abstract

**Background:** Mannitol has been used intravenously for decreasing cerebral edema since decades. The study was performed to evaluate the effect of its irrigation on edema in live rats. Edema was induced by artificial brain injury. We hereby present our results on the same using live rats and confirm its beneficial effect on reducing edema when used as irrigation. **Aims:** The aim of this study is to evaluate the effect of mannitol irrigation in reducing cerebral edema in rat brain after induction of artificial trauma and to compare the results with standard normal saline irrigation using randomized controlled study. **Settings and Design:** This study was a prospective randomized controlled trial. **Materials and Methods:** A total of 20 fully grown Albino Wistar rats were subjected to artificial trauma after a burr hole and divided randomly into two groups of ten rats each. One group was subjected to mannitol irrigation after durotomy and the other was subjected to normal saline. Tissue biopsy was sent at the end of 1 h to check for the status of edema and was classified into three grades. **Statistical Analysis Used:** Comparison of proportions test. **Results:** Mannitol irrigation produced a statistically significant difference ( $P = 0.022$ ) in the grade of edema at the end of 1 h as compared to normal saline. **Conclusions:** Mannitol irrigation can be used during neurosurgical procedures instead of normal saline to reduce postoperative brain edema.

**Keywords:** Brain edema, mannitol irrigation, rat study, topical mannitol

### Introduction

About 20% mannitol is widely used in clinical practice as a dehydrating agent in cerebral edema. However, because it may lead to hypotension, renal dysfunction, heart failure, electrolyte disturbances, and other side effects, there are certain restrictions to its use in clinical practice.<sup>[1]</sup> When applied topically to the cornea, mannitol has a tissue dehydrating effect.<sup>[2]</sup> Reflexion coefficient of mannitol is 0.9. Parenteral mannitol increases edema in areas of disrupted blood–brain barrier (BBB) and may cause rebound edema. The surgical field is an area of avid BBB disruption. The molecular drawback of parenteral mannitol can be worked to our advantage by using mannitol as an irrigation fluid.<sup>[3]</sup> The aim of the present study was to evaluate this effect of mannitol irrigation on brain edema. The objective was to apply the results in practice and use mannitol irrigation during surgery in humans to reduce postoperative edema.

### Materials and Methods

The study was a prospective randomized controlled trial. The Institutional Animal

This is an open access journal, and articles are distributed under the terms of the Creative Commons Attribution-NonCommercial-ShareAlike 4.0 License, which allows others to remix, tweak, and build upon the work non-commercially, as long as appropriate credit is given and the new creations are licensed under the identical terms.

For reprints contact: reprints@medknow.com

Ethics Committee approval was taken. Twenty fully grown adult Wistar albino rats, weighing between 150 and 250 g, were randomly divided into two groups of ten rats each. Animals that had any visible deformity or decreased activity were not included in the study. Animals were placed prone on a custom-made autoclaved table. Head and body clamps were applied for immobilization [Figure 1]. The animals were anesthetized using intramuscular ketamine (100 mg/kg) plus intraperitoneal ketamine (10 mg/kg) with 23G needles until there was complete immobility on pinprick sensory stimulus. Local incision was infiltrated with standard lignocaine v/w.<sup>[4]</sup> Veterinary backup was available throughout all procedures. With the animal in the prone position and under the effect of anesthesia, a longitudinal incision was taken in the right frontal region. A craniotomy (1 cm × 1 cm) was made in the right frontal region of the skull, leaving the dura mater intact. Animals were subjected to mild traumatic brain injury. A 20 g steel weight was dropped on the craniotomy site through a 10 cm long fiberglass tube<sup>[5]</sup> [Figures 2 and 3]. This trauma has been found to be sufficient to cause mild brain injury in the animal.<sup>[5]</sup> The dura mater was opened in a cruciate fashion thereafter (Video 1).

**How to cite this article:** Velho VL, Bhide AA, Ansari SA. Effect of mannitol irrigation on brain edema in a live rat model. *Asian J Neurosurg* 2018;13:766-8.

Vernon L. Velho,  
Anuj Arun Bhide,  
Sameer A. H. Ansari

Departments of Neurosurgery  
and Pathology, Grant  
Government Medical College  
and Sir JJ Group of Hospitals,  
Mumbai, Maharashtra, India

### Address for correspondence:

Dr. Anuj Arun Bhide,  
Department of Neurosurgery,  
Grant Government Medical  
College and Sir JJ Group  
of Hospitals, Mumbai,  
Maharashtra, India.  
E-mail: anujbhide@yahoo.in

Video available on:  
[www.asianjns.org](http://www.asianjns.org)

### Access this article online

Website: [www.asianjns.org](http://www.asianjns.org)

DOI: 10.4103/ajns.AJNS\_11\_18

### Quick Response Code:



The ten rats from the control group were thereafter irrigated with commercially available standardized normal saline (0.9%), and the ten rats from the test group were irrigated with mannitol (20%). The irrigation fluids were attached to an intravenous set, and 18-gauge intravenous catheter was used to suspend the irrigating fluid over the traumatized brain for 1 h. The flow rate of the irrigant was kept at 8.5 ml/min (i.e. a total of 500 ml irrigation) [Figure 4]. Tissue biopsy of the traumatized area (<3 mm depth) was sent at the end of 1 h. (10% standard formalin solution). The histopathological analysis was taken as benchmark for further calculation (standard hematoxylin and eosin staining). Histopathological analysis was performed by a single observer senior neuropathologist in our hospital. Quantification of the edematous tissue was done into three categories (mild, moderate, and severe) based on the pallor of background, distension of perivascular and pericellular spaces, rarefaction of subpial spaces, the vacuolated appearance of gray matter, pools of protein-rich fluid and sieve-like appearance of myelinated areas.<sup>[6]</sup>

## Results

The results were tabulated as per grades of edema [Table 1 and Figure 5]. Only one rat out of the ten irrigated with mannitol had severe edema at the

end of 1 h in the biopsy, whereas seven rats in the group irrigated with normal saline had severe edema. The tabulated results were tested with “Comparison of Proportions-test (Using SPSS – version 16.0, SPSS Inc, Chicago, USA)” and inference was drawn. Mannitol irrigation reduced brain edema with a statistical significance at the end of 1 h ( $P = 0.022$ ) [Table 2]. Mannitol irrigation produces a statistically significant decrease ( $P = 0.022$ ) in the number of rats having severe edema (Grade 3) after mild traumatic brain injury. Hence, mannitol irrigation may be used intraoperatively during neurosurgical procedures to help reducing postoperative edema due to tissue handling and brain retraction.

## Discussion

The introduction of osmotic agents in the treatment of raised intracranial pressure (ICP) was initiated by experiments of Weed and McKibben in 1919 which showed the ability of intravenous hypertonic solutions to acutely lower ICP. During the 1960s and 1970s, hypertonic urea and glycerol were widely used, but in recent years,

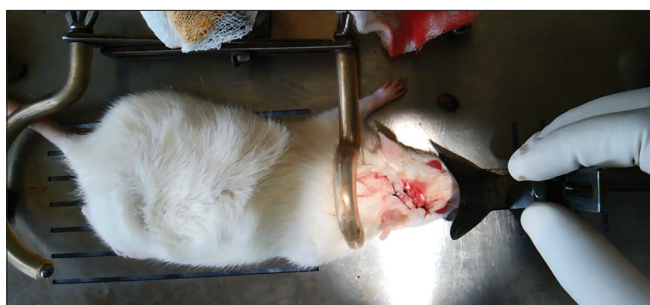

Figure 1: Custom-made autoclave abled table with clamps to position the animal

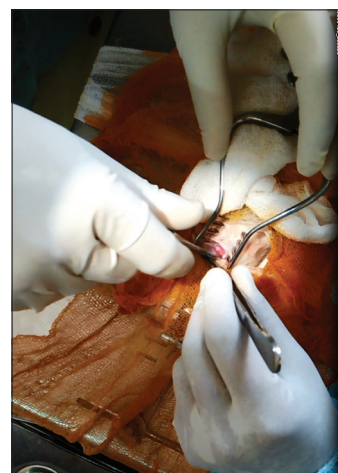

Figure 2: Burr hole being made over the frontal region

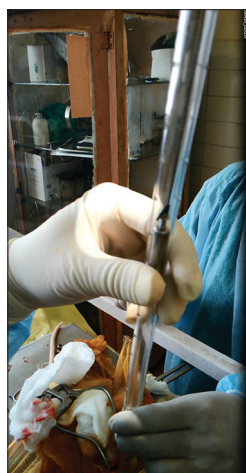

Figure 3: Contusion device for the weight to be dropped at the exact site from the exact height

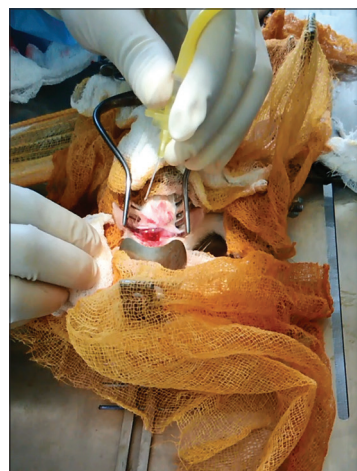

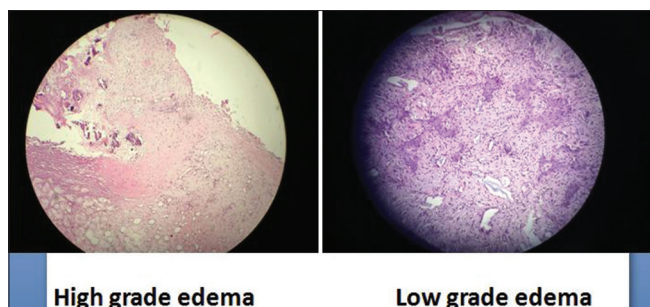
Figure 4: Irrigation fluid being suspended over the site of durotomy

**Table 1: Grades of edema on biopsy after 1 h of irrigation in both groups**

Edema on histopathology	Rats irrigated with mannitol (n=10)			Rats irrigated with normal saline (n=10)		
	Mild	Moderate	Severe	Mild	Moderate	Severe
Number of rats (%)	6 (60)	3 (30)	1 (10)	0	3 (30)	7 (70)

**Table 2: Statistical analysis of grades of edema in test and control group**

	Rats irrigated with mannitol (n=10)	Rats irrigated with normal saline (n=10)	P
Mild edema	6	0	0.014
Moderate edema	3	3	0.66
Severe edema	1	7	0.022



**Figure 5: Illustration of the grade of edema in two cases as analyzed on histopathology**

mannitol has become popular.<sup>[7]</sup> Surgical handling and brain retraction cause damage to the brain, leading to increase in postoperative edema.<sup>[8]</sup> Intravenous mannitol irrigation had the added disadvantage of systemic side effects and rebound phenomenon.<sup>[9]</sup> Since irrigation fluid in neurosurgery is of utmost importance for almost all aspects of surgery such as hemostasis, prevention of desiccation and visibility, irrigation of the surgical field by mannitol can provide an added benefit of reducing postoperative brain edema. Since mannitol draws edema fluid in the vascular space when given intravenously, in theory, it should also draw fluid out into a surgical field when irrigated topically during surgery on the brain. As illustrated in our results, mannitol irrigation reduced brain edema after mild traumatic brain injury which mimics the intraoperative scenario.

## Conclusions

Mannitol irrigation can be used during neurosurgical procedures instead of normal saline to reduce postoperative brain edema.

## Financial support and sponsorship

Nil.

## Conflicts of interest

There are no conflicts of interest.

## References

- Zeng HK, Wang QS, Deng YY, Jiang WQ, Fang M, Chen CB, *et al.* A comparative study on the efficacy of 10% hypertonic saline and equal volume of 20% mannitol in the treatment of experimentally induced cerebral edema in adult rats. *BMC Neurosci* 2010;11:153.
- Nissenson AR, Weston RE, Kleeman CR. Mannitol. *West J Med* 1979;131:277-84.
- Boone MD, Oren-Grinberg A, Robinson TM, Chen CC, Kasper EM. Mannitol or hypertonic saline in the setting of traumatic brain injury: What have we learned? *Surg Neurol Int* 2015;6:177.
- Marshall S, Milligan A, Yates R. Experimental techniques and anaesthesia in the rat and mouse. *ANZCCART Facts sheet, ANZCCART News* 1994;7:1-4.
- Feeney DM, Boyeson MG, Linn RT, Murray HM, Dail WG. Responses to cortical injury: I. Methodology and local effects of contusions in the rat. *Brain Res* 1981;211:67-77.
- Yates AJ, Thelmo W, Pappius HM. Postmortem changes in the chemistry and histology of normal and edematous brains. *Am J Pathol* 1975;79:555-64.
- Kalita J, Ranjan P, Misra UK. Current status of osmotherapy in intracerebral hemorrhage. *Neurol India* 2003;51:104-9.
- Zhong J, Dujovny M, Perlin AR, Perez-Arjona E, Park HK, Diaz FG, *et al.* Brain retraction injury. *Neurol Res* 2003;25:831-8.
- Node Y, Yajima K, Nakazawa S. Rebound phenomenon of mannitol and glycerol: Clinical studies. *No To Shinkei* 1983;35:1241-6.