

Histopathological Pattern and Outcome of Posterior Fossa Tumors in Children and Adults – A 20-Year Experience

Abstract

Context: The postoperative quality and span of life in posterior fossa tumors (PFTs) is complicated by the residual disease, progression, recurrence, disabilities, and mortality. **Aims:** The aim of this study is to analyze the link between histopathological type of tumor and outcome in an ethnic Himalayan population of India. **Settings and Design:** The histopathological records of 410 out of 589 patients were compared with their clinical outcome up to the 1st postoperative year in a single center which amounts to regional epidemiological value of PFTs. **Materials and Methods:** In this observational study, retrospectively postoperative records of 589 PFTs from November 1990 to December 2010 (20 years) were retrieved, scrutinized, and observed. The postoperative records of 410 patients with proved histopathological examination results were included. **Statistical Analysis Used:** The statistical law of variance was applied wherever necessary. **Results:** About 63.2% of 410 operated PFTs were males while females predominated in meningiomas and pineoblastomas. About 31.7% of PFTs were children (below 18 years.). About 54.1% of the cases were histologically malignant. The residual tumors comprised 40.2%, and symptoms of disease progression occurred in 10.9%. The tumor recurrence occurred in 14.3% while 6.0% of the patients developed severe disability. The overall mortality was 11.4% up to the 1st postoperative year, with 18.9% in malignant patients. The first 1-year event-free survival (EFS) for all the patients was 66.0%. While the patients with malignancies had the first 1-year EFS of 47.7%, the histologically benign group had 87.7%. **Conclusion:** The first 1-year postoperative EFS of histologically benign and some malignant PFTs both in children and adults such as pilocytic astrocytomas, ependymomas, and pineoblastomas was much better (87.7%) than other malignant PFTs.

Keywords: Children and adults, histopathology, outcome, posterior fossa tumors

Introduction

The triad of anatomically tight-spaced posterior fossa, presence of biologically active tumor, and obstructive hydrocephalus are the predictors of the worse outcome in PFTs. The posterior fossa of the cranial cavity, limited by the tentorium above, also called infratentorial space, has much smaller space than the rest of the cranial cavity. However, the contents of such a comparably small space are several types of motor and sensory tracts and a number of vital nuclei and reticular formation for the systemic body functions and consciousness in the form of midbrain, pons, and medulla. Also packed are cranial nerves, vascular network with large venous sinuses, changing volume of cerebrospinal fluid (CSF) in the ventricle and cisterns, and prominently visible cerebellar parenchyma with nuclei and

peduncles. Most of the times, the posterior fossa tumors (PFTs) present themselves as an acute emergency following the compression of the brainstem either due to the increase in tumor size, edema, bleed, or obstruction to CSF pathways and herniation. The surgical debulking, to relieve the pressure on the brainstem, though full of risks, is an indispensable mode of management. However, in such a small space, the intraoperative complications and postoperative disease progression owing to residual or recurrence of the lesion worsen the surgical outcome. In 1930, an account of 61 patients of PFTs was published by the most cherished neurosurgeon of the world, Cushing H, claiming fatal outcome in almost all.^[1] The present study emphasizes the significance of histological identification to the surgical outcome.

This is an open access journal, and articles are distributed under the terms of the Creative Commons Attribution-NonCommercial-ShareAlike 4.0 License, which allows others to remix, tweak, and build upon the work non-commercially, as long as appropriate credit is given and the new creations are licensed under the identical terms.

For reprints contact: reprints@medknow.com

How to cite this article: Bhat AR, Wani MA, Kirmani AR. Histopathological pattern and outcome of posterior fossa tumors in children and adults – A 20-year experience. *Asian J Neurosurg* 2020;15:285-92.

Submitted: 29-Apr-2019

Accepted: 12-Mar-2020

Published: 29-May-2020

**Abdul Rashid Bhat,
Muhammed Afzal
Wani,
Altaf Rehman
Kirmani**

*Department of Neurosurgery,
Sher-i-Kashmir Institute of
Medical Sciences, Srinagar,
Jammu and Kashmir, India*

Address for correspondence:

*Dr. Abdul Rashid Bhat,
C/O: B-4, Faculty Quarters,
Department of Neurosurgery,
Sher-i-Kashmir Institute
of Medical Sciences,
Srinagar - 190 011,
Jammu and Kashmir, India.
E-mail: seven_rashid@
rediffmail.com*

Access this article online

Website: www.asianjns.org

DOI: 10.4103/ajns.AJNS_120_19

Quick Response Code:



Materials and Methods

Literally of epidemiological value, this observational study took into account the records of those patients who were treated in the past and did not need to identify themselves to the researchers. Since the study was mainly a compilation of surgical and histopathological records wherein neither institutional review board/ethical approval nor patient consent was required, it provided epidemiological data about the disease and a particular population because the population group is mainly mountain locked, ethnic, and nonmigratory. It benefited the medical and community health census directly. It was conducted on all operated patients of PTFs admitted from November 1990 to December 2010 (20 years) in the division of neurosurgery. The neurosurgical patients are managed with a standard and uniform protocol. Retrospectively records of all the 589 patients of PTFs were retrieved from the files in the medical records department, operation theatre register, outpatient department files, referral clinics, and follow-up files of the supportive departments such as medical and radiation oncology and pathology of this tertiary health-care facility. The information about the patient's biodata, history, examination, basic routine biochemical and hematological investigations, all the imaging (computed tomography [CT], magnetic resonance imaging [MRI]), surgical procedures, intraoperative (frozen/crush) histopathological reports, final histopathological examination reports, postoperative follow-up notes, and imaging records (CT and MRI) up to the first 1 year of only 410 patients were included and recorded. The data were analyzed, compiled, and conclusions drawn. The statistical law of variance was applied wherever necessary.

Results

The results of the study revealed a male predominance of 63.2% (259/410) of the cases in overall PFTs with a M/F ratio of 1.7:1.0 [Table 1]. About 31.7% (130/410) of all the PFTs were found in the children (age = 18 years and below). The most commonly occurring PFTs in children were medulloblastomas (more of a classical variety) (84.7%, 61/72). However, various tumors such as schwannomas (2.9%, 3/102) and meningiomas (2.6%, 1/38) were uncommonly found in children while metastases not at all. The results revealed that the vestibular schwannoma [Figure 1] at the rate of 23.9% (98/410) was the most occurring individual PFT. The most common histopathology of the PFTs was the malignancy occurring in 54.1% (222/410) of the cases [Tables 1 and 2]. The medulloblastoma (histologically classical) was the most common (32.4%, 72/222) malignant PFT. The histological types of PFTs and the 1-year postoperative outcome showed a significant relation. Comparatively, the histologically benign PFTs had only 18.6% (35/188) of the patients left with residual lesions. The symptoms of disease progression were found in 5.1% (5/98) of the patients of vestibular schwannomas and 14.2% (4/28) of hemangioblastomas [Figure 2]. The event-free survival (EFS) of hemangioblastomas was 85.7% (24/28), dermoids 100% (15/15), and epidermoids 88.8% (8/9) [Figure 3] in the 1st postoperative year. The postoperative residual tumor on imaging was found in 70.2% (33/47) of the patients of high-grade astrocytomas, 66.6% (6/9) with metastatic lesions, 62.5% (15/24) with pilocytic astrocytomas, 43.0% (31/72) with medulloblastomas [Figures 4 and 5], and 41.8% (18/43) with ependymomas [Figure 6]. The highest tumor recurrences of 100% (4/4) were noted in malignant

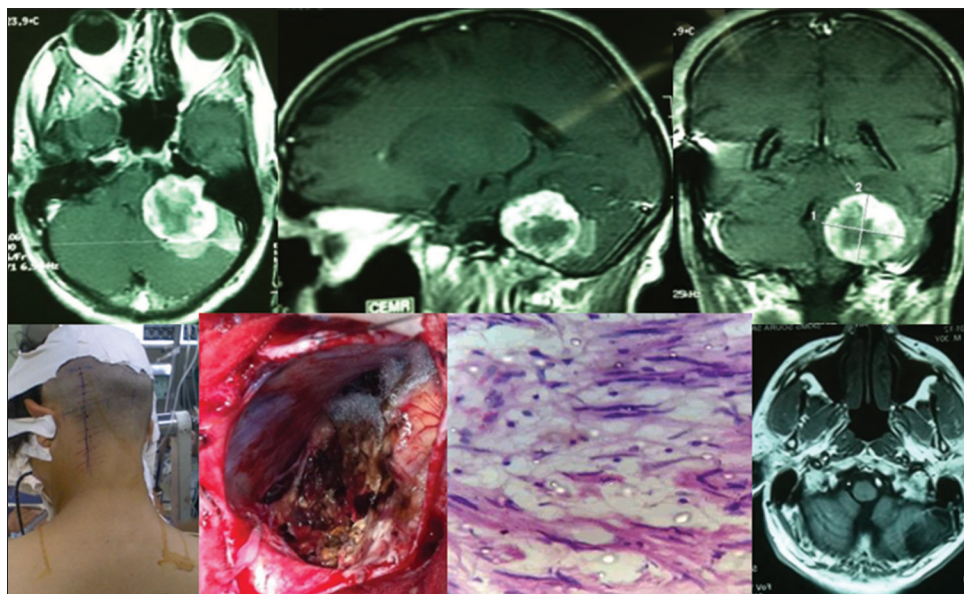


Figure 1: A patient of left cerebello-pontine angle vestibular schwannoma; Intraoperative photos in sitting position and post-operative axial magnetic resonance imaging with histopathological photograph (H and E; $\times 40$)

Table 1: Histopathology, sex, and postoperative outcome in posterior fossa tumors

Serial number	Histopathological type/site	Number of patients	Males	Females	Children (18 years and below)	Postoperative		
						Residual lesion/ disease progression	Recurrence	Mortality
1	Schwannomas	102	63	39	3	25/6	12	4
	Vestibular (CP angle)	98	60	38	3	23/5	11	4
	Trigeminal	4	3	1	-	2/1	1	-
2	Meningiomas	38*	16	22	1	10/3	5	3
	Cerebellar cortex and tentorial	16	5	11	1	-	-	-
	CP angle	12	5	7	-	5	-	-
	Foramen magnum	7	3	4	-	4/2	4	2
	Peri-torcular	2	2	-	-	-	-	-
	Jugular foramen	1	1	-	-	1/1	1	1
3	Hemangioblastomas	28	15	13	1	4/4	4	-
4	Dermoids	15	9	6	4	-	-	-
5	Epidermoids	9	6	3	3	-	-	1
6	Medulloblastomas	72	53	19	61	31/12	14	22
	Classical	53	42	11	51	19/7	7	15
	Desmoplasticvariant	11	8	3	4	7/1	1	1
	Anaplastic changes	5	3	2	4	3/3	5	5
	Glial differentiation	3	1	2	2	2/1	1	1
7	Cerebellar astrocytomas (HG)	47	32	15	12	33/1	2	1
8	Ependymomas	43	29	14	9	18/5	5	3
9	Cerebellar pilocytic astrocyto	24	18	6	20	15	-	-
10	Brainstem gliomas	16	11	5	12	16/6	9	7
	Juvenile pilocytic astrocytoma	5	3	2	5	5/1	2	1
	Glioblastoma multiforme	4	3	1	1	4/3	4	4
	Fibrillary astrocytomas	3	1	2	3	3/1	1	-
	Gangliogliomas	2	2	-	2	2	-	-
	Oligodendrogliomas	1	1	-	1	1	1	1
	Primitive neuroectodermal tumor	1	1	-	-	1/1	1	1
11	Metastatic posterior fossa	9	5	4	-	6/5	5	6
	Carcinoma lung	3	3	-	-	2/2	2	3
	Carcinoma breast	3	-	3	-	1/1	1	2
	Renal cell carcinoma	2	1	1	-	2/1	1	-
	Malignant melanoma	1	1	-	-	1/1	1	1
12	Pineoblastomas	7	2	5	4	7/3	3	-
Total	Posterior fossa tumors (%)	410 (100)	259 (63.2)	151 (36.8)	130 (31.7)	165 (40.2)/45 (10.9)	59 (14.3)	47 (11.4)

*38 – 4 out of 38 meningiomas were malignant (WHO Grade-III). HG – High grade (III-anaplastic and IV-glioblastoma multiforme); Astrocyto – Astrocytomas; CP=Cerebello-pontine

meningiomas (anaplastic and rhabdoid variants), 56.2% (9/16) in brainstem gliomas, 55.5% (5/9) in metastatic lesions, 42.8% (3/7) in pineoblastomas, and 19.4% (14/72) in medulloblastomas. The severe disability was more often seen in the brainstem gliomas owing to their long survival, decubitus ulcers, and respiratory system infections. However, there was no EFS in any case of malignant meningioma, which simultaneously had the highest mortality of 75.0% (3/4). The mortality in metastatic lesions was 66.6% (6/9), brainstem gliomas 43.7% (7/16), and medulloblastomas 30.5% (22/72). There was no mortality found in pinealoblastomas and pilocytic astrocytomas, although in a postoperative year, ependymoma had a lower mortality of 6.9% (3/43) and high-grade astrocytomas 2.1% (1/47).

Discussion

The present study observed that 31.7% of the patients were children (18 years and below). Histopathologically malignancy featured in most (54.1%) of the patients while benign tumors occurred in 45.8% of the patients [Tables 1 and 2]. A research study in 1997 revealed that out of the 1000 vestibular schwannoma tumors operated in 962 patients, 2.1% of the patients had residual tumors, 1.1% of the patients had severe neurological disability, 5.5% of the patients had caudal cranial nerve palsies, and 1.1% had mortality.^[2] Seol *et al.*, in 2006, analyzed 116 patients of vestibular schwannomas where the residual tumor was seen in 77.5% and the recurrence in 17.2%. The gross total resection (GTR) was the best

Table 2: Surgical outcome related to histopathological types of tumors in posterior fossa

Serial number	Histological types	Number of patients	Postoperative outcome					
			Residual lesion	Symptoms of disease progression	Recurrence	Severe disability	EFS	Mortality
	Benign lesions	188	35	10	17	9	165	5
1	Vestibular (CP angle) schwannomas	98	23	5	11	6	85	4
2	Trigeminal schwannomas	4	2	1	1	0	3	0
3	Meningiomas (Grade I, II)	34	6	0	1	3	30	0
	Meningotheliomatous	18	0	0	0	1	17	0
	Fibrous	6	1	0	0	0	6	0
	Transitional	3	1	0	0	1	2	0
	Psammomatous	2	0	0	0	0	2	0
	Atypical	2	2	0	1	1	0	0
	Angiomatous	1	1	0	0	0	1	0
	Secretory	1	1	0	0	0	1	0
	Microcystic	1	0	0	0	0	1	0
4	Hemangioblastomas	28	4	4	4	0	24	0
5	Dermoids	15	0	0	0	0	15	0
6	Epidermoids	9	0	0	0	0	8	1
	Malignant lesions	222	130	35	42	16	106	42
1	Medulloblastomas	72	31	12	14	7	40	22
2	Cerebellar astrocytomas (HG)	47	33	1	2	2	15	1
3	Ependymomas	43	18	5	5	4	22	3
4	Cerebellar pilocytic astrocyto	24	15	0	0	0	18	0
5	Brainstem gliomas	16	16	6	9	3	5	7
6	Metastatic lesions	9	6	5	5	0	2	6
7	Pineoblastomas	7	7	3	3	0	4	0
8	Meningiomas (Grade III)	4	4	3	4	0	0	3
	Anaplastic	3	3	3	3	0	0	3
	Rhabdoid	1	1	0	1	0	0	0
Total	Posterior fossa lesion	410	165	45	59	25	271	47

EFS – Event free survival; CP – Cerebello-pontine; Astrocyto – Astrocytomas; HG – High grade (III-anaplastic and IV-glioblastoma); Grade I, II, III – WHO grades

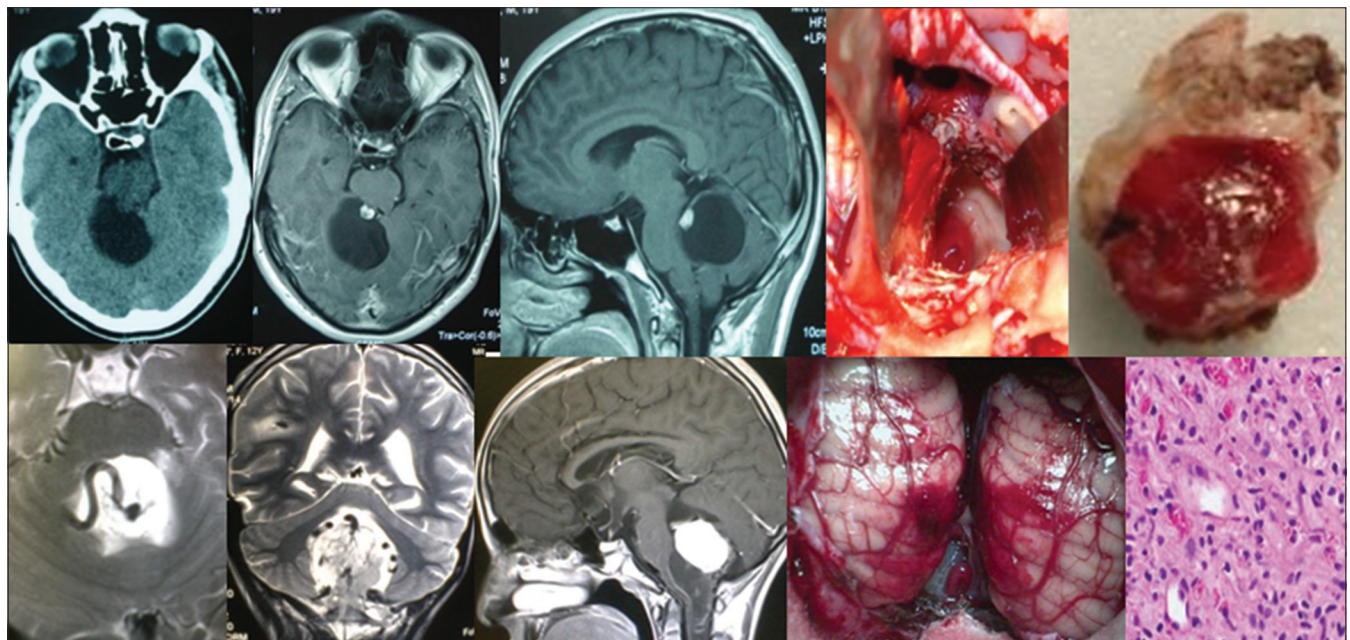


Figure 2: Two (Sibling) patients of hemangioblastomas; shows Imaging, resected specimen and histological photograph (H and E; ×400). The large serpentine vessel supplying the intramural nodule as viewed on magnetic resonance images, in the lower row, is seen on intraoperative photograph

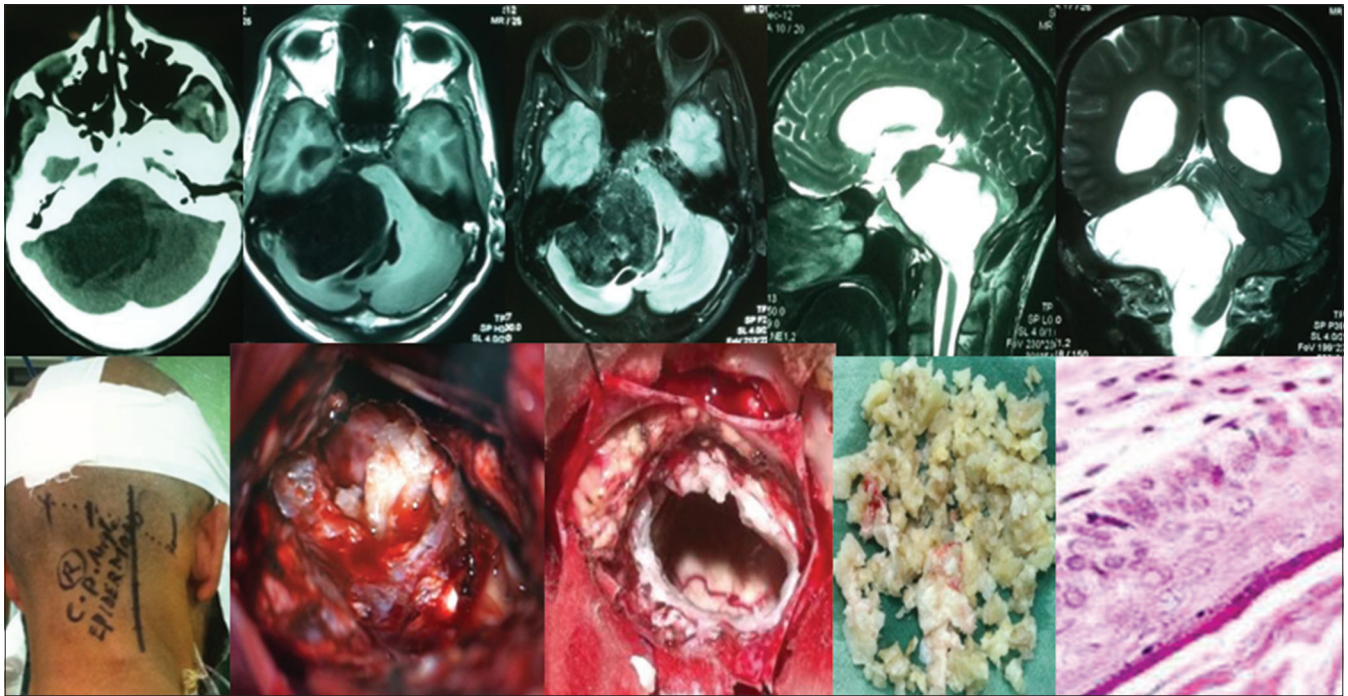


Figure 3: Computed tomography scan, magnetic resonance images, intraoperative photographs in sitting position and tumor specimen of a cerebello-pontine angle Epidermoid with histopathological microphotograph

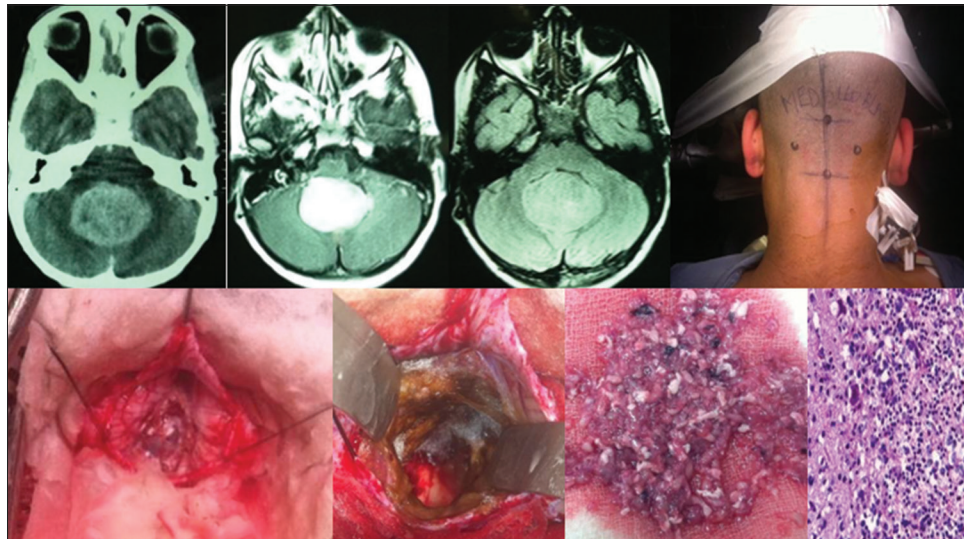


Figure 4: An 8 years male child with medulloblastoma shows radio-imaging and intraoperative pictures. Histopathological images show infiltrating tumor cells invading cerebellar cortex (H and E; $\times 20$)

approach to avoid the recurrence.^[3] Yamakami *et al.*, in 2004, revealed 14% residual tumor, 4% neurodeficit, and no mortality in 50 operated patients of vestibular schwannomas.^[4] The present study observed 50% of residual tumors in trigeminal schwannomas and 23.4% in vestibular schwannomas. About 2.9% of schwannomas were found in children. Roberti *et al.*, 2001, wrote that 161 patients of posterior fossa meningiomas were operated over a period of 9 years with residual tumors found in 43% of the patients, progression of disease and recurrence in 13.7%, and mortality in 2.5%.^[5] The

researchers, in 2012, showed postoperative results of 64 patients of posterior fossa meningiomas, where recurrence occurred in 15.6% of the patients, severe neurological deficits in 33%, hydrocephalus in 43.75%, and mortality in 3.2%.^[6] Hakuba *et al.* reported 17% mortality and severe neurological deficits in 83% of the patients in radical excision of clival meningiomas of the posterior fossa.^[7] Couldwell *et al.* studied 40 males and 69 females, a male–female ratio of 1:1.7, with posterior fossa (petroclival) meningiomas postoperatively in which gross total excision was achieved in 69% of the patients

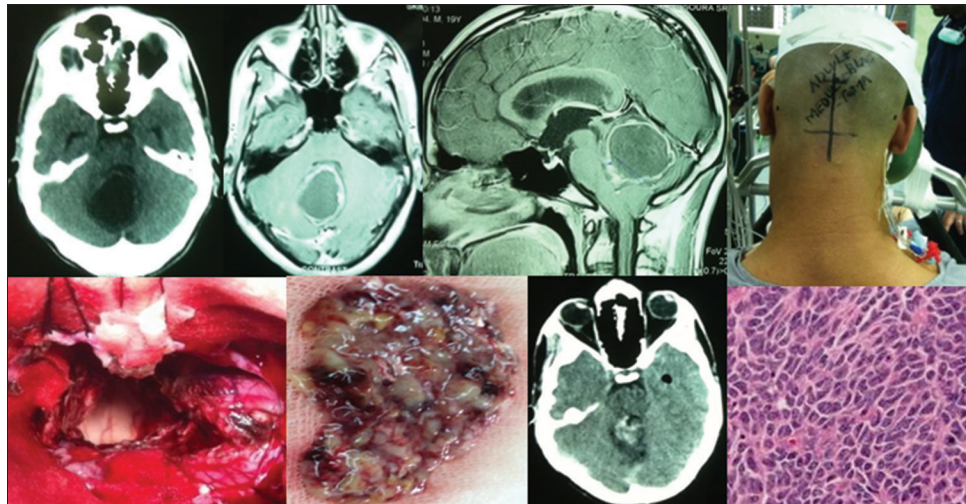


Figure 5: Adult medulloblastoma; depicts computed tomography and magnetic resonance images, intraoperative photographs in sitting position and postoperative computed tomography scan at day fourth. The histopathological micrograph shows moderate anaplasia (H and E; ×100)

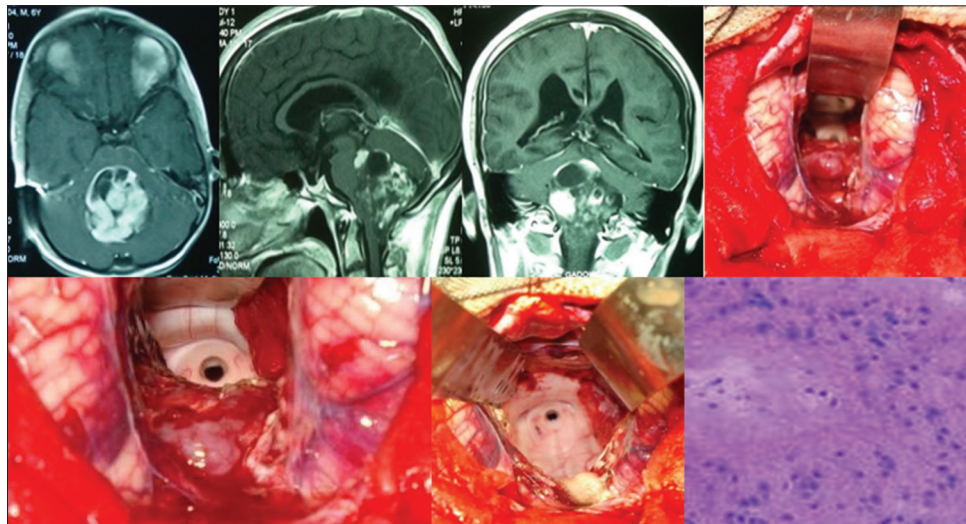


Figure 6: Magnetic resonance images and intraoperative photographs of an ependymoma of 4th ventricle (WHO Grade II). The aqueduct of sylvius is seen opening inside the fourth ventricle. Low power microphotograph shows the histopathological view of the tumor

and 13% had recurrence or progression of disease.^[8] Louis *et al.* reported a 5-year progression-free survival of approximately 50%.^[9] The present analysis showed almost similar results. Hemangioblastomas are uncommon highly vascular, well-circumscribed, <3% of all central nervous system tumors, mostly (7.5%) in adult cerebellum and brainstem.^[10] The present study found an incidence of 6.8% for hemangioblastomas [Figure 2], including two sisters in a family. The research found an EFS of 85.7% in the 1st postoperative year. Dermoid cysts represent a rare clinical entity that accounts for 0.1%–0.7% of all brain tumors.^[11] This study observed that the dermoids comprised 3.6% of all the PFTs. The EFS of dermoids was 100% in the 1st postoperative year. Epidermoids, also known as cholesteatomas, are pearly tumors and account for approximately 0.1% of all intracranial tumors growing by the desquamation of the cyst wall and accumulation

of keratin and cholesterol.^[12] Zakrzewski *et al.* studied 216 children with PTFs below the 18th year of age, which depicted male/female ratio of 1.35:1.00. The most common tumor was pilocytic astrocytoma – 41.5%; medulloblastoma – 34.5%; ependymomas – 13%, and mixed neuronal–glial tumors – 5.5%.^[13] Muzumdar *et al.*, in 2011, presented 154 patients (age <18 years) of medulloblastoma noting 92.2% (142 cases) had classical medulloblastoma and 5.1% (8 cases) had desmoplastic variant. The 5- and 10-year progression-free survival rate was 73% and 41%, respectively, for average-risk disease, while for high-risk disease, it was 34%.^[14] Rutka 1997 noted that medulloblastomas are intracranial childhood neoplasm, accounting for 25% of all childhood tumors.^[15] Furthermore, Bloom and Bessell in 1990 showed that medulloblastomas in adults account for <1% of all adult brain tumors.^[16] Chan *et al.*,

in 2000, found in a study that the recurrence rate for medulloblastomas in adults is approximately 50%–60%. The median time-to-tumor progression and recurrence is approximately 30 months after treatment.^[17] In the present study, medulloblastomas [Figures 4 and 5] were found in 17.5% of the patients mostly (84.7%) in children. The postoperative residual tumor was found in 43.0% and recurrence in 19.4%. A mortality of 30.5% occurred in the 1st-postoperative year. Djalilian and Hall reported that 53% of the patients in a study had Grade IV malignant cerebellar gliomas and 47% had anaplastic Grade III astrocytomas.^[18] The present study observed that 11.4% of PFTs had high-grade anaplastic and glioblastoma type of malignant cerebellar astrocytomas. The postoperative residual tumor was found in 70.2%, and an EFS of 31.9% in the 1st postoperative year was observed with a mortality of 2.1%. Witt *et al.* 2011 reported that the posterior fossa ependymomas comprise two distinct molecular entities, ependymoma posterior fossa A (EPN PFA), and EPN PFB, with differentiable gene expression profiles.^[19] In the present study, ependymoma [Figure 6] had residual tumors in 41.8% and recurrence in 11.6%. The EFS of 51.1% and a mortality of 6.9% were found in the 1st postoperative-year. Desai *et al.*, 2001, reported that the pilocytic cerebellar astrocytomas comprise 25% of all PFTs in children.^[20] Following up 104 children with cerebellar juvenile pilocytic astrocytomas over a mean period of 8.3 years, Daszkiewicz *et al.*, 2009, found that 57.6% (60/104) of the patients had permanent neurological deficits while 47 had significant behavioral disorders.^[21] A study by Lesniak *et al.* 2003 observed that among 57 patients of brainstem gliomas, 29 had a total surgical resection, 8 a near-total resection (>90%), 15 a subtotal resection (STR) (50%–90%), and 5 a partial resection (<50%). The progression-free survival of all patients was 71.9% at 3 years and 45.6% at 5 years.^[22] Donaldson *et al.*, 2006, reported a high rate of recurrence or progression and often followed an inexorable course of progression, despite therapy.^[23] All brainstem gliomas in the present study had postoperative residual lesions, and 37.5% had progression of disease and 56.2% recurrence. The severe disability in the brainstem gliomas, in the present study, was more often linked to the long survival, motor dysfunction, decubitus ulcers, and respiratory system infections caused by the early involvement of lower cranial nerves and the long tracts by these low-grade tumors. These had a mortality of 43.7% and an EFS of 31.2%. Sunderland *et al.*, 2016 reported that overall 80% of the patients underwent GTR, 14% underwent STR, and 6% underwent biopsy of the metastatic posterior fossa. The median overall survival was 6.00 months. The 28-day mortality was 7.6% ($n = 7$), with a perioperative morbidity of 22.8% ($n = 21$).^[24] Zhang *et al.*, 2012, observed that the most common primary site

of malignancy for brain metastasis was lung (20%–40%), followed by breast(5%–17%) and melanoma (7%–11%) with renal, colorectal, and gynecological cancers making up the majority of the remaining.^[25] The present series of 410 PFTs also consisted of 2.1% of the patients of metastatic deposits, mostly from primaries such as carcinoma lung, carcinoma breast, renal cell carcinoma, and malignant melanoma. Tate *et al.*, in 2012, suggested an increase in survival of pineoblastomas with increasing degrees of resection by observing a 5-year survival rate of 84% for patients who underwent GTR versus 53% for patients who underwent STR and 29% for patients who underwent debulking.^[26] Pineoblastomas in this study comprised 1.7% of all PFTs while 57.1% of these were children. Roberti *et al.*, 2001, reported 5% malignant meningiomas in a study of 161 patients.^[5] However, Wang *et al.*, 2016, reported that about 51% of the patients experienced recurrences. The relapse-free survival at 12 months was 84.3% and at 5 years was 57.8%.^[27] Of 410 PFTs presently, 0.97% had malignant meningiomas (WHO Grade III), mostly rhabdoid and anaplastic, which formed 10.6% of all PTFs with a recurrence of 100% and mortality of 75.0%.

Conclusion

The present study of PFTs in children and adults, of an ethnic nonmigratory Himalayan-population of India, is of regional epidemiological value. Given the aggressive biological behavior, the histologically proven malignant lesions in posterior fossa have all the opportunities to harm the vitality of posterior fossa structures and lead to catastrophic outcome pre-, intra-, and postoperatively.

Acknowledgements

We thank Aisha Jr., Huwa, Nancy, Aisha Sr., Saim-UI, Roh-UI, Abul-Adam, and Maqbool-Abu for their sincere help and sincerity.

Financial support and sponsorship

Nil.

Conflicts of interest

There are no conflicts of interest.

References

1. Cushing H. Experience with the cerebellar medulloblastoma: Critical review. *Acta Pathol Microbiol Immunol Scand* 1930;7:1-86.
2. Samii M, Matthies C. Management of 1000 vestibular schwannomas (acoustic neuromas): Surgical management and results with an emphasis on complications and how to avoid them. *Neurosurgery* 1997;40:11-21.
3. Seol HJ, Kim CH, Park CK, Kim CH, Kim DG, Chung YS, *et al.* Optimal extent of resection in vestibular schwannoma surgery: Relationship to recurrence and facial nerve preservation.

- Neurol Med Chir (Tokyo) 2006;46:176-80.
4. Yamakami I, Uchino Y, Kobayashi E, Yamaura A, Oka N. Removal of large acoustic neurinomas (vestibular schwannomas) by the retrosigmoid approach with no mortality and minimal morbidity. *J Neurol Neurosurg Psychiatry* 2004;75:453-8.
 5. Roberti F, Sekhar LN, Kalavakonda C, Wright DC. Posterior fossa meningiomas: Surgical experience in 161 cases. *Surg Neurol* 2001;56:8-20.
 6. Velho V, Agarwal V, Mally R, Palande DA. Posterior fossa meningioma "our experience" in 64 cases. *Asian J Neurosurg* 2012;7:116-24.
 7. Hakuba A, Nishimura S, Tanaka K, Kishi H, Nakamura T. Clivus meningioma: Six cases of total removal. *Neurol Med Chir (Tokyo)* 1977;17:63-77.
 8. Couldwell WT, Fukushima T, Giannotta SL, Weiss MH. Petroclival meningiomas: Surgical experience in 109 cases. *J Neurosurg* 1996;84:20-8.
 9. Louis DN, Ohgaki H, Wiestler OD, Cavenee WK, Burger PC, Jouvet A, *et al.* The 2007 WHO classification of tumours of the central nervous system. *Acta Neuropathol* 2007;114:97-109.
 10. Gläsker S. Central nervous system manifestations in VHL: Genetics, pathology and clinical phenotypic features. *Fam Cancer* 2005;4:37-42.
 11. Benzagmout M, Agharbi S, Chakour K, Chaoui ME. Dermoid cyst of the posterior fossa. *Neurosciences (Riyadh)* 2011;16:153-5.
 12. BAUMANN CH, BUCY PC. Paratrigeminal epidermoid tumors. *J Neurosurg* 1956;13:455-68.
 13. Zakrzewski K, Fiks T, Polis L, Liberski PP. Posterior fossa tumours in children and adolescents. A clinicopathological study of 216 cases. *Folia Neuropathol* 2003;41:251-2.
 14. Muzumdar D, Deshpande A, Kumar R, Sharma A, Goel N, Dange N, *et al.* Medulloblastoma in childhood-King Edward Memorial hospital surgical experience and review: Comparative analysis of the case series of 365 patients. *J Pediatr Neurosci* 2011;6:S78-85.
 15. Rutka JT. Medulloblastoma. *Clin Neurosurg* 1997;44:571-85.
 16. Bloom HJ, Bessell EM. Medulloblastoma in adults: A review of 47 patients treated between 1952 and 1981. *Int J Radiat Oncol Biol Phys* 1990;18:763-72.
 17. Chan AW, Tarbell NJ, Black PM, Louis DN, Frosch MP, Ancykiewicz M, *et al.* Adult medulloblastoma: Prognostic factors and patterns of relapse. *Neurosurgery* 2000;47:623-31.
 18. Djalilian HR, Hall WA. Malignant gliomas of the cerebellum: An analytic review. *J Neurooncol* 1998;36:247-57.
 19. Witt H, Mack SC, Ryzhova M, Bender S, Sill M, Isserlin R, *et al.* Delineation of two clinically and molecularly distinct subgroups of posterior fossa ependymoma. *Cancer Cell* 2011;20:143-57.
 20. Desai KI, Nadkarni TD, Muzumdar DP, Goel A. Prognostic factors for cerebellar astrocytomas in children: A study of 102 cases. *Pediatr Neurosurg* 2001;35:311-7.
 21. Daszkiewicz P, Maryniak A, Roszkowski M, Barszcz S. Long-term functional outcome of surgical treatment of juvenile pilocytic astrocytoma of the cerebellum in children. *Childs Nerv Syst* 2009;25:855-60.
 22. Lesniak MS, Klem JM, Weingart J, Carson BS Sr. Surgical outcome following resection of contrast-enhanced pediatric brainstem gliomas. *Pediatr Neurosurg* 2003;39:314-22.
 23. Donaldson SS, Laningham F, Fisher PG. Advances toward an understanding of brainstem gliomas. *J Clin Oncol* 2006;24:1266-72.
 24. Sunderland GJ, Jenkinson MD, Zakaria R. Surgical management of posterior fossa metastases. *J Neurooncol* 2016;130:535-42.
 25. Zhang X, Zhang W, Cao WD, Cheng G, Liu B, Cheng J. A review of current management of brain metastases. *Ann Surg Oncol* 2012;19:1043-50.
 26. Tate M, Sughrue ME, Rutkowski MJ, Kane AJ, Aranda D, McClinton L, *et al.* The long-term postsurgical prognosis of patients with pineoblastoma. *Cancer* 2012;118:173-9.
 27. Wang YC, Chuang CC, Wei KC, Chang CN, Lee ST, Wu CT, *et al.* Long Term Surgical Outcome and Prognostic Factors of Atypical and Malignant Meningiomas. *Sci Rep* 2016;6:35743.