

Contrecoup Extradural Hematoma with Coronal Suture Diastasis

Abstract

Extradural hematoma (EDH) generally occurs in the site of impact, that is, coup injury site. EDH is associated with fracture of skull in many a times due to direct impact. However, EDH in counter coup site is a rare occurrence. Hardly, yet, 12 cases have been reported including this case. Here, we reported a case of a 22-year-old male of contrecoup acute EDH who had sustained head injury due to fall from bike. Physical examination revealed direct impact at the left occipito-parietal region with laceration of scalp and bruise with transient loss of consciousness at the time of injury. There was no evidence of impact on the right side of his head. Computed tomography scan revealed an EDH in the right fronto-temporal region without any bone fracture on bone windows. On intraoperative exploration, it is found that there was coronal suture diastasis with small subgaleal hematoma and right fronto-temporal extradural hematoma. The evacuation of EDH was done. The patient discharged on 3rd postoperative day. It can be concluded that direct impact on head causes exactly opposite hit of brain, and compensatory rebound causes a negative pressure in between the layers causing disruption of vessels and potential accumulation of blood. This mechanism mostly favors for acute subdural hematoma due to compact attachment of dura with cranium. However, in this case, diastasis of coronal suture due to transmitted force is the cause of accumulation of blood extradurally in relatively loosely adhered dura in fronto-temporal region where a potential negative pressure space is created by contrecoup injury.

Keywords: Contrecoup, coronal suture diastases, extradural hematoma

Introduction

Extradural hematoma (EDH) is a collection of blood between duramater and inner table of the skull which generally occurs due to injury at the site of impact (coup injury).^[1] Coup injury is a common mechanism in EDH case, but counter-coup injury causing EDH opposite to the site of impact is a quite rare case and hardly only 12 cases have been reported including this case.^[2-12] We presented a case of a 22-year-old male of contrecoup acute EDH who sustained head injury due to fall from bike.

Case Report

A 22-year-old male presented with head injury due to fall from bike 6 h before admitted to our emergency department. He had transient loss of consciousness at the time of injury. He had bruise with laceration of scalp over the left parieto-occipital region, small laceration over the left frontal area, and abrasions over the left shoulder. His pulse rate was 62/min, blood pressure was 130/80 mmHg, and his Glasgow

Coma Score was 14/15. The pupils were normal. Computed tomography scan of the brain revealed right fronto-temporal hyperdense lesion with mass effect suggesting contrecoup EDH [Figure 1a]. There was no visible bony abnormality

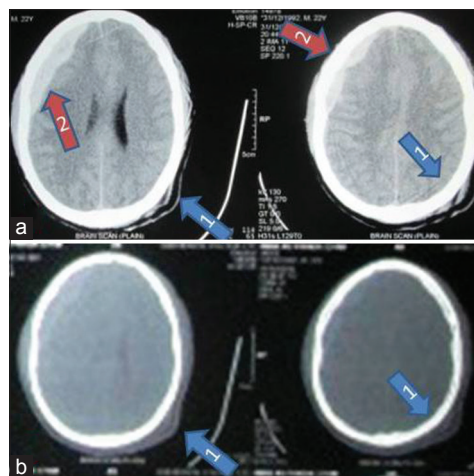


Figure 1: Preoperative computed tomography scan. (a) Axial computed tomography scan of the brain showing a soft-tissue injury; at arrow marked 1 is coup injury and a hyperdense concavo convex extradural hematoma in countercoup right fronto-temporal area is marked by arrow 2. (b) Axial bone window shows no bony fracture in coup site marked as arrow 1

How to cite this article: Nath PC, Mishra SS, Dhir MK, Deo RC, Behera BR, Rout SK. Contrecoup extradural hematoma with coronal suture diastasis. *Asian J Neurosurg* 2017;12:751-3.

**Pratap Chandra Nath,
Sudhansu Sekhar Mishra,
Manmath Kumar Dhir,
Rama Chandra Deo,
Bikash Ranjan Behera,
Sitansu Kumar Rout**

*Department of Neurosurgery,
SCB Medical College, Cuttack,
Odisha, India*

Address for correspondence:

*Dr. Pratap Chandra Nath,
Department of Neurosurgery,
SCB Medical College,
Cuttack - 753 007,
Odisha, India.
E-mail: drpratapnath@
rediffmail.com*

Access this article online

Website: www.asianjns.org

DOI: 10.4103/ajns.AJNS_12_15

Quick Response Code:



This is an open access article distributed under the terms of the Creative Commons Attribution-NonCommercial-ShareAlike 3.0 License, which allows others to remix, tweak, and build upon the work non-commercially, as long as the author is credited and the new creations are licensed under the identical terms.

For reprints contact: reprints@medknow.com

detected [Figure 1b]. The patient was immediately operated by right Falconer's osteoplastic flap exposing fronto-temporo-parietal area. Intraoperatively, it was found that there was about 15 ml of subgaleal hematoma with wide coronal sutural diastasis. The osteoplastic flap is taken up by four burr holes. It was found that about 80 ml of extradural clots was evacuated. Dural hitches were given. The wound closed in layer with a drain *in situ*. The patient discharged on 3rd postoperative day without any neurological deficit [Figure 2].

Discussion

EDH usually occurs in the coup site and commonly associated with fractures of skull.^[1] EDH is the collection of blood in between the inner layer of cranium and dura. Usually, bleeding of EDH is arterial origin and may occur from dural sinuses, fracture sites, or sutural diastasis in coup injury sites. However, counter coup EDH due to sutural diastasis as in our case is rare and reported as a case report in one case previously.^[2] Contrecoup EDH is a hardly reported entity and only 12 cases have been reported yet including this case.^[2-12] Most of the counter coup EDH cases reported have some coup intracranial lesion,^[5,6,8,9] but in our case, there was no intracranial coup site injury. Our case is a young male of 22 years with involvement of the right fronto-temporal region. Hence, female preponderance and relatively high old age as described by Takeuchi *et al.*^[12] are not consistent with this case though the involvement of frontal region is similar. The peak incidence of EDH in the second decade of life in general is similar to contrecoup EDH as seen in our case. Out of all reported cases known, only three cases including our case are below the age of 50 years which are 28 years,^[2] 21 years,^[5] and 22 years.

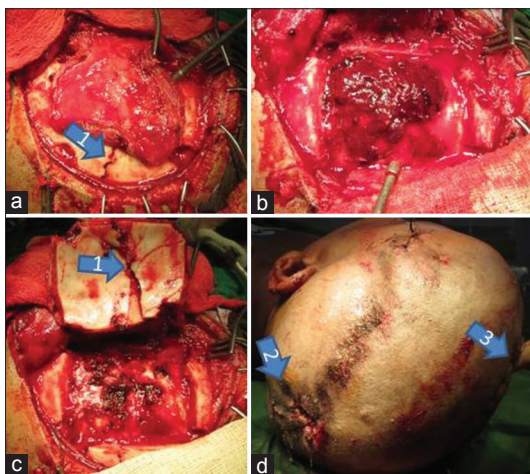


Figure 2: Intraoperative on table photographs. (a) Coronal suture diastasis as marked by arrow 1. (b) Extradural hematoma more confounding to fronto-temporal region. (c) After evacuation of extradural hematoma and dural hitches, arrow marked 1 shows sutural diastasis from inside after taking up of osteoplastic flap. (d) The superficial coup wound with operative stitched wound in contrecoup side

On impact, the brain moves diagonally and hits the opposite cranium where it rebounds producing a tractional negative pressure and causes rupture of bridging and other vessels. The impacted energy is responsible for the production of both coup and contrecoup injuries.^[13]

Coup and contrecoup injuries are caused by different mechanisms. In coup injury, direct blunt impact causes scalp injury, fracture of skull, EDH, acute subdural hematoma (ASDH), parenchymal contusion, and diffuse axonal injury due to direct transmitted energy in the impacted sites which also causes whole brain to move and have an impact in a site just opposite to the coup site. When the brain hits in the opposite side, there occur parenchymal contusion and ASDH due to stretching and vascular rupture. After hitting, the brain bounces due to bouncy force of cerebrospinal fluid and brains' elastic property. During bounce, it creates different negative pressure zones where ASDH and parenchymal contusion are more common than EDH. By this hypothesis, it can be described that, after a trauma depending on impacted force, the brain bounces many times both in coup and contrecoup sites to come into a neutral position [Figure 3]. In case of penetrating and other injuries, the physical mechanism is totally different because the energy transmission is different. The point of maximum damage depends on the point of action where more transmitted forces meet. If the impact is less enough, it may become neutralized during passage through any layer of brain in the coup phase of injury.

As in our case, detection of sutural diastasis may not be possible at normal axial views, but sutural diastasis may cause counter coup EDH due to bleeding into negative pressure zone created at that site. Contrecoup EDH is a

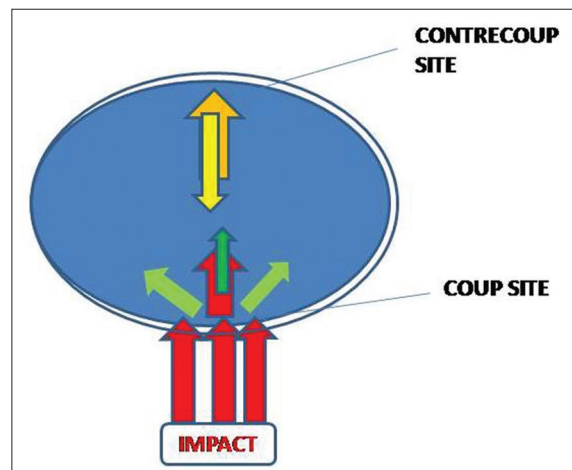


Figure 3: Hypothetical physical energy transfer model showing coup and contrecoup injuries. Three parallel red arrows suggest the force of impact which causes skull deformation and coup injury. Single red arrow with other two bottle green arrows suggests transmitted energy. The orange arrow suggests that the brain hits the contrecoup site. The yellow arrow in contrecoup site suggests rebound from contrecoup site. The green arrow in coup site suggests re-rebound from coup sites until energy will be zero or neutral

rare entity but life threatening. Early diagnosis and surgical decompression provide a good outcome.^[14]

Financial support and sponsorship

Nil.

Conflicts of interest

There are no conflicts of interest.

References

1. Arvind B, Dhaval S, Indira DB, Sastry Kolluri VR. Coup and contrecoup head injuries: Predictors of outcome. *Indian J Neurotrauma* 2009;6:115-8.
2. Shamji MF, Lesiuk H. Traumatic coronal suture diastasis and contre-coup epidural hematoma. *Can J Neurol Sci* 2010;37:906-8.
3. Okamoto H, Harada K, Yoshimoto H, Uozumi T. Acute epidural hematoma caused by contrecoup injury. *Surg Neurol* 1983;20:461-3.
4. Shigemori M, Moriyama T, Eguchi G, Noguchi M, Kawasaki K, Kawaba T, *et al.* Acute epidural hematoma of the posterior fossa caused by fronto-temporal impact. Case report. *Neurol Med Chir (Tokyo)* 1985;25:489-92.
5. Abe S, Furukawa K, Endo S, Hoshi S, Kanaya H. Acute epidural hematoma of the posterior fossa caused by forehead impact. *No Shinkei Geka* 1988;16:321-5.
6. Balasubramaniam V, Ramesh VG. A case of coup and contrecoup extradural hematoma. *Surg Neurol* 1991;36:462-4.
7. Miyazaki Y, Isojima A, Takekawa M, Abe S, Sakai H, Abe T. Frontal acute extradural hematoma due to contrecoup injury: A case report. *No Shinkei Geka* 1995;23:917-20.
8. Motohashi O, Tominaga T, Shimizu H, Koshu K, Yoshimoto T. Acute epidural hematoma caused by contrecoup injury. *No To Shinkei* 2000;52:833-6.
9. Mishra A, Mohanty S. Contre-coup extradural haematoma: A short report. *Neurol India* 2001;49:94-5.
10. Mitsuyama T, Ide M, Kawamura H. Acute epidural hematoma caused by contrecoup head injury – Case report. *Neurol Med Chir (Tokyo)* 2004;44:584-6.
11. Sato S, Mitsuyama T, Ishii A, Kawamata T. An atypical case of head trauma with late onset of contrecoup epidural hematoma, cerebellar contusion, and cerebral infarction in the territory of the recurrent artery of Heubner. *J Clin Neurosci* 2009;16:834-7.
12. Takeuchi S, Takasato Y, Masaoka H, Otani N. Contrecoup epidural hematoma. *Neurol India* 2010;58:152-4.
13. Hooper R. Observations on extradural haemorrhage. *Br J Surg* 1959;47:71-87.
14. Cakir Z, Cakir M, Emet M, Aslan S, Saritas A. Acute epidural haematoma due to counter-coup head injury: A case report. *Hong Kong J Emerg Med* 2009;16:252-4.