

## Case Report

## Hydrocephalus after Deep Brain Stimulation for Parkinson's Disease

## Abstract

A fearsome complication of deep brain stimulation (DBS) constitutes intracranial hemorrhage. Incidence rates vary between 0.5% and 5%, with 1.1% of cases resulting in permanent deficit or death. Intracranial hemorrhage can present asymptotically or result in fatal outcome. A rare complication in this setting is acute hydrocephalus due to obstruction of the cerebrospinal fluid flow. This complication might have catastrophic consequences resulting in death in a few hours if not an external ventricular drainage promptly is placed. We report a patient with acute hydrocephalus due to intraventricular hemorrhage after the DBS procedure. Patients should be warned of this complication when informed consent is obtained.

**Keywords:** *Complications, deep brain stimulation, hemorrhage, hydrocephalus, Parkinson's disease*

## Introduction

For the past nearly three decades,<sup>[1]</sup> deep brain stimulation (DBS) constitutes an established and efficient surgical procedure for movement disorders, such as Parkinson's disease, dystonia, and essential tremor. To date, more than 100,000 procedures have been performed worldwide.<sup>[2]</sup> Although DBS is considered to be relatively safe, transient or permanent complications can occur.<sup>[3]</sup> Hemorrhage constitutes the most fearsome complication, with incidence rates reported between 0.5%<sup>[4]</sup> and 5%, resulting in 1.1% of cases in permanent deficit or death.<sup>[5]</sup> Clinical manifestations of intracranial hemorrhage vary from asymptomatic to fatal cases. Risk factors of hemorrhage occurrence can be classified into surgical- and patient-related ones. Surgical-related risk factors include the use of multiple recording microelectrodes or multiple attempts to position the definitive electrode,<sup>[6]</sup> whereas patient-related risk factors include hypertension,<sup>[7]</sup> antithrombotic therapy,<sup>[8]</sup> or advanced age.<sup>[9]</sup> In this paper, we report a patient with acute hydrocephalus due to intraventricular hemorrhage after DBS procedure. To the best of our knowledge, this is the first report of acute hydrocephalus after the DBS procedure.

## Case Report

A 59-year-old female patient with diagnosis of Parkinson's disease underwent DBS

surgery of the subthalamic nucleus; comorbidities were protein-S deficiency, hypercholesterolemia, and a previous history of transient ischemic attack. For the protein-S deficiency, she was treated with cardioaspirin, which was stopped 6 days before surgery. DBS was proposed due to poor control of motor symptoms despite optimal medical therapy. The surgical procedure of electrode positioning (Medtronic Lead 3389®) was uneventful with correct positioning verified with intraoperative computed tomography (CT) scan. Intraoperatively, three microrecording electrodes were used. On the 2<sup>nd</sup> day of postsurgery, the patient presented a deep stuporous state. An urgent brain CT scan was performed showing a left basal ganglia hemorrhage with blood in the aqueduct of sylvius and the presence of acute hydrocephalus [Figure 1]. An urgent external ventricular drainage was positioned. We used the right electrode entry point to position the external ventricular catheter. The fixing system of the stim-lock was removed maintaining the DBS electrode in place which was fixed to the skull with titanium plate. The postsurgical CT scan showed the correct positioning of the ventricular catheter. The patient showed a progressive improvement returning to normal level of consciousness. The external drainage was removed on the 7<sup>th</sup> day after 2 days of not draining at a height of 15 cm H<sub>2</sub>O. Unfortunately, the patient presented few hours after the removal of the external drainage an acute

**Edvin Zekaj,  
Christian Saleh,  
Domenico Servello**

*Department of Neurosurgery,  
IRCCS Istituto Ortopedico  
Galeazzi, Milan, Italy*

## Address for correspondence:

*Dr. Edvin Zekaj,  
Department of Neurosurgery,  
IRCCS Istituto Ortopedico  
Galeazzi, Milan, Italy.  
E-mail: ezekaj@yahoo.com*

## Access this article online

**Website:** [www.asianjns.org](http://www.asianjns.org)

**DOI:** 10.4103/ajns.AJNS\_136\_18

## Quick Response Code:



**How to cite this article:** Zekaj E, Saleh C, Servello D. Hydrocephalus after deep brain stimulation for Parkinson's disease. *Asian J Neurosurg* 2019;14:538-40.

This is an open access journal, and articles are distributed under the terms of the Creative Commons Attribution-NonCommercial-ShareAlike 4.0 License, which allows others to remix, tweak, and build upon the work non-commercially, as long as appropriate credit is given and the new creations are licensed under the identical terms.

**For reprints contact:** [reprints@medknow.com](mailto:reprints@medknow.com)

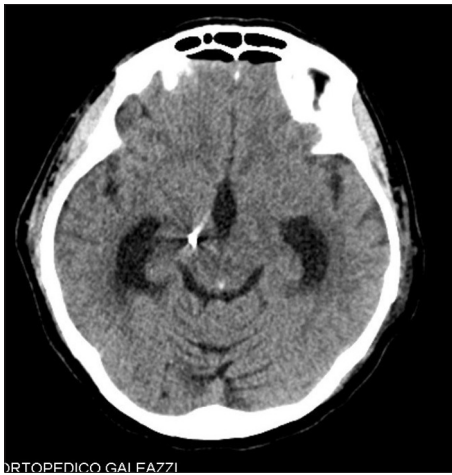


Figure 1: Hydrocephalus and blood in the aqueduct

worsening with a Glasgow Coma Scale (GCS) dropping to 11. CT scan revealed an important pneumocephalus with widening of the ventricular system [Figure 2]. A repeated surgical procedure of ventricular catheter positioning was necessary. The patient showed after this procedure a progressive clinical improvement and recovered fully; finally, the catheter could be removed after 10 days.

## Discussion

Intracranial hemorrhage is the most feared complication for surgeons and patients.<sup>[5]</sup> This complication is fairly rare, but unfortunately in some reports, it has resulted fatal due to acute intracranial hypertension. Hemorrhages after DBS procedure maybe located deep in the basal ganglia or superficial at cortical level usually secondary to occlusion of superficial cortical veins or rupture of sulcal vessels. The deep located hemorrhages may extend into the ventricular system. Intraventricular blood may lead to acute hydrocephalus due to obstruction of the cerebrospinal fluid flow. This complication might have catastrophic consequences resulting in death in few hours if not an external ventricular drainage promptly is placed. To the best of our knowledge, to date, there is no report of acute hydrocephalus after DBS procedure. The aim of our paper is to highlight on the importance of this extremely rare but potentially fatal complication. The main issue of acute hydrocephalus is early diagnosis and prompts surgical treatment. Clinically, patients with acute hydrocephalus have symptoms of intracranial hypertension, such as headache, nausea, vomiting, and alteration of consciousness. Many patients present with only alteration of consciousness such as somnolence or stupor. Under this condition, the early diagnosis of acute hydrocephalus in patients undergoing DBS surgery might be complicated as many patients undergoing DBS present with postsurgical confusion and somnolence due to postsurgical pneumoencephalus. Patients presenting with low GCS as 12–13 need a brain CT scan. In the presence of only

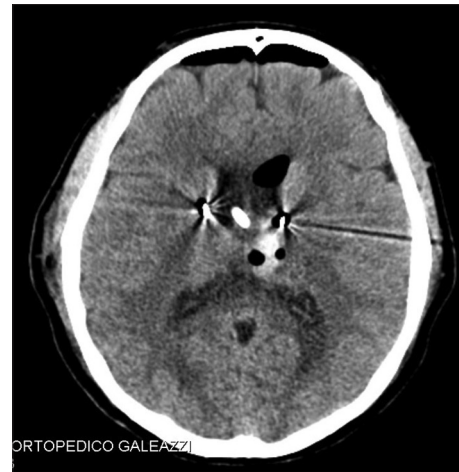

Figure 2: Pneumocephalus with widening of ventricular system

pneumocephalus clinical observation and intravenous hydration is sufficient; however, in case of hemorrhage radiological follow-up or surgery should be considered. We advise a close observation in cases of hemorrhages near the ventricular wall as hemorrhage extension into the ventricular system might lead to acute hydrocephalus.

## Conclusion

This is the first report showing hydrocephalus as a potentially severe complication of DBS for movement disorders. The physiopathology of this phenomenon is related to postoperative intraventricular hemorrhage. Patients should be warned of this complication when informed consent is obtained.

## Declaration of patient consent

The authors certify that they have obtained all appropriate patient consent forms. In the form, the patient has given her consent for her images and other clinical information to be reported in the journal. The patient understands that name and initials will not be published, and due efforts will be made to conceal identity, but anonymity cannot be guaranteed.

## Financial support and sponsorship

Nil.

## Conflicts of interest

There are no conflicts of interest.

## References

1. Hariz M. Twenty-five years of deep brain stimulation: Celebrations and apprehensions. *Mov Disord* 2012;27:930-3.
2. Sugiyama K, Nozaki T, Asakawa T, Koizumi S, Saitoh O, Namba H. The present indication and future of deep brain stimulation. *Neurol Med Chir (Tokyo)* 2015;55:416-21.
3. Hariz MI. Complications of deep brain stimulation surgery. *Mov Disord* 2002;17 Suppl 3:S162-6.
4. Fenoy AJ, Simpson RK Jr. Risks of common complications in

- deep brain stimulation surgery: Management and avoidance. J Neurosurg 2014;120:132-9.
5. Zrinzo L, Foltynie T, Limousin P, Hariz MI. Reducing hemorrhagic complications in functional neurosurgery: A large case series and systematic literature review. J Neurosurg 2012;116:84-94.
6. Hariz MI. Safety and risk of microelectrode recording in surgery for movement disorders. Stereotact Funct Neurosurg 2002;78:146-57.
7. Xiaowu H, Xiufeng J, Xiaoping Z, Bin H, Laixing W, Yiqun C, *et al.* Risks of intracranial hemorrhage in patients with Parkinson's disease receiving deep brain stimulation and ablation. Parkinsonism Relat Disord 2010;16:96-100.
8. Sivakumar W, Garber ST, Schrock LE, House PA. Recurrent, delayed hemorrhage associated with edoxaban after deep brain stimulation lead placement. Case Rep Neurol Med 2013;2013:691840.
9. Ben-Haim S, Asaad WF, Gale JT, Eskandar EN. Risk factors for hemorrhage during microelectrode-guided deep brain stimulation and the introduction of an improved microelectrode design. Neurosurgery 2009;64:754-62.