

Spontaneous Intracranial Extradural Hematoma Secondary to Hypofibrinogenemia: A Rare Case Report

Abstract

Spontaneous extradural hematoma is a well-documented but fairly rare condition, which can be associated with conditions such as vascular malformations, sickle cell disease, metastasis to the skull, infectious diseases of the skull, coagulation disorders, and use of anticoagulants. Of these, very few cases are of life-threatening extradural hematomas in adults, where hypofibrinogenemia is the cause of bleed, without any history of trauma. In this report, we have discussed the management of such a patient.

Keywords: Cryoprecipitate, extradural hematoma, hypofibrinogenemia

**Santosh Prabhu,
Sidharth Agarwal,
Sujata Prabhu¹**

Departments of Neurosurgery
and ¹Neuroanesthesia, Western
India Institute of Neurosciences,
Kolhapur, Maharashtra, India

Introduction

Intracranial extradural hematomas are usually traumatic in origin,^[1] but spontaneous extradural hematomas are a rare entity, first documented by Schneider in 1951,^[2] since then, only around 20 such cases have been reported.^[3-4] Deficiency of fibrinogen levels in blood (Normal: 2–4 g/L), but not complete absence is termed as “hypofibrinogenemia.” Fibrinogen is a coagulation factor (Factor I), which is converted to insoluble fibrin in the last step of the coagulation pathway, in the presence of activated thrombin (Factor II).^[5] This inability to form insoluble fibrin from fibrinogen leads to the inability of the blood to clot, thus leading to bleeding diathesis.

Case Report

A 21-year-old female was admitted with a history of dull aching headache since 1 day, associated with multiple episodes of nonprojectile vomiting. This was followed by progressive drowsiness leading to coma over the past 10 h. There was no history of trauma. The patient was a known case of hypofibrinogenemia since birth. She was the 3rd child of the II degree consanguineous marriage.

The patient was admitted to a very critical condition. Upon admission, she was

unconscious, with no eye-opening, flexing right upper and lower limbs to pain, left side was plegic. Pupils: Right: 5 mm, Left: 4 mm nonreactive to light, GCS: E1M4V1 = 6/15. Vitals were stable. In view of her low Glasgow Coma Score (GCS), she was intubated. Computed tomography (CT) scan done showed a large extra-axial extradural hematoma in the right frontal convexity measuring approximately 8.9 cm × 4.0 cm × 6.7 cm with mass effect in the form of subfalcine herniation, evidence of early uncal herniation, and a midline shift of 1.2 [Figure 1].

On investigation, the coagulation profile of the patient was grossly deranged, prothrombin time was >180 s (Control: 13.5 s), INR was 14.7, activated partial thromboplastin time (APTT): >180 (Control: 28.5 s), and fibrinogen: 90.4 (Normal: 150–400 mg/dl). Looking at the rapid deterioration in the condition of the patient, immediate surgery to evacuate the bleed was proposed. Hematologist was consulted, and the patient was taken up for surgery with transfusion of 4 units fresh frozen plasma (FFP), 4 units cryoprecipitate, and 1 unit packed cells, intraoperatively.

The surgery was uneventful. Intraoperatively, the blood was liquid and had not clotted in the extradural space, frank blood gushed out of the burr holes. Postoperative CT scan showed significant

Address for correspondence:

Prof. Santosh Prabhu,
Department of Neurosurgery,
Western India Institute of
Neurosciences, 183/B, Nagala
Park, Kolhapur - 416 002,
Maharashtra, India.
E-mail: sprabhuneuro@gmail.
com

Access this article online

Website: www.asianjns.org

DOI: 10.4103/ajns.AJNS_143_19

Quick Response Code:



How to cite this article: Prabhu S, Agarwal S, Prabhu S. Spontaneous intracranial extradural hematoma secondary to hypofibrinogenemia: A rare case report. *Asian J Neurosurg* 2019;14:1288-90.

This is an open access journal, and articles are distributed under the terms of the Creative Commons Attribution-NonCommercial-ShareAlike 4.0 License, which allows others to remix, tweak, and build upon the work non-commercially, as long as appropriate credit is given and the new creations are licensed under the identical terms.

For reprints contact: reprints@medknow.com

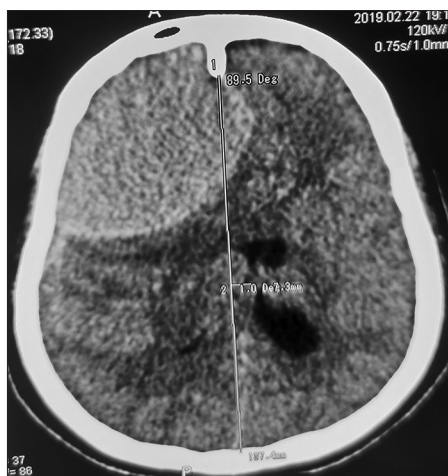


Figure 1: Computed tomography scan head showing large right frontal extradural hematoma with severe mass effect and subfalcine herniation. Note relative hypodensity of hematoma due to hypofibrinogenemia (43 HU)

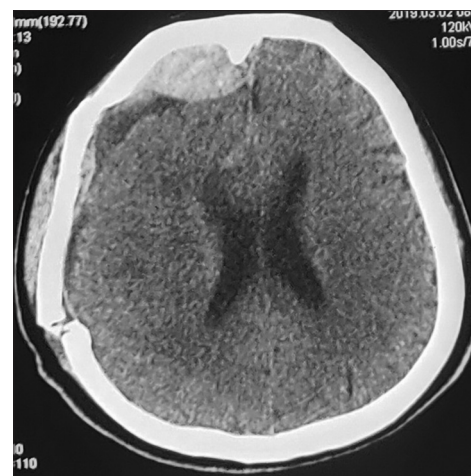

Figure 2: Postoperative computed tomography scan showing good evacuation of epidural hemorrhage, small new postoperative epidural hemorrhage with hyperdensity (HU 78) indicating the correction of hypofibrinogenemia in postoperative period

evacuation of the extradural hematoma with reduction in mass effect and restoration of midline shift [Figure 2].

Prothrombin time international normalized ratio (PT-INR) and APTT levels were monitored regularly postsurgery. FFP and cryoprecipitate transfused as indicated, to keep the PT-INR and APTT levels within normal range. Postoperatively, the patient got progressively got better, became conscious, and both pupils became reactive. At discharge, the patient's GCS was E4M6V5 = 15/15, had power grade IV in all four limbs, and walked without support. A total of 1-unit whole blood, 2 units of packed cells, 51 units of cryoprecipitate, and 63 units of FFP were transfused during the intra- and post-operative stay. No fibrinogen concentrates were transfused due to nonavailability.

Discussion

Hypofibrinogenemia is defined as a decreased level of circulating fibrinogen in blood (normal range 200–400 mg/dl), with an incidence of 1 in 1 million.^[6,7] Overall, 8% of all the cases of bleeding disorders are due to fibrinogen deficiency.^[8] Fibrinogen is a 340 kD glycoprotein which is synthesized in the liver. It consists of pairs of three polypeptide chains, thus forming a hexamer. The synthesis is based on three genes, located on chromosome 4.^[9] It has a half-life of 2–4 days. It is inherited through an autosomal recessive trait, and parental consanguinity is common among affected females.^[10] According to a study conducted by Peyvandi *et al.*, there were no cases of CNS bleeding reported in patients with mild fibrinogen deficiency (fibrinogen levels of 10 mg/dl or more) who usually presented with menorrhagia, hemarthrosis, muscle hematoma, GI bleeds, and epistaxis.^[11] Prolonged umbilical stump bleeding at birth is highly suggestive of such bleeding disorders.

Intracranial extradural hematomas are collection of blood between the inner surface of the cranium and the dura.

The collection is limited by suture lines. It can cause significant life-threatening mass effect on the brain. Most of the extradural hematomas are traumatic in origin^[1] where the origin of bleed is from the meningeal arteries. Once an artery starts to bleed, it strips the dura from the cranium due to the increasing bleed. However, spontaneous nontraumatic extradural hematomas are very rare and mostly occur due to vascular malformations,^[12] sickle cell disease,^[13] metastasis to the skull,^[4] infectious diseases of the skull,^[12] coagulation disorders,^[14] and use of anticoagulants.^[15]

When hypofibrinogenemia is the cause of an intracranial extradural hematoma, time is the essence of successful therapy. Early identification and treatment is paramount to save the patient. For large extradural hematomas, surgical evacuation of the hematoma should be done pronto. The coagulation profile can be corrected by giving fibrinogen concentrates and transfusing cryoprecipitate and FFP. Furthermore, the use of tranexamic acid is indicated in such patients, which prevents fibrinolysis of the clots once formed. In our case, fibrinogen concentrates were not available, so cryoprecipitates and FFP were transfused to maintain PT-INR and APTT values within normal range. Injection tranexamic acid was added to the regimen. Patients usually require multiple transfusions during the perioperative period as the risk of rebleed is high. Once safely out of the perioperative period, regular PT-INR and APTT level monitoring should be done. Patients should also watch for bleeding tendencies such as menorrhagia, hematuria, easy bruising, bleeding gums, and other signs of coagulation disorders.

Our patient discussed here had prolonged umbilical stump bleed at birth which led to investigations and diagnosis of hypofibrinogenemia. The patient also had severe menorrhagia at the age of 14 which was controlled by transfusion of cryoprecipitates and FFPs.

Another finding worth discussion here is that the primary bleed, which the patient had was hypodense on the CT scan (43 HU) [Figure 1]; but another small extradural hematoma which occurred postoperatively, was hyperdense on the CT scan (78 HU) [Figure 2]. This may be attributed to the high INR preoperatively, which prevented the blood to clot in the extradural space, thus giving rise to a hypodense bleed. This finding is also confirmed from the intraoperative finding that blood in extradural space had not clotted and it was seen coming out of the burr holes of the craniotomy, in a liquid form. This is in contrast to the postoperative bleed which is hyperdense, as by that time, the INR had been restored to the near-normal range (postoperative INR = 1.49), and hence the blood clotted.

In such patients, whether to give cryoprecipitate prophylactically is still a topic of discussion.

Conclusion

Spontaneous intracranial extradural hematomas secondary to hypofibrinogenemia though rare can present with life-threatening hematomas which may warrant emergent surgical management. Immediate correction of the coagulation profile can be achieved by transfusion of FFP and cryoprecipitate intra or preoperatively. Tranexamic acid can also be added to the regimen. Early diagnosis and quick management are paramount factors that decide prognosis and outcome.

Declaration of patient consent

The authors certify that they have obtained all appropriate patient consent forms. In the form the patient(s) has/have given his/her/their consent for his/her/their images and other clinical information to be reported in the journal. The patients understand that their names and initials will not be published and due efforts will be made to conceal their identity, but anonymity cannot be guaranteed.

Financial support and sponsorship

Nil.

Conflicts of interest

There are no conflicts of interest.

References

1. Cooper RP. Post traumatic intracranial mass lesion. In: Head Injury. 2nd ed. Baltimore: Williams & Wilkins; 1987. p. 238-84.
2. Schneider RC, Hegarty WM. Extradural hemorrhage as a complication of otological and rhinological infections. *Ann Otol Rhinol Laryngol* 1951;60:197-206.
3. Novaes V, Gorbitz C. Extradural hematoma complicating middle-ear infection. Report of a case. *J Neurosurg* 1965;23:352-3.
4. Wani AA, Ramzan AU, Kirmani AR, Bhatt AR, Hamdani N, Zargar J. Idiopathic epidermoid causing spontaneous extradural hematoma: Case report. *Neurosurgery* 2008;62:971.
5. Palta S, Saroa R, Palta A. Overview of the coagulation system. *Indian J Anaesth* 2014;58:515-23.
6. Mannucci PM, Duga S, Peyvandi F. Recessively inherited coagulation disorders. *Blood* 2004;104:1243-52.
7. Bornikova L, Peyvandi F, Allen G, Bernstein J, Manco-Johnson MJ. Fibrinogen replacement therapy for congenital fibrinogen deficiency. *J Thromb Haemost* 2011;9:1687-704.
8. Peyvandi F. Epidemiology and treatment of congenital fibrinogen deficiency. *Thromb Res* 2012;130 Suppl 2:S7-11.
9. Acharya SS, Dimichele DM. Rare inherited disorders of fibrinogen. *Haemophilia* 2008;14:1151-8.
10. Mansour AM, Jaroudi MO. Recurrent vitreous haemorrhage and epidural haematoma in a child with hypofibrinogenemia. *BMJ Case Rep* 2012;2012. pii: bcr2012006478.
11. Peyvandi F, Haertel S, Knaub S, Mannucci PM. Incidence of bleeding symptoms in 100 patients with inherited afibrinogenemia or hypofibrinogenemia. *J Thromb Haemost* 2006;4:1634-7.
12. Griffiths SJ, Jatavallabhula NS, Mitchell RD. Spontaneous extradural haematoma associated with craniofacial infections: Case report and review of the literature. *Br J Neurosurg* 2002;16:188-91.
13. N'dri Oka D, Tokpa A, Bah A, Derou L. Spontaneous intracranial extradural hematoma in sickle cell disease. *J Neurol Surg Rep* 2015;76:e97-9.
14. Zheng FX, Chao Y. Spontaneous intracranial extradural hematoma: Case report and literature review. *Neurol India* 2009;57:324-6.
15. Ruschel LG, Rego FM, Milano JB, Jung GS, Silva LF Jr, Ramina R. Spontaneous intracranial epidural hematoma during rivaroxaban treatment. *Rev Assoc Med Bras* (1992) 2016;62:721-4.