

Largest Intracranial Calcified Hydatid Cyst: A Case Report with Review of Literature

Abstract

Cerebral hydatid disease is a peculiar manifestation of echinococcosis, an infection acquired from *Echinococcus* tapeworm, in its larval stage. It symbolizes only 2% of all the cerebral space occupying lesions. It is frequently observed in children and young adults. In this paper, we report an exceptional case of intracranial solitary calcified hydatid cyst in a 25 year old male, shepherd by occupation, presenting with history of difficulty in walking and convulsions for the last 20 years. Craniotomy was carried out and an intact calcified mass weighing around 300 grams was excised. It is the largest intracranial calcified hydatid cyst excised till date and is first of its kind.

Keywords: Calcified, echinococcosis, hydatid cyst, intracranial

**Vivek Mahesh
Agrawal,
Pramod Janardan
Giri**

Department of Neurosurgery,
Super Speciality Hospital,
Nagpur, Maharashtra, India

Introduction

Hydatid disease, a cyclo-zoonotic infection induced by *Echinococcus* tapeworm, a larval form. In humans, the two predominant variety of hydatid disease are caused by *Echinococcus multilocularis*, and *Echinococcus granulosus*.^[1] Cerebral hydatid disease is infrequently observed, even in the endemic areas, depicting only 2% of all cerebral space occupying lesions.^[2] Infestation with *E. multilocularis* frequently leads to calcification, but is rarely observed with incidence being <1% of all the intracranial hydatid cysts. In the Indian subcontinent, it is prevalent in Tamil Nadu, Andhra Pradesh, and Punjab.^[2,3] In the present article, we report an exceptional case of largest solitary calcified cerebral hydatid cyst (~25.4 cm in diameter) in a young male with detailed review of literature.

Case Report

We present a case of a 25-year-old male patient, shepherd by occupation, native of Balaghat, Madhya Pradesh. He presented to our clinic with complaints of difficulty in walking and convulsions for the past 20 years. For all these years, he was being treated by a local physician and was misdiagnosed as a case of poliomyelitis.

Neurological examination had revealed muscle wasting and contracture of both limbs on the right side. Power was grade four. Speech and vision were normal. No other deficit was found. A noncontrast computed tomography (CT) of the brain revealed a well-defined spherical nonenhancing, hypodense, well-circumscribed, peripherally calcified 7 cm × 8 cm size space occupying lesion in the left frontoparietal region [Figure 1]. A contrast-enhanced magnetic resonance imaging (MRI) of the brain revealed nonenhancing intra-axial focal lesion with calcified walls [Figure 2a and b]. No restriction on diffusion was observed. Cyst wall appeared hypo-intense in all sequences with blooming area, suggestive of calcification. No perilesional edema was seen. Complete work-up of the patient was done but there was no presence of primary disease in other organs. The patient was operated with frontoparieto-temporal craniotomy. The mass was totally calcified and loosely adherent to dura matter. Through simple dissection, mass was excised in one piece without rupture and spillage. The weight of the cyst was around 300 g [Figure 3]. The longest and shortest diameter of the cyst were 25.4 cm and 23.9 cm, respectively [Figure 4a and b]. The cavity

Address for correspondence:

Dr. Vivek Mahesh Agrawal,
Flat No 202, Royal Crest Appts,
Purshottam Sathe Marg,
Dhantoli, Nagpur - 440 012,
Maharashtra, India.
E-mail: vivekmahesh
agrawal21@gmail.com

Access this article online

Website: www.asianjns.org

DOI: 10.4103/ajns.AJNS_143_20

Quick Response Code:



This is an open access journal, and articles are distributed under the terms of the Creative Commons Attribution-NonCommercial-ShareAlike 4.0 License, which allows others to remix, tweak, and build upon the work non-commercially, as long as appropriate credit is given and the new creations are licensed under the identical terms.

For reprints contact: WKHLRPMedknow_reprints@wolterskluwer.com

How to cite this article: Agrawal VM, Giri PJ. Largest intracranial calcified hydatid cyst: A case report with review of literature. *Asian J Neurosurg* 2020;15:713-5.

Submitted: 07-Apr-2020

Revised: 08-May-2020

Accepted: 11-Jun-2020

Published: 28-Aug-2020

was then irrigated with hypertonic saline jet. Ventricle was incidentally punctured leading to spilling of cerebrospinal fluid. Dura was closed primarily. There was no postoperative new neurological deficit. Histopathological examination revealed calcified hydatid cyst. The patient was discharged on 10th postoperative day after removal of the sutures and was prescribed tablet albendazole 400 mg BD for a month and advised regular follow-up.

Discussion

Hydatid cyst frequently involves liver (75%) followed by lung (15%). However, central nervous system is involved

in only 1% of the cases. It is generally diagnosed in children and young adults. Cyst can be located anywhere in the brain, but is usually found in the supratentorial compartment, supplied by the middle cerebral artery. Parietal region is most frequently affected, followed by the frontal region.^[2,4]

Cerebral hydatid cysts can be categorized as primary and secondary. The primary hydatid cysts grows as a result of the direct infestation of larvae in the brain, devoid of evidence of disease in other organs. Primary cysts incorporates scolices and brood capsules, thus are fertile and can lead to recurrence on rupture. Secondary hydatid cysts do not have brood capsule and scolices. They arise due to traumatic, spontaneous, or surgical rupture of primary hydatid cyst. They are infertile and thus, the chances of recurrence, as a result of rupture, are minimal.^[5]

Hydatid cyst starts producing symptoms only when they attain a large size. Its location is responsible for the appearance of the various symptoms. Majority of patients present with headache and vomiting.^[6] Almost all the cases of calcified hydatid cyst described in the literature presented with convulsions.^[4] Similarly, our patient had a history of convulsion for the past 20 years.

Imaging techniques such as CT and MRI are diagnostic of intracranial hydatid cyst. CT is suitable for distinguishing the cyst calcification, whereas cyst capsule is best demonstrated by MRI. In addition, MRI is beneficial in preparation of the patient for the surgery.^[2] However, histopathological examination forms the major basis for making the specific

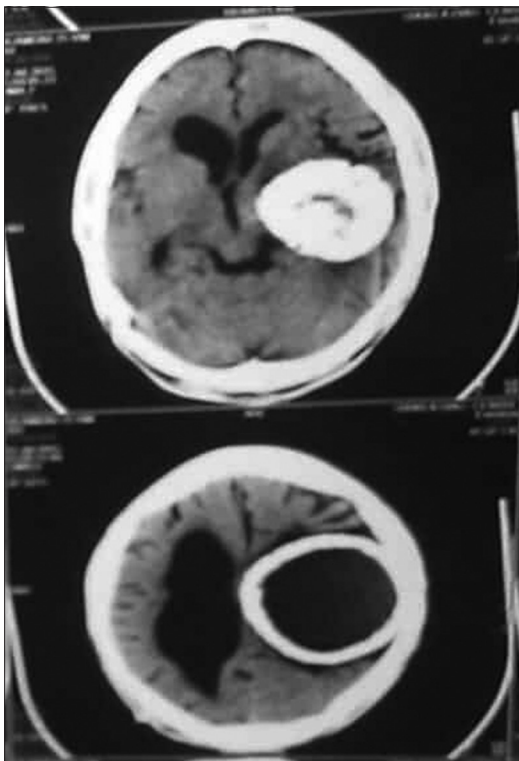


Figure 1: Computed tomography scan showing left frontoparietal mass (7 cm × 8 cm) with perilesional calcification

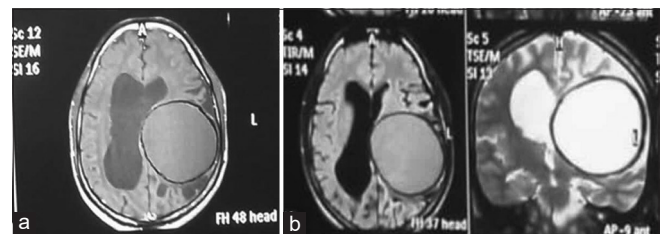


Figure 2: (a) T1-weighted magnetic resonance imaging shows images showing the left cystic mass with hypointensity in the posterosuperior wall consistent with perilesional calcification (b) T2-weighted magnetic resonance imaging shows nonenhancing intra-axial focal lesion with calcified wall

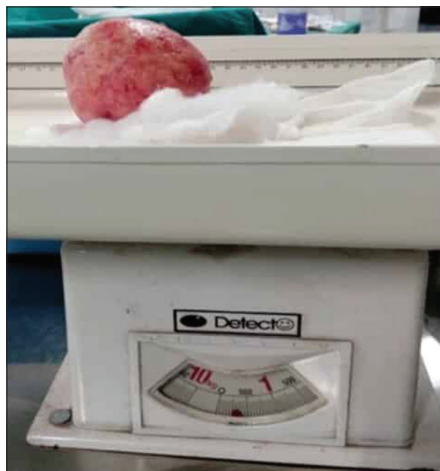

Figure 3: Weight of calcified hydatid cyst (~300 grams)

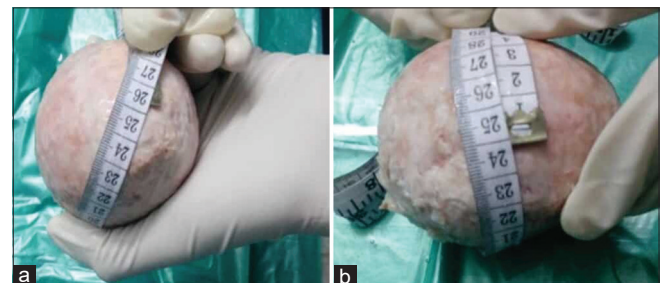


Figure 4: Dimensions of calcified hydatid cyst (a) Longest diameter of the cyst ~25.4 cm (b) Shortest diameter of the cyst ~23.9 cm

diagnosis of hydatid disease. Serological tests are commonly negative, when the cyst is calcified.^[7]

The differential diagnosis of intracranial hydatid cyst involves arachnoid cysts, porencephalic cysts, pyogenic abscess, and cystic tumor of the brain. Arachnoid cysts are not round in shape, are not covered by the brain tissue, and remain extra-axial. Porencephalic cysts are usually due to trauma to the normal brain parenchyma and are covered with white matter. Cystic tumors often have enhancement of soft-tissue components on imaging. Cerebral abscess show distinct central necrotic area, peripheral edema, and satellite lesions.^[2,8]

Primary treatment of hydatid cyst is surgical. The most desired procedure is Dowling technique. It includes Valsalva maneuver, gravity assisted removal of the cyst from the corticectomy site, and breaking the adhesions between brain parenchymal tissue and cyst wall with the help of hypertonic saline jet. Different surgical problems encountered includes extraction of the intact cyst to arrest the rupture, anaphylaxis, and recurrence of the cyst.^[9] Known postoperative complications includes obstructive hydrocephalus and subdural effusion. Chief reason of mortality during the procedure is anaphylactic reaction, as a result of the cyst rupture.^[8]

Albendazole in the form of drug treatment may be used for small multifocal cysts and presurgically to reduce the size of a large cyst. It is recommended as a four 1-month courses, with 15 days drug free intervals, in a dose of 10–15 mg/kg/day. It is parasitocidal and acts by blocking the uptake of glucose by larvae and adult parasites.^[8,10]

Our patient's case is unique in a sense that there was a presence of long standing history of complaints coupled with misdiagnosis, as a case of poliomyelitis, and intracranial solitary calcified hydatid cyst weighing 300 g, which is rare in the literature and first of its kind in India. Hydatid cyst in the brain without its presence in other organs has not been fully explained in the literature. This case is, thus, a primarily intracranial calcified hydatid cyst, a condition rare in adults.

Conclusion

An intracerebral calcified hydatid cyst is a rare entity with very few cases reported in literature. Hydatid disease should be considered when there is the presence of calcification and absence of contrast enhancement and perilesional

edema during CT brain, in patients living in endemic or nonendemic areas.

Declaration of patient consent

The authors certify that they have obtained all appropriate patient consent forms. In the form, the patient has given his consent for his images and other clinical information to be reported in the journal. The patient understands that name and initials will not be published and due efforts will be made to conceal identity, but anonymity cannot be guaranteed.

Financial support and sponsorship

Nil.

Conflicts of interest

There are no conflicts of interest.

References

1. Vikas S, Preety S, Sanjeev P. Cerebral hydatid cyst: A case report. *Acta Med Int* 2016;3:207-9.
2. Bükte Y, Kemaloglu S, Nazaroglu H, Ozkan U, Ceviz A, Simsek M. Cerebral hydatid disease: CT and MR imaging findings. *Swiss Med Wkly* 2004;134:459-67.
3. Tyagi DK, Balasubramaniam S, Sawant HV. Primary calcified hydatid cyst of the brain. *J Neurosci Rural Pract* 2010;1:115-7.
4. Köktekir E, Erdem Y, Gökçek C, Karatay M, Yılmaz A, Bayar MA, *et al*. Calcified intracranial hydatid cyst: Case report. *Türkiye Parazitoloj Derg* 2011;35:220-3.
5. Gupta S, Desai K, Goel A. Intracranial hydatid cyst: A report of five cases and review of literature. *Neurol India* 1999;47:214-7.
6. Ozkan U, Kemaloglu M, Selcuki M. Gigantic intracranial mass of hydatid cyst. *Child's Nerv Syst* 2001;17:623-5.
7. Kilani M, Nsir AB, Gannouni C, Zemmali M, Darmoul M, Hattab N. Intracranial calcified hydatid cyst mimicking primary brain tumor. *Int J Clin Med Res* 2015;2:1-3.
8. Angın T, Çelebisoy M, Karatepe AN, Gelal MF, Şirin HK. Cerebral hydatid cyst: A case report. *Turk J Neurol* 2014;20:87-90.
9. Sharma V, Sharma A, Sharma M, Sharma A, Khajuria A. Primary intracranial multiple hydatid cysts in an adult. *Int J Med Public Health* 2015;5:247-9.
10. Kalaitzoglou I, Drevelengas A, Petridis A, Palladas P. Albendazole treatment of cerebral hydatid disease: Evaluation of results with CT and MRI. *Neuroradiology* 1998;40:36-9.