

Endoscopic Microvascular Decompression for Hemifacial Spasm

Abstract

Introduction and Objective: Hemifacial spasm (HFS) is a condition, characterized by painless, involuntary unilateral tonic or clonic contractions of the facial muscles innervated by the ipsilateral facial nerve. HFS starts with contractions in the orbicularis oculi muscle with subsequent eyelid closure and/or eyebrow elevation, but may spread to involve muscles of the frontalis, platysma, and orbicularis oris muscles. Microvascular decompression (MVD) is reliable and accepted surgical treatment for HFS. MVD is the standard surgical technique now for HFS treatment with long-term success rates. **Materials and Methods:** We performed fully endoscopic MVD technique for 1 patient with HFS (a 83-year-old female) at our institution. HFS was diagnosed based on the clinical history and presentation, a neurologic examination, and additional imaging findings. Respectively, the durations of HFS were 3 years, respectively. The patient had been previously treated with repeated botulinum toxin injections. Preoperative evaluation was done with magnetic resonance imaging; three-dimensional computed tomography fusion images examinations had identified the anterior inferior cerebellar artery (AICA) as the offending vessel in this patient. **Results:** The patient with HFS was treated by fully endoscopic MVD technique. The AICA, which had been identified as the offending vessel by preoperative magnetic resonance imaging, was successfully decompressed. No surgery-related complications occurred and had excellent outcomes with the complete resolution of HFS immediately after the operation. **Conclusions:** Endoscopic surgery can provide a more panoramic surgical view than conventional microscopic surgery. Fully endoscopic MVD is both safe and effective in the treatment of HFS. This method minimizes the risks of brain retraction and extensive dissection often required for microscopic exposure. Endoscopic MVD is safe and has advantage over microscope in terms of visualization of structure, identification of neurovascular conflict, but it has a learning curve and technically challenging.

Keywords: Endoscope, facial nerve root exit zone, hemifacial spasm, microvascular decompression

Introduction

Hemifacial spasm (HFS) is a condition characterized by painless, involuntary unilateral tonic or clonic contractions of the facial muscles innervated by the ipsilateral facial nerve.^[1-3] HFS starts with contractions in the orbicularis oculi muscle with subsequent eyelid closure and/or eyebrow elevation, but may spread to involve muscles of the frontalis, platysma, and orbicularis oris muscles.^[2,4] In its most severe form, HFS can be a disfiguring, sustained grimace, partial closing of the eyes and lifting of the mouth, described as a “tonus phenomenon,” curvature of the face can impair vision and facial expression.^[5] Involuntary facial movements have various psychosocial consequences for patients can be very debilitating and lead to a general decrease in the quality of life.^[6,7]

This is an open access journal, and articles are distributed under the terms of the Creative Commons Attribution-NonCommercial-ShareAlike 4.0 License, which allows others to remix, tweak, and build upon the work non-commercially, as long as appropriate credit is given and the new creations are licensed under the identical terms.

For reprints contact: WKHLRPMedknow_reprints@wolterskluwer.com

Patients often report exacerbation of symptoms with fatigue, anxiety, and/or head movement. Most cases of HFS occur unilaterally; it is estimated that between 0.6% and 5% occurs bilaterally.^[8] One study also found that headaches associated with HFS were connected with the increased severity of spasm.^[9]

Two classified types of HFS are currently described: primary, due to neurovascular compression (NVC) of the facial nerve, and secondary, which comprises all other types of damage to the facial nerve.^[4] Secondary HFS has been reported through a variety of mechanisms, including cerebellopontine angle masses, arteriovenous malformations, enterogenous cysts, and aneurysms.^[2,7-9]

However, in the vast majority of patients, HFS is caused by NVC at the facial nerve root exit zone (REZ) in the posterior fossa.

How to cite this article: Matmusaev M, Kumar RS, Yamada Y, Nagatani T, Kawase T, Tanaka R, et al. Endoscopic microvascular decompression for hemifacial spasm. *Asian J Neurosurg* 2020;15:833-8.

Submitted: 10-Apr-2020

Revised: 02-May-2020

Accepted: 28-May-2020

Published: 18-Oct-2020

Maruf Matmusaev,
R. Senthil Kumar¹,
Yasuhiro Yamada²,
Tetsuya Nagatani³,
Tsukasa Kawase²,
Riki Tanaka²,
Miyatani Kyosuke²,
Yoko Kato²

Republican Specialized Scientific and Practical Medical Center of Neurosurgery, Tashkent, Uzbekistan, ¹Department of Neurosurgery, Royal Care Super Speciality Hospital, Coimbatore, Tamil Nadu, India, ²Department of Neurosurgery, Banbuntane Hotokukai Hospital, Fujita Health University, ³Department of Neurosurgery, Japanese Red Cross Nagoya Daini Hospital, Nagoya, Japan

Address for correspondence:

Dr. Maruf Matmusaev,
Republican Specialized Scientific and Practical Medical Center of Neurosurgery,
Tashkent, Uzbekistan.
E-mail: marufmatmusaev@gmail.com

Access this article online

Website: www.asianjns.org

DOI: 10.4103/ajns.AJNS_152_20

Quick Response Code:



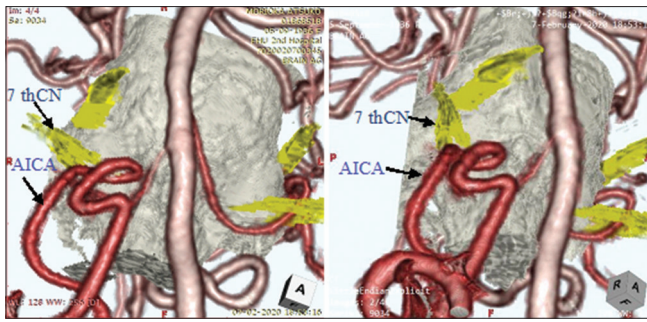


Figure 1: Three dimensional computed tomography brain showing neurovascular conflict Facial nerve compressed by anterior inferior cerebellar artery

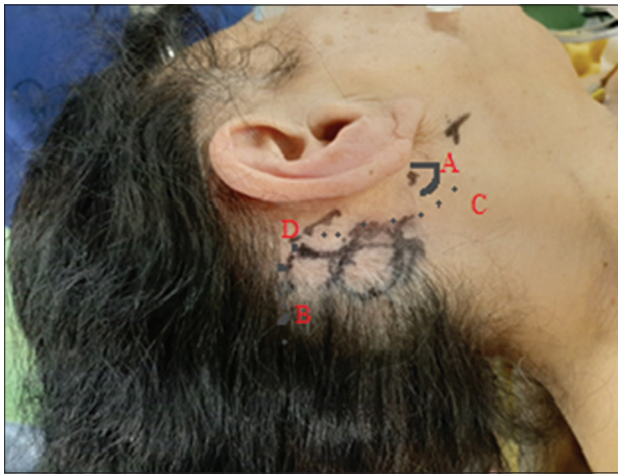

Figure 3: Anatomical landmarks: A: Tip of mastoid process. B and D: Course of transverse sinus. C and D: course of sigmoid sinus

The anterior inferior cerebellar artery (AICA), posterior inferior cerebellar artery, and vertebral artery (VA) are the most frequently implicated vessels in HFS.^[3,7,10,11]

The microvascular decompression (MVD) for neurovascular conflict was first described by Dandy in 1934 and Jannetta *et al.* in 1970s popularized the surgical technique.^[12] MVD is reliable and accepted surgical treatment for HFS. MVD is the standard surgical technique now for HFS treatment with long-term success rates.^[13] The utility of endoscope in neurosurgery is increasing nowadays, endoscope was used as an adjuvant to microscope in posterior fossa surgery. Only limited data are available about fully endoscopic MVD for HFS.^[13]

Here, we report the case of HFS treated by endoscopic microvascular decompression, describing the advantages of fully endoscopic MVD.

Materials and Methods

Patient

We performed fully endoscopic MVD technique for 1 patient with HFS (a 83-year-old female) at our institution. HFS was diagnosed based on the clinical history and presentation, a neurologic examination, and

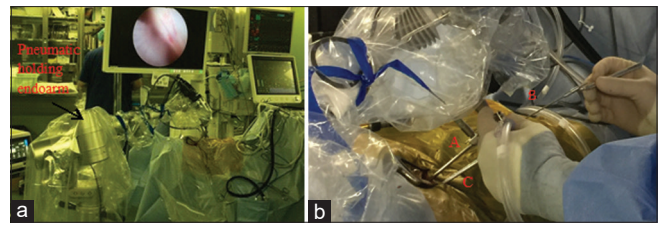


Figure 2: (a) operative room setup. (b) Placement of the endoscope A, the suction C and dissector B should be arranged in a triangle to avoid clashing of instruments

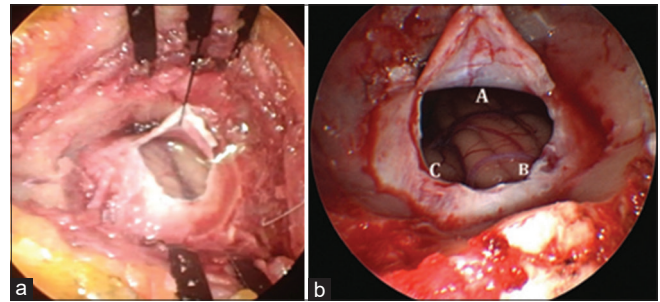


Figure 4: (a) Endoscopic view of craniectomy for E-microvascular decompression of the facial nerve. The dura mater has been opened and reflected toward the sigmoid sinus. (b) Placement of the endoscope 12 o'clock (point A), microinstrument at 5 o'clock (B) and suction at 7 o'clock (C)

additional imaging findings. Respectively, the durations of HFS were 3 years, respectively. The patient had been previously treated with repeated botulinum toxin injections. Preoperative evaluation was done with magnetic resonance imaging; three dimensional computed tomography fusion images examinations had identified the AICA as the offending vessel in this patient [Figure 1].

Surgical steps

For surgery, 4-mm 0°-and 30° rigid endoscopes were used (Olympus, Tokyo, Japan). The Endo Arm (Olympus, Tokyo, Japan) endoscope was used; it is designed to move smoothly and steadily, using a fixed floor-standing pneumatic system [Figure 2a], and a bimanual technique was performed with single-shaft instruments. A brain retractor was not used. Transposition was performed using a Teflon felt string and fibrin glue.

The surgery was performed under general anesthesia by endotracheal intubation. The patient was placed in a supine position with the ipsilateral shoulder raised by a pillow, and the patient's head was rotated 90° to the contralateral side and fixed in a Sugita 4-point head holder (Mizuho Medical Innovation, Tokyo, Japan).

Surgical steps are slight modifications of the standard retrosigmoid approach for MVD. Anatomical landmarks are very important in every step of the surgery. Small linear incision was made slight behind the pinna. Mastoid process and mastoid tip are very important landmarks, which are defined after deepening skin incision to bone depth. The

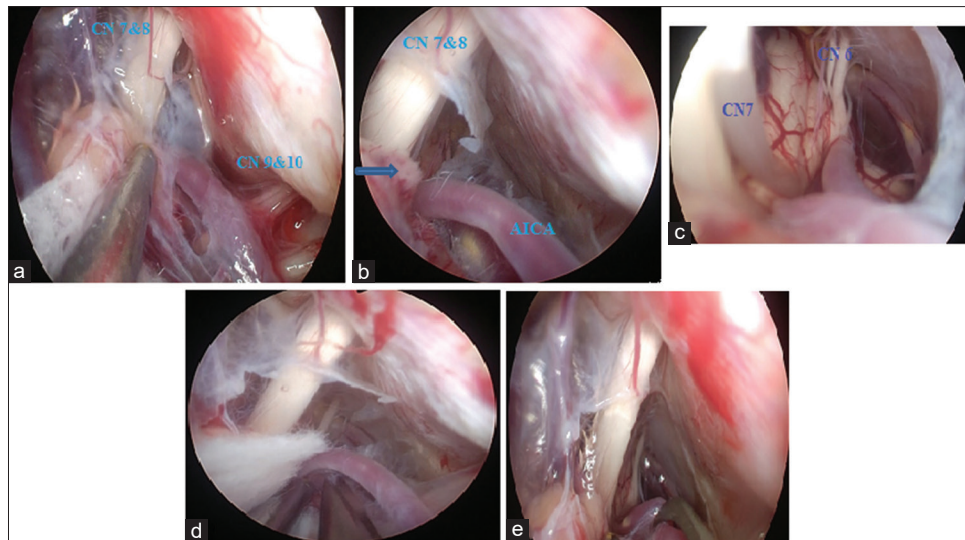


Figure 5: Fully endoscopic procedures. (a-c) The acousticofacial bundle is visualized, and the facial nerve and offending vessels were identified. (d and e) Right anterior inferior cerebellar artery is dissected from the root exit zone of the right facial nerve (cranial nerve 7) under the endoscopic view. Neurovascular conflict

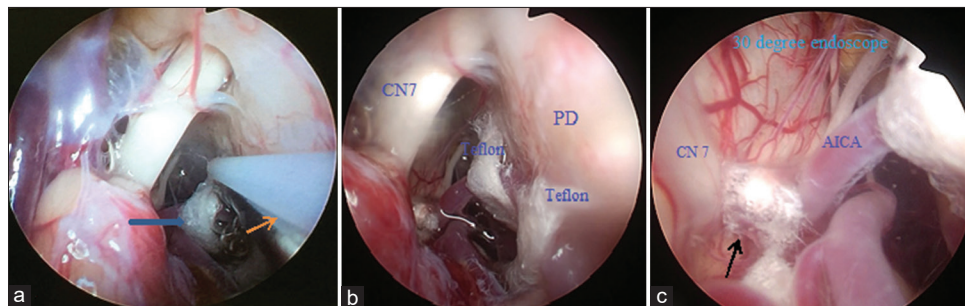


Figure 6: (a and b) Intraoperative photograph showing transposition of vessel (anterior inferior cerebellar artery) with Teflon loop and stuck to the petrosal dura mater with fibrin glue. Petrosal dura mater. (c) A final survey surgery using a 30° endoscope was conducted to evaluate the adequacy of the decompression. Teflon pledget (black arrow) is placed between the root exit zone of cranial nerve 7 and the anterior inferior cerebellar artery under the endoscopic view

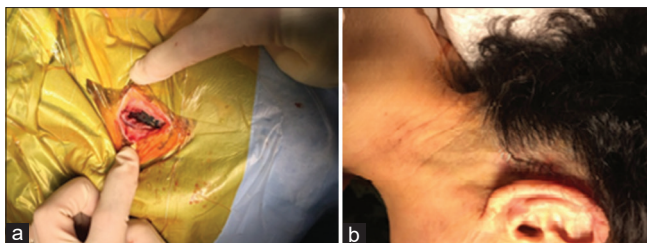


Figure 7: (a) Small incision and craniotomy with plate. (b) Small incision after closure

insertion of posterior belly of digastric muscle, digastric notch, and mastoid emissary vein are other useful landmarks. The course of the transverse sinus is marked byinion to external auditory meatus line. The course of the sigmoid sinus is marked by a line drawn along the posterior border of mastoid process [Figure 3]. Single burr hole is placed close to the junction of the sigmoid and transverse sinus. The burr hole is enlarged to 2–2.5 cm wide craniectomy using high speed drill.

For a fully endoscope MVD, pneumatic arm was placed on the left side of surgeon, zero degree 4.0 mm endoscope was

fixed to pneumatic arm. Under endoscope, 1 cm, C-shaped durotomy was made, dura reflected toward sigmoid sinus [Figure 4].

The endoscope, the suction and dissector should be arranged in a triangle to avoid the clashing of instruments [Figure 2b]. The endoscope is placed at 12 o'clock position to obtain a panoramic view. Suction in the left hand at 7 o'clock position. Suction tube tip is 2 mm diameter, malleable and 12 cm length with irrigation. Dissector in the right hand at 5 o'clock position [Figure 4]. Size of dissector, tip angled 15° or 30°, width 1 mm, working length 10 cm or 13 cm. We have designed 0° dissector also which is extremely useful in some selected situation. With gentle retraction of the cerebellum, careful arachnoid dissection should be carried out. This will allow gradual CSF egress and this will provide corridor to the cerebellopontine angle region.

A brain retractor is not necessary as CSF drainage will provide adequate space. Using a brain retractor will interfere with movement of instruments in the available corridor.

Facial nerve is identified and looked for conflict. Gentle dissection of the arachnoid place will allow separation of the vessel from the nerve.

Initially, the nerve compression by the offending vessel around the nerve REZ was systematically inspected using a 0° endoscope. The 30° endoscope provides a more panoramic surgical view, allowing for the identification of the precise location of the neurovascular conflict [Figure 5].

The nerve should be adequately decompressed by either interposition of the graft or by transposition of the vessel. When the offending vessel can mobilized well, it can be transposed with Teflon loop and stucked to the petrosal dura mater with fibrin glue [Figure 6].

The dura should be closed in a watertight fashion, mastoid air cells if opened should be waxed and then dural sealant was applied to prevent postoperative CSF leakage. The bone defect is closed either with bone dust and titanium plate and wound closed in layers [Figure 7]. Fixing the endoscope to pneumatic arm allows bimanual dexterity, it stabilizes the endoscope to prevent unintended injury to the surrounding structures and trajectory can be adjusted throughout the procedure.

The smaller diameter endoscope minimizes brain retraction, instrument clash, and it allows more working space for the other instruments.

As you know, the endoscopic approach is difficult due to scanty sizes. It follows that the tools used in this process should be miniature, convenient, and of course high-quality.

The most needed and frequently used instruments in the endoscopic approach are HOPKINS: Straight Forward Telescope 0° and Forward-Oblique Telescope 30°, enlarged view, diameter 4 mm, length 18 cm, micro scissors, horizontal, bayonet-shaped, sharp/sharp, straight, working length 10 cm. Dissector tip is angled 15° or 30°, width 1 mm, working length 10 cm or 13 cm. Suction tube tip is 2 mm diameter, malleable and 12 cm length with irrigation and Pneumatic holding system.

Results

The patient with HFS was treated by fully endoscopic MVD technique. The AICA, which had been identified as the offending vessel by preoperative magnetic resonance imaging, was successfully decompressed. No surgery-related complications occurred and had excellent outcomes with the complete resolution of HFS immediately after the operation.

Discussion

The endoscope has rapidly become a standard operative tool in minimally invasive neurosurgery of the sella, parasellar lesions, and ventricular system due to the panoramic views and bright lightening and having no blocks or dead corner in the surgical field.^[14-16]

Flanders *et al.*^[17] in 2018 published a retrospective study of 27 patients who underwent fully endoscopic MVD and attempted to demonstrate the efficacy and safety of fully endoscopic MVD. They found complete and near-complete relief of symptoms in 60.7% and 14.3% of the cases, respectively comparable to MVD literature.^[18,19] The neurovascular conflict was visualized in 100% of the cases in this study. Sharma *et al.*^[20] in 2017 did a systematic review to determine the long-term efficacy of MVD. They attempted to compile the results of studies published between January 1992 and December 2015. They found MVD is an effective treatment modality with good long-term benefits in 88.5% of the patients. We could obtain only very few data from this study regarding the utility of endoscope in MVD for HFS. No fully endoscopic MVD data are available in the past 25 years.

Advantages

Even though excellent clinical outcomes can be obtained using microscope alone, the ability of the operating microscope to view the deep structures has limitations in terms of obtaining viewing angle. In contrast, the endoscope provides very good illumination, and good visualization view obtained is panoramic. Endoscope can be adjusted to view different angles and helps to view corners than a microscope. The endoscope can be used alone or as an adjuvant to the microscope in HFS. Endoscope helps to identify the hidden compression more easily as compared to the microscope.

The endoscope enables complete visualization of the surgical field of interest. Microscopic MVD usually requires large craniotomy as compared to endoscopic MVD, and it may require increased cerebellar retraction which, in turn, causes traction on the cranial nerves.

Furthermore, another advantage was mentioned by Komatsu *et al.*,^[21] that A 30° endoscopic view through the petrosal surface of the cerebellum through a retrosigmoid keyhole clearly demonstrates the neurovascular structures and relationship around the supraolivary fossette behind the flocculus. The REZ of the facial nerve is readily identified after mobilization of the AICA as the offending artery.

As well as, the endoscope also clearly demonstrates small perforators even behind obstacles^[22] and secure recognition of perforators contributes to avoidance of injury during decompression procedures, especially for the transposition technique.

Limitations of endoscope

An endoscope has also couple limitations. Let's count most frequent occurrences cases: First, limitations of view. During manipulation with MVD an invisible review of the whole picture of what is happening because an endoscope provides two-dimensional information and has no sense of depth and it provides only a front vision, making it impossible to look

for bilateral and posterior structures. Second, inconvenient to use. As that one hand needs to hold an endoscope and the other to manipulate, and one-handed manipulation causes some difficulties during surgery. Third, danger during operation. Surrounding structures may be injured when the position and angle of the endoscope are changed. At last, bleeding can spoil the endoscope lens, affecting the quality of the endoscopic images. These disadvantages has also been described in other articles.^[16,22,23]

We currently postulate contraindication for this surgery includes repeated surgery and very tortuous VA which seems to be the responsible.

Challenges

An endoscope is undoubtedly one of the convenient ways. However, for novice surgeons, it can cause some difficulties that eventually disappear with the advent of skills. To improve the skills of working on an endoscope, a young neurosurgeon should train at cadaver laboratories, also live surgery very important, more aperture under supervision of older and more experienced mentors neurosurgeons to prevent the complications during surgery and after surgery period. What we want to stress on as the advantage of purely endoscopic MVD is that it provides seamless procedure during the entire surgery.

The use of endoscope in the posterior fossa has a steep-learning curve. Posterior fossa structures are delicate to handle into contrast to other endoscopic skull base approaches. No natural access corridor lateral to the cerebellar hemisphere use of the endoscope compromise sacrifices binocular vision provided by microscope and is technically demanding. In endoscope-assisted surgery, the surgeon has to hold the endoscope in one hand and do the manipulation in the other hand.

We believe that scope holder is a feasible solution to solve this problem; however, no scope holder currently available in this country is perfect. Their drawbacks include size and maneuverability, both of which are the cause of difficulty for the assistant surgeon to move the scope to fix in the proper position like as three-hand technique in pituitary surgery. We think in the future scope holder should have a function of stereotaxy to some extent.

Ideally, a modern surgeon should be proficient in modern techniques. As they say, “the future is here and now.” Today’s tools and techniques are very effective. But still, there is no limit to perfection. Three main ways of further development: minimizing injuries– technologies become even less invasive; the appearance of robots which have a number of advantages, and finally, all that is connected with modern information technologies.

Conclusions

Endoscopic surgery can provide a more panoramic surgical view than conventional microscopic surgery.

Fully endoscopic MVD is both safe and effective in the treatment of HFS. This method minimizes the risks of brain retraction and extensive dissection often required for microscopic exposure. Endoscopic MVD is safe and has advantage over microscope in terms of visualization of structure, identification of neurovascular conflict, but it has a learning curve and technically challenging. Endoscopic surgery allows the surgeon to avoid perforating artery and cranial nerves injury during decompression. The scope holder is a feasible solution to solve this problem of “busy hands” inconvenience situation.

To summarize, instruments dedicated to endoscopic keyhole approach should be required to be thin sized, malleable, and some rigidity.

Financial support and sponsorship

Nil.

Conflicts of interest

There are no conflicts of interest.

References

1. Wilkins RH. Hemifacial spasm: A review. *Surg Neurol* 1991;36:251-77.
2. Wang A, Jankovic J. Hemifacial spasm: Clinical findings and treatment. *Muscle Nerve* 1998;21:1740-7.
3. Campos-Benitez M, Kaufmann AM. Neurovascular compression findings in hemifacial spasm. *J Neurosurg* 2008;109:416-20.
4. Lu AY, Yeung JT, Gerrard JL, Michaelides EM, Sekula RF Jr., Bulsara KR. Hemifacial spasm and neurovascular compression. *ScientificWorldJournal* 2014;2014:349319.
5. Sekula RF Jr., Bhatia S, Frederickson AM, Jannetta PJ, Quigley MR, Small GA, *et al.* Utility of intraoperative electromyography in microvascular decompression for hemifacial spasm: A meta-analysis. *Neurosurg Focus* 2009;27:E10.
6. Bigder MG, Kaufmann AM. Failed microvascular decompression surgery for hemifacial spasm due to persistent neurovascular compression: An analysis of reoperations. *J Neurosurg* 2016;124:90-5.
7. Teton ZE, Blatt D, Holste K, Raslan AM, Burchiel KJ. Utilization of 3D imaging reconstructions and assessment of symptom-free survival after microvascular decompression of the facial nerve in hemifacial spasm. *J Neurosurg* 2019;1-8.
8. Felício AC, Godeiro-Junior Cde O, Borges V, Silva SM, Ferraz HB. Bilateral hemifacial spasm: A series of 10 patients with literature review. *Parkinsonism Relat Disord* 2008;14:154-6.
9. Peeraully T, Tan SF, Fook-Chong SM, Prakash KM, Tan EK. Headache in hemifacial spasm patients. *Acta Neurol Scand* 2013;127:e24-7.
10. Park JS, Koh EJ, Choi HY, Lee JM. Characteristic anatomical conformation of the vertebral artery causing vascular compression against the root exit zone of the facial nerve in patients with hemifacial spasm. *Acta Neurochir (Wien)* 2015;157:449-54.
11. Sindou M, Mercier P. Microvascular decompression for hemifacial spasm: Surgical techniques and intraoperative monitoring. *Neurochirurgie* 2018;64:133-43.
12. Jannetta PJ, Abbasy M, Maroon JC, Ramos FM, Albin MS. Etiology and definitive microsurgical treatment of hemifacial spasm. Operative techniques and results in 47 patients. *J Neurosurg* 1977;47:321-8.

13. Dannenbaum M, Lega BC, Suki D, Harper RL, Yoshor D. Microvascular decompression for hemifacial spasm: Longterm results from 114 operations performed without neurophysiological monitoring. *J Neurosurg* 2008;109:410-5.
14. Jho HD, Carrau RL. Endoscopy assisted transsphenoidal surgery for pituitary adenoma. Technical note. *Acta Neurochir (Wien)* 1996;138:1416-25.
15. Adappa ND, Learned KO, Palmer JN, Newman JG, Lee JY. Radiographic enhancement of the nasoseptal flap does not predict postoperative cerebrospinal fluid leaks in endoscopic skull base reconstruction. *Laryngoscope* 2012;122:1226-34.
16. Nagata Y, Watanabe T, Nagatani T, Takeuchi K, Chu J, Wakabayashi T. The Multiscope Technique for Microvascular Decompression. *World Neurosurg* 2017;103:310-4.
17. Flanders TM, Blue R, Roberts S, McShane BJ, Wilent B, Tambi V, *et al.* Fully endoscopic microvascular decompression for hemifacial spasm. *J Neurosurg* 2018;131:813-9.
18. Hanakita J, Kondo A. Serious complications of microvascular decompression operations for trigeminal neuralgia and hemifacial spasm. *Neurosurgery* 1988;22:348-52.
19. Kureshi SA, Wilkins RH. Posterior fossa reexploration for persistent or recurrent trigeminal neuralgia or hemifacial spasm: Surgical findings and therapeutic implications. *Neurosurgery* 1998;43:1111-7.
20. Sharma R, Garg K, Agarwal S, Agarwal D, Chandra PS, Kale SS, *et al.* Microvascular decompression for hemifacial spasm: A systematic review of vascular pathology, long term treatment efficacy and safety. *Neurol India* 2017;65:493-505.
21. Komatsu F, Imai M, Hirayama A, Hotta K, Hayashi N, Oda S, *et al.* Endoscopic microvascular decompression with transposition for trigeminal neuralgia and hemifacial spasm: Technical note. *J Neurol Surg A Cent Eur Neurosurg* 2017;78:291-5.
22. Ishikawa M, Tanaka Y, Watanabe E. Microvascular decompression under neuroendoscopic view in hemifacial spasm: Rostral-type compression and perforator-type compression. *Acta Neurochir (Wien)* 2015;157:329-32.
23. Abolfotoh M, Bi WL, Hong CK, Almefty KK, Boskovitz A, Dunn IF, *et al.* The combined microscopic-endoscopic technique for radical resection of cerebellopontine angle tumors. *J Neurosurg* 2015;123:1301-11.