

Compound Elevated Skull Fracture Presented as a New Variety of Fracture with Inimitable Entity: Single Institution Experience of 10 Cases

Abstract

Background: Compound elevated skull fracture (CESF) is a rare variety of fracture with rare presentation in comparison to other type of skull fracture. The mechanical force being applied is tangential causing high impact over skull as comparison to structure underlying the cranium. **Objective:** Aims of this study are bring attentiveness and management to deal this rare type of fracture and its outcomes. **Materials and Methods:** In this study, we demonstrated 10 cases of CESF in adult patients from January 2014 to January 2018 in the Department of Neurosurgery at RNT Medical College and M. B. Hospital, Udaipur, Rajasthan, India. Recorded documents were prospectively studied for age of distribution, sex, mode of injury, mechanism of injury, clinical profile, radiological investigations, neurosurgical management, and outcome asses by Glasgow outcome scale. **Results:** Totally 10 patients had CESF. Six are males and four are females. Male to female ratio was 3:2. Their age range was 20–45 years. The most common mode of injury was Road traffic accident in 60%. Wound exploration, cleaning, debridement, and reduction of fracture segment was done in eight cases, frontal bone craniotomy with evacuation of pneumocephalus done one case, frontal bone craniotomy, and extradural hematoma evacuation was done in one case. The postoperative course was uneventful, and outcome was good (GOS 5) in 8 (80%) cases. **Conclusion:** In compound elevated fracture, early recognition and immediate surgical intervention should be done to avoid related morbidity and mortality. Any delay in surgery may lead to a high possibility of wound infection and poor outcome.

Keywords: Compound, elevated, fracture skull, Glasgow Outcome Score

Introduction

Elevated skull fracture is an atypical type of fracture with very few cases has been reported in different literature. The classification of skull bone fracture is based on type (open fracture and closed fracture), site (depressed fracture and basal fracture), and pattern (linear, diastatic, and comminuted).^[1] The different variety of fracture depends on the shape of impacting object, mechanism of force, and site of impact over skull. In 1650–1550 BC, elevated fracture of skull was first described in the renowned surgical treatise “The Edwin Smith surgical papyrus.”^[2] It was described as fracture in which fractured fragment is elevated above the level of the intact skull.^[3] Owing to the rarity of occurrence or neglect, this fracture remained unreported in surgical texts till as late as 1976 when Ralston mentioned its occurrence and reviewed the pathology.^[4]

It can be caused during an assault with a weapon where the initial blow penetrates the skull and the underlying meninges, and on withdrawal, the weapon lifts the fractured portion of the skull outward. It can also be caused the skull rotating while being struck in a case of blunt force trauma, the skull rotating while striking an inanimate object as in a fall, or it may occur during transfer of a patient after an initial compound head injury.

Materials and Methods

This is a prospective study conducted over period of 4 years from January 2014 to January 2018 at tertiary care center in the Department of neurosurgery at RNT Medical College and M. B. Hospital, Udaipur, Rajasthan, India. During this period, the total patient admitted of head injury is 10951, so the incidence of compound elevated skull fracture (CESF) in our series is 0.091% which is very less compared to previous literature.

This is an open access journal, and articles are distributed under the terms of the Creative Commons Attribution-NonCommercial-ShareAlike 4.0 License, which allows others to remix, tweak, and build upon the work non-commercially, as long as appropriate credit is given and the new creations are licensed under the identical terms.

For reprints contact: reprints@medknow.com

How to cite this article: Kumar A, Kankane VK, Jaiswal G, Kumar P, Gupta TK. Compound elevated skull fracture presented as a new variety of fracture with inimitable entity: Single institution experience of 10 cases. *Asian J Neurosurg* 2019;14:410-4.

**Ashok Kumar,
Vivek Kumar Kankane,
Gaurav Jaiswal,
Pavan Kumar,
Tarun Kumar Gupta**

*Department of Neurosurgery,
RNT Medical College, Udaipur,
Rajasthan, India*

Address for correspondence:
Dr. Vivek Kumar Kankane,
Department of Neurosurgery,
RNT Medical College,
Udaipur, Rajasthan, India.
E-mail: vivekkankane9@gmail.com

Access this article online

Website: www.asianjns.org

DOI: 10.4103/ajns.AJNS_153_18

Quick Response Code:



Recorded documents were prospectively studied for age of distribution, sex, mode of injury, site of injury, mechanism of injury, clinical profile, radiological investigations, neurosurgical management, and outcome asses by Glasgow Outcome Scale at the time of discharge and at the age of 6 months. Postoperatively, the patients were followed up clinically and radiologically at a regular interval. Postoperative computed tomography (CT) scan was performed in the immediate postoperative period.

Results

During this period, total patients admitted of head injury are 10951. Out of which 10 patients had CESF, six are males and four are females. Male to female ratio was 3:2. Their age range was 20–45 years (mean age 31.1 years). Six patients were lies in 20–30 years of age group, three were in between 31–40 years, while one patient was 45 years old [Table 1]. The most common mode of injury was Road traffic accident (RTA) in 60% ($n = 6$) followed by fall from height in 20% ($n = 2$) and Assault in 20% ($n = 2$) by sharp-edged objects (sword) [Table 2]. The fracture was compound type in all 10 patients. All of them had scalp wound directly overlying the calvarial fracture segment, and scalp wound length range was 5–15 cm, dural tears were seen in two out of ten patients. After hemodynamic stabilization, all patients underwent the Noncontrast Computed Tomography (NCCT) brain with bone window.

Table 1: Age distribution

Age range (years)	n (%)
20-30	6 (60)
31-40	3 (30)
41-50	1 (10)

Table 2: Mode of injury

Manner of injury	n (%)
Road traffic accident	6 (60)
Assault	2 (20)
Fall from height	2 (20)

Table 3: Clinical-radiological condition and Glasgow Outcome Score at the time of discharge and age 6 month

GCS	Radiological finding	GOS score at the time of discharge	GOS score at 6 months
E4V5M6	Elevated right frontal bone fracture with bilateral pneumocephalus	5	5
E4V5M6	Elevated right frontal bone fracture	5	5
E4V5M6	Elevated right parietal bone fracture	5	5
E4V5M6	Elevated right parietal bone fracture with underlying ICH	5	5
E2V3M5	Elevated right frontal bone fracture with bilateral pneumocephalus	5	5
E3V5M6	Elevated right frontal bone fracture	5	5
E2V3M5	Elevated right frontal bone fracture with underlying contusion	5	5
E2V3M4	Elevated right frontal bone fracture with pneumocephalus and contusion	1	1
E2V3M4	Elevated right parietal bone fracture with pneumocephalus	3	4
E2V2M5	Elevated right frontal bone fracture with underlying EDH	5	5

EDH – Epidural hemorrhage; ICH – Intracranial hematoma; GCS – Glasgow Coma Scale Score; GOS – Glasgow Outcome Score

Wound exploration, cleaning, debridement, and reduction of fracture segment were done in eight cases, frontal bone craniotomy and extradural hematoma removal were done in one case, frontal bone craniotomy with evacuation of pneumocephalus was done one case postoperative course was uneventful and outcome was good (GOS 5) in 8 (80%) cases.

At the time of presentation, five patients had mild head injury (Glasgow Coma Scale Score (GCS 13–15), five had moderate head injury (GCS 9–12) [Table 3]. Elevated frontal bone fracture on the right side is seen in 7 (70%) patients, whereas parietal bone fracture was seen in 3 (30%) cases [Table 3]. Among the associated NCCT head finding, pneumocephalus [Figure 1a] was most common, present in three cases followed by contusion in two cases, extradural hematoma in one case and intracranial hematoma in one case. The dural tear was seen in two patients.

Frontal bone craniotomy with evacuation of pneumocephalus was done one case [Figure 1a, b and c] whereas exploration, cleansing, debridement, and reduction of fracture segment were done in 8 cases [Figures 2a-c, 3, 4a, b, 5 and 6].

Good recovery was noted in 8 (80%) cases (GOS 5) [Table 3], severe disability seen in one patient which was admitted for prolong time and improvement was delayed due poor GCS score at time of admission (GOS 3 at the time of discharge and GOS 4 at 6-month follow-up), and one patient was expired (GOS 1) [Table 3] because of poor GCS during admission and ventilator-associated pneumonia. All nine patients are on a regular follow-up recovered well.

Discussion

The principles for the management for all type of fracture either CESFs or other type of skull fracture are same that is, early diagnosis and prompt intervention with the use of broad-spectrum antibiotics, wound debridement, and irrigation, removal of the foreign body and loose bone fragments and watertight dural repair.^[4-7] Whenever delay

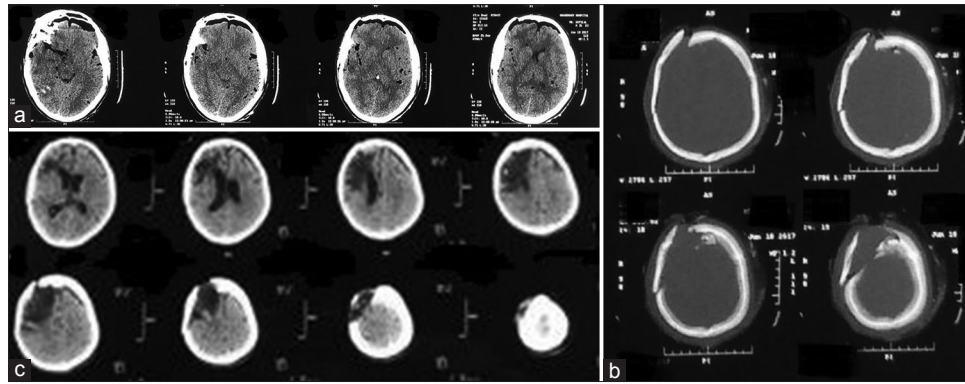


Figure 1: (a) Noncontrast Computed Tomography head showing right frontal bone elevated fracture with bilateral pneumocephalus, (b) Noncontrast Computed Tomography Head bone window showing right frontal bone elevated fracture, (c) postoperative Noncontrast Computed Tomography scan showing reduced fracture segment

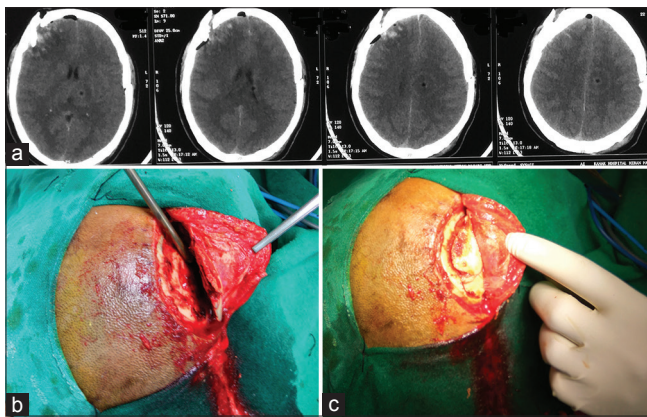


Figure 2: (a) Noncontrast Computed Tomography head showing elevated right frontal bone fracture, (b) intraoperative image showing elevated fracture, (c) intraoperative image after reduction of elevated fracture

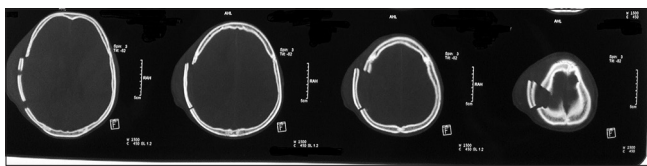


Figure 3: Noncontrast Computed Tomography brain bone window showing elevated right parietal bone fracture

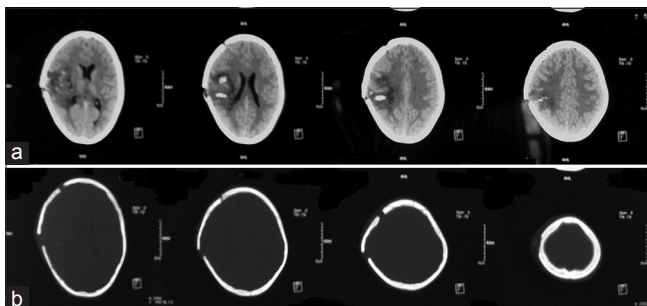


Figure 4: (a) Noncontrast Computed Tomography brain showing elevated fracture of the right parietal bone with intracranial hematoma, (b) Noncontrast Computed Tomography bone window showing right parietal bone elevated fracture

in performing the surgery, it may lead to intracranial infection, meningitis, brain abscess, bone flap osteomyelitis,

surgical site infection, wound gap, and poor outcome. Elevated fracture has more favorable outcome if it is not associated with underlying brain parenchymal injury. The outcome is also depends on GCS at time of admission and postoperative infection. The mechanisms behind such type of injuries are the lateral pull of the object or head rotation during the impact, as happens in head injuries sustained with long, sharp-edged objects such as propeller or machete.^[8,9] Another mechanism might be the elevation of the free fragment while attempts are made to remove the offending object or while the patient is transferred, described in few literature.^[8] There are very few references of elevated skull fracture in literature. We compared our patients with other published reports. Exclusive male gender involvement is related to their involvement in outdoor activities more than females. Modes of injury in Adeolu *et al.*, series were assault, domestic accident, and RTA.^[8] In patients with “CESF,” make it highly vulnerable to develop several complications (e.g., meningitis, brain abscess formation, or cerebrospinal fluid fistula [CSF]) and any delay in intervention can be catastrophic and can alter the prognosis.^[9-11] Dura may be intact in elevated skull fracture as mentioned by Borkar *et al.*^[9] In our series dural tear seen in two patients. It has been documented by some literature that elevated fractures are always compound in nature.^[12]

Noncontract CT Scan of the head with bone window is the investigation of choice in all age groups of elevated skull fracture patients because it reveals bony abnormality as well as any underlying hematoma and brain parenchymal lesions.^[1,13] Compound elevated fractures should be managed as compound depressed fracture with extensive debridement of wound, elevated bones fragment repositioned or remove after the evacuation of hematoma or contusion, with proper wash and closure of dura. Like for any other compound injury, early recognition, and adequate treatment of elevated skull fracture subgroup will prevent avoidable complications like intracranial sepsis or CSF fistula, and thus will reduce the morbidity and mortality.^[10] Pediatric patients are more susceptible

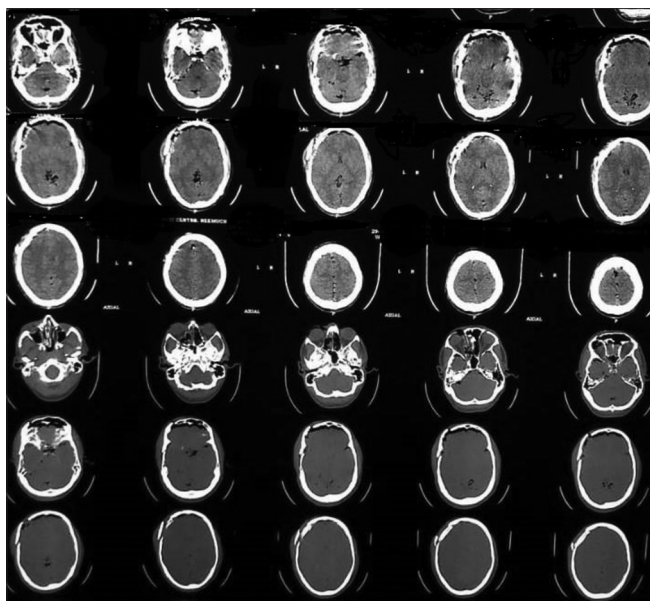


Figure 5: Noncontrast Computed Tomography brain showing elevated fracture of the right Frontal bone with bilateral pneumocephalus with underlying small extradural hematoma with contusion

for the secondary insult of the brain from low oxygen saturation, fluid imbalances, electrolyte disturbances, fever, and seizures requiring special care. Extensive medical literature search by our group shows that almost all reported cases of elevated skull fracture report adults.^[4,8-12] Chhiber *et al.* Reported two cases of elevated fractures in pediatric age group.^[11] Key elements of surgery are evacuation of hematomas, dural repair, further decompression (if brain is tense and bulging), thorough debridement and judicious replacement of elevated bone segment (depending on the degree of contamination, protrusion of brain, and adequacy of debridement), and a scalp repair over a subgaleal or extradural drain.^[9,13] Wound contamination may be relatively less in this group of fractures owing to tangential direction of impact which would introduce less amount of foreign material in the wound as compared to depressed skull fractures tangential force acting on the intact calvarium in association with rotation of the head.^[9,12] The amount of force transmitted to the brain and its overlying structures is more when applied force is perpendicular to the brain's surface in comparison to when the force is applied tangentially.^[8] Thus, injury to brain and associated structures may be less severe in elevated fracture having tangential impact compared to depressed fractures having a perpendicular impact.^[8] Depressed fracture of skull may be more contaminated than the elevated fracture of skull because the perpendicular direction of force drives more dirt in the wound than the tangential direction of the force. Hence, patients of depressed fractures are more prone for infectious complications than those with elevated fractures. Rarely, presentations are complicated with intraventricular hemorrhage and superior sagittal sinus

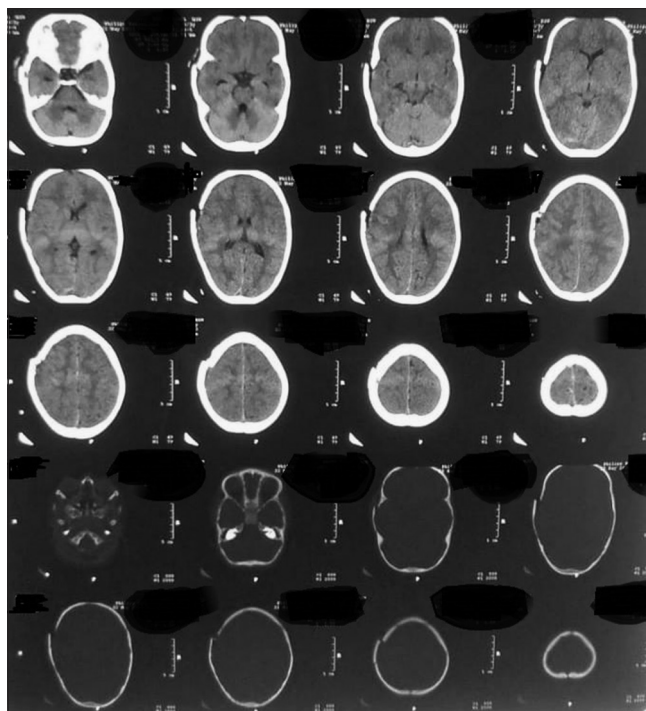


Figure 6: Noncontrast Computed Tomography brain showing elevated fracture of the right Frontal bone

occlusion.^[7,10] Although a few pediatric cases have been reported, none of them have quoted a long-term follow-up data.^[14]

Conclusion

Conventionally, directed mechanical force over calvarium is responsible for such type of injury. Early recognition and prompt surgical intervention in the form of wound debridement, thorough wound wash, fracture segment reduction, removal of foreign body, and loose bone segment with broad-spectrum antibiotic coverage is essential to prevent morbidity and mortality and leads to better outcome.

Financial support and sponsorship

Nil.

Conflicts of interest

There are no conflicts of interest.

References

1. Bhaskar S. Compound "elevated" fracture of the cranium. *Neurol India* 2010;58:149-51.
2. Breasted JH. Facsimile and hieroglyphic transliteration with translation and commentary, in two volumes. In: *The Edwin Smith Surgical Papyrus*. Chicago: University of Chicago Press; 1930.
3. Sanchez GM, Burrige AL. Decision making in head injury management in the Edwin smith papyrus. *Neurosurg Focus* 2007;23:E5.
4. Ralston BL. Compound elevated fractures of the skull. *J Neurosurg* 1976;44:77-9.

5. Garg N, Devi BI, Maste P. Elevated skull fracture. *Indian J Neurotrauma* 2007;4:133.
6. Balasubramaniam S, Tyagi DK, Savant HV. Everted skull fracture. *World Neurosurg* 2011;76:479.e1-3.
7. Sharma R, Kumar A, Bhat DI, Devi BI. Compound elevated fracture in adult: A series of five patients and review of literature. *Indian J Neurotrauma* 2012;9:112-6.
8. Adeolu AA, Shokunbi MT, Malomo AO, Komolafe EO, Olateju SO, Amusa YB, *et al.* Compound elevated skull fracture: A forgotten type of skull fracture. *Surg Neurol* 2006;65:503-5.
9. Borkar SA, Sinha S, Sharma BS. Post- traumatic compound elevated fracture of skull simulating a formal craniotomy. *Turk Neurosurg* 2009;19:103-5.
10. Abu Talha K, Selvapandian S, Asaduzzaman K, Selina F, Rahman M, Riad M, *et al.* Compound elevated skull fracture with occlusion of the superior sagittal sinus. A case report. *Kobe J Med Sci* 2009;54:E260-3.
11. Chhiber SS, Wani MA, Kirmani AR, Ramzan AU, Malik NK, Wani AA, *et al.* Elevated skull fractures in pediatric age group: Report of two cases. *Turk Neurosurg* 2011;21:418-20.
12. Verdura J, White RJ. Letter: Compound elevated skull fractures. *J Neurosurg* 1976;45:245.
13. Mohindra S, Singh H, Savardekar A. Importance of an intact Dura in management of compound elevated fractures; a short series and literature review. *Brain Inj* 2012;26:194-8.
14. Sharma R, Saligouda P, Bhat DI, Devi BI. Compound elevated skull fracture mimicking a frontotemporoorbitozygomatic craniotomy flap. *Neurol India* 2012;60:448-9.